EST. 1887
B. LOGIN & SON INC
CHEMICAL MEDICAL & SCIENTIFIC PERIODICALS AND BOOKS
B. L. S.
29 EAST 21 ST ST.
NEW YORK

TRANSACTIONS

of the

American Ophthalmological Society

Fifty-Ninth Annual Meeting

COLORADO SPRINGS, COL., 1923

VOLUME XXI

332545
27. 10. 36.

Philadelphia
American Ophthalmological Society
1923

RE
1
A55
V.21

PRESS OF WM. F. FELL COMPANY
PHILADELPHIA

TABLE OF CONTENTS

	PAGE
Officers and Council	5
List of Presidents	6
List of Members	7
Necrology	13
Minutes of the Proceedings	23
Hydrophthalmos (Buphthalmos or Infantile Glaucoma)—Report of a Case with Microscopic Findings: Dr. Samuel Theobald and Dr. C. A. Clapp	43
Report of Two Experiences with Acute Glaucoma: Dr. Hiram Woods	52
Iridectomy in Glaucoma: A New Technic: Dr. E. Török	62
An Operation for Blepharoptosis, with the Formation of a Fold in the Lid: Dr. Robert G. Reese	71
Duct Conservation in Lacrimal Abscess: Dr. A. E. Ewing	78
A Report of the Changes Found in the Eyes of Rabbits Following the Injection of Living Tubercle Bacilli into the Common Carotid Artery, Dr. William C. Finnoff	87
Melanotic Epibulbar Tumor Dispelled by the Use of Radium: Dr. William H. Wilder	100
Recurrent Pigmented Growth at Limbus: Dr. W. H. Luedde	107
A Case of Large Round-Cell Sarcoma of the Upper Eyelid: Dr. C. E. G. Shannon	119
Exhibition of Cases, New Instruments, and Apparatus:	
Thermophore: Dr. W. E. Shahan	124
Tuberculosis of the Eye: Dr. William C. Finnoff	124
Variations in the Primary Insertions of the Ocular Muscles: Dr. Lucien Howe	124
Glioma of Retina: Dr. Edward Jackson	124
Demonstration of Pathologic Slides:	
Siderosis Bulbi: Dr. Brown Pusey	125
A Case of Extensive Tuberculosis of the Eyeball: Dr. W. Gordon M. Byers	126
Persistent Hyaloid Artery: Dr. William C. Finnoff	134
Osteoma of the Orbit: Dr. Arthur J. Bedell	134
A Case of Adenocarcinoma Probably Arising From the Lacrimal Gland: Dr. Lee Masten Francis	140
A Case of Encapsulated Angioma of the Orbit: Dr. W. Gordon M. Byers	144
Posterior Transillumination of the Eyeball: Dr. George S. Derby	148
Selective Thermotherapy: Dr. W. E. Shahan	151
Malignant Disease of the Retina: Dr. Edward Jackson	159

PAGE

Autopsy Report of a Case of Bilateral Glioma Retinæ with Gliomatous Involvement of the Iris: Dr. Arnold Knapp 164

Siderosis Bulbi with Dilated Inactive Pupil. Recovery of Pupillary Activity After Removal of Foreign Body: Dr. Nelson M. Black... 171

Supplementary Notes on Lipæmia Renitalis: Effects of Insulin: Dr. William F. Hardy 183

The Significance of Deep Ocular Pain in Retinal Detachment: Dr. J. W. Charles 189

Bilateral Detachment of the Retina in two Successive Pregnancies: Dr. Emory Hill 194

Observations on Phacoanaphylactic Endophthalmitis: Dr. Albert N. Lemoine and Dr. Alexander E. MacDonald 202

Monocular Diplopia, with Especial Reference to that Associated with Cerebral Lesions: Dr. William Zentmayer 223

Metastatic Choroiditis from Focal Infection: Dr. Allen Greenwood 230

Optic Atrophy Manifested by Visual Disturbance Following Distant Hemorrhage: Dr. Delamere F. Harbridge 239

Traumatic Neurology of the Eye in Relation to Cerebral and Other Injuries: Dr. Hunter W. Scarlett 247

Examination of the Blind Spot of Mariotte: Dr. Conrad Berens, Jr.... 271

The Effect of General Tuberculosis on the Eye, with a Report of Frequently Overlooked Symptoms: Dr. H. H. Stark 290

Some of the Essentials in Legislation for the Relief of the Blind: Dr. F. E. Woodruff 301

Appendix: Report of Committee on Undergraduate Teaching of Ophthalmology 315

Report of Committee on Graduate Teaching of Ophthalmology 320

Index 327

OFFICERS AND COUNCIL

of the

American Ophthalmological Society

Elected at the Annual Meeting, June 19, 1923

President

DR. ALEXANDER DUANE, New York

Vice-President

DR. CASSIUS D. WESCOTT, Chicago

Secretary-Treasurer

DR. T. B. HOLLOWAY, Philadelphia

Council

DR. WALTER R. PARKER, Detroit, Mich.

DR. W. E. LAMBERT, New York

DR. HOWARD F. HANSELL, Philadelphia

DR. E. C. ELLETT, Memphis, Tenn.

DR. GEORGE S. DERBY, Boston, Mass.

PRESIDENTS OF THE SOCIETY

(Since its Foundation)

1864–1868 Dr. Edward Delafield, New York
1869–1873 Dr. Henry W. Williams, Boston, Mass.
1874–1878 Dr. C. R. Agnew, New York
1879–1884 Dr. Henry D. Noyes, New York
1885–1889 Dr. William F. Norris, Philadelphia
1890–1893 Dr. Hasket Derby, Boston, Mass.
1894–1898 Dr. George C. Harlan, Philadelphia
1899–1902 Dr. O. F. Wadsworth, Boston, Mass.
1903–1905 Dr. Charles S. Bull, New York
1906 Dr. Arthur Mathewson, Washington, D. C.
1907 Dr. Charles J. Kipp, Newark, N. J.
1908 Dr. Samuel D. Risley, Philadelphia
1909 Dr. S. B. St. John, Hartford, Conn.
1910 Dr. Samuel Theobald, Baltimore, Md.
1911 Dr. Emil Gruening, New York
1912 Dr. Edward Jackson, Denver, Col.
1913 Dr. Myles Standish, Boston, Mass.
1914 Dr. Robert Sattler, Cincinnati, O.
1915 Dr. M. H. Post, St. Louis, Mo.
1916 Dr. George E. de Schweinitz, Philadelphia
1917 Dr. Peter A. Callan, New York
1918 Dr. William H. Wilder, Chicago, Ill.
1919 Dr. Lucien Howe, Buffalo, N. Y.
1920 Dr. Hiram Woods, Baltimore, Md.
1921 Dr. John E. Weeks, New York
1922 Dr. Wm. M. Sweet, Philadelphia
1923 Dr. Wm. H. Wilmer, Washington, D. C.

American Ophthalmological Society

FOUNDED 1864

LIST OF MEMBERS

* Associate Members O. M. Original Members

Elected	Name	Residence	Place
1915	Dr. Ellice M. Alger,	40 East 41st Street,	New York, N. Y.
1899	Dr. A. N. Alling,	257 Church Street,	New Haven, Conn.
1883	Dr. J. A. Andrews,	1229 State Street,	Santa Barbara, Cal.
1913	Dr. Fred. D. Bailey,	260 Hancock Street,	Brooklyn, N. Y.
1923	*Dr. S. J. Beach,	704 Congress Street,	Portland, Me.
1911	Dr. Arthur J. Bedell,	344 State Street,	Albany, N. Y.
1908	Dr. Geo. H. Bell,	40 East 41st Street,	New York, N. Y.
1905	Dr. Jas. H. Bell,	5 E. Franklin St.,	Richmond, Va.
1921	*Dr. Wm. L. Benedict,	Mayo Clinic,	Rochester, Minn.
1923	*Dr. Conrad Berens,	9 East 46th Street,	New York, N. Y.
1921	*Dr. Nelson M. Black,	120 Wisconsin St.,	Milwaukee, Wis.
1916	Dr. Eugene M. Blake,	55 Trumbull Street,	New Haven, Conn.
1909	Dr. James Bordley, Jr.,	Professional Building,	Baltimore, Md.
1918	Dr. H. H. Briggs,	73 Haywood Street,	Asheville, N. C.
1908	Dr. E. V. L. Brown,	122 S. Michigan Blvd.,	Chicago, Ill.
1907	Dr. Wm. E. Bruner,	Guardian Bldg.,	Cleveland, Ohio
1901	Dr. H. D. Bruns,	211 Camp Street,	New Orleans, La.
1920	Dr. John W. Burke,	1740 M Street, N. W.,	Washington, D. C.
1906	Dr. W. K. Butler,	1207 M Street, N. W.,	Washington, D. C.
1906	Dr. W. Gordon M. Byers,	346 Mountain Street,	Montreal, Canada.
1918	Dr. F. Phinizy Calhoun,	The Doctors Building,	Atlanta, Ga.
1876	Dr. Peter A. Callan,	452 Fifth Avenue,	New York, N. Y.
1885	Dr. F. P. Capron,	118 Angell Street,	Providence, R. I.
O. M.	Dr. W. H. Carmalt,	261 St. Ronan Street,	New Haven, Conn.
1898	Dr. J. T. Carpenter,	2030 Chestnut Street,	Philadelphia, Pa.
1904	Dr. Burton Chance,	1305 Spruce Street,	Philadelphia, Pa.
1893	Dr. H. B. Chandler,	34½ Beacon Street,	Boston, Mass.
1904	Dr. J. W. Charles,	509 Humboldt Bldg.,	St. Louis, Mo.
1893	Dr. F. E. Cheney,	64 Commonw'th Ave.,	Boston, Mass.
1912	Dr. E. W. Clap,	390 Commonw'th Ave.,	Boston, Mass.
1922	*Dr. C. A. Clapp,	513 N. Charles Street,	Baltimore, Md.

Elected	Name	Residence	Place
1891	Dr. C. F. Clark,	188 East State Street,	Columbus, Ohio
1912	Dr. G. S. Crampton,	1819 Walnut Street,	Philadelphia, Pa.
1890	Dr. C. M. Culver,	36 Eagle Street,	Albany, N. Y.
1906	Dr. R. J. Curdy,	1134 Rialto Building,	Kansas City, Mo.
1902	Dr. Colman W. Cutler,	24 East 48th Street,	New York, N. Y.
1907	Dr. A. E. Davis,	47 East 57th Street,	New York, N. Y.
1878	Dr. W. S. Dennett,	36 Gramercy Park,	New York, N. Y.
1918	Dr. David N. Dennis,	221 West 9th Street,	Erie, Pa.
1909	Dr. George S. Derby,	23 Bay State Road,	Boston, Mass.
1912	Dr. Oscar Dodd,	1604 Chicago Avenue,	Evanston, Ill.
1902	Dr. Alexander Duane,	139 E. 37th Street,	New York, N. Y.
1912	Dr. E. C. Ellett,	Exchange Building,	Memphis, Tenn.
1887	Dr. J. B. Emerson,	40 East 41st Street,	New York, N. Y.
1890	Dr. Arthur E. Ewing,	Metropolitan Bldg.,	St. Louis, Mo.
1920	Dr. Marcus Feingold,	4206 St. Charles Ave.,	New Orleans, La.
1896	Dr. T. H. Fenton,	1319 Spruce Street,	Philadelphia, Pa.
1920	Dr. William C. Finnoff,	Imperial Bldg.,	Denver, Col.
1915	Dr. Carl Fisher,	1028 Pacific-Mutual Bldg.,	Los Angeles, Cal.
1893	Dr. George F. Fiske,	25 E. Washington Street,	Chicago, Ill.
1909	Dr. M. L. Foster,	106 Centre Avenue,	New Rochelle, N.Y.
1913	Dr. Lee M. Francis,	636 Delaware Avenue,	Buffalo, N. Y.
1902	Dr. Percy Fridenberg,	38 West 59th Street,	New York, N. Y.
1894	Dr. H. Friedenwald,	1029 Madison Ave.,	Baltimore, Md.
1913	Dr. H. G. Goldberg,	1925 Chestnut Street,	Philadelphia, Pa.
1923	*Dr. H. S. Gradle,	22 E. Washington Street,	Chicago, Ill.
1896	Dr. H. Y. Grant,	Falls View,	Ontario, Canada
1919	Dr. John Green, Jr.,	626 Metropolitan Bldg.,	St. Louis, Mo.
1908	Dr. L. S. Greene,	1624 I Street, N. W.,	Washington, D. C.
1905	Dr. Allen Greenwood,	82 Commonwealth Ave.,	Boston, Mass.
1914	Dr. J. Milton Griscom,	1925 Chestnut St.,	Philadelphia, Pa.
1892	Dr. G. W. Hale,	210 Hitchcock Building,	Nashville, Tenn.
1895	Dr. Wm. D. Hall,	416 Marlborough Street,	Boston, Mass.
1887	Dr. H. F. Hansell,	17th and Walnut Streets,	Philadelphia, Pa.
1918	*Dr. D. F. Harbridge,	Goodrich Building,	Phoenix, Ariz.
1918	Dr. Wm. F. Hardy,	Metropolitan Bldg.,	St. Louis, Mo.
1889	Dr. David Harrower,	13 Elm Street,	Worcester, Mass.
1896	Dr. N. D. Harvey,	114 Waterman Street,	Providence, R. I.
1904	Dr. H. H. Haskell,	5 Vista Avenue,	Auburndale, Mass.
1914	Dr. Edw. B. Heckel,	Jenkins Building,	Pittsburgh, Pa.
1913	Dr. Chas. R. Heed,	1205 Spruce Street,	Philadelphia, Pa.
1920	Dr. Emory Hill,	Professional Building,	Richmond, Va.
1896	Dr. Ward A. Holden,	8 East 54th Street,	New York, N. Y.
1909	Dr. T. B. Holloway,	1819 Chestnut Street,	Philadelphia, Pa.
1921	*Dr. E. E. Holt, Jr.	723 Congress Street,	Portland, Me.
1917	*Dr. Harvey J. Howard,	Union Medical College,	Peking, China

Elected	Name	Residence	Place
1878	Dr. Lucien Howe,	520 Delaware Avenue,	Buffalo, N. Y.
1891	Dr. D. W. Hunter,	71 Central Park, W.,	New York, N. Y.
1895	Dr. E. E. Jack,	215 Beacon Street,	Boston, Mass.
1885	Dr. Edward Jackson,	217 Imperial Bldg.,	Denver, Col.
1912	Dr. P. C. Jameson,	139 Montague Street,	Brooklyn, N. Y.
1918	Dr. J. Wilkinson Jervey,	Jervey-Jordan Bldg.,	Greenville, S. C.
1892	Dr. W. B. Johnson,	170 Broadway,	Paterson, N. J.
1908	Dr. B. R. Kennon,	Taylor Building,	Norfolk, Va.
1919	Dr. Ben Witt Key,	180 W. 59th Street,	New York, N. Y.
1903	Dr. Arnold Knapp,	10 East 54th Street,	New York, N. Y.
1889	Dr. Carl Koller,	30 East 58th Street,	New York, N. Y.
1888	Dr. Chas. W. Kollock,	86 Wentworth Street,	Charleston, S. C.
1913	Dr. Robert S. Lamb,	Stoneleigh Court,	Washington, D. C.
1891	Dr. W. E. Lambert,	112 East 35th Street,	New York, N. Y.
1902	Dr. W. B. Lancaster,	520 Commonw'lth Ave.,	Boston, Mass.
1919	*Dr. Francis Lane,	25 E. Washington Street,	Chicago, Ill.
1912	Dr. H. M. Langdon,	1530 Locust Street,	Philadelphia, Pa.
1903	Dr. J. C. Lester,	640 Madison Avenue,	New York, N. Y.
1907	Dr. George F. Libby,	Majestic Bldg.,	Denver, Col.
1883	Dr. J. A. Lippincott,	Park Palace,	Monte Carlo, Monaco
1909	Dr. R. G. Loring,	140 Beacon Street,	Boston, Mass.
1899	Dr. D. B. Lovell,	340 Main Street	Worcester, Mass.
1914	Dr. W. H. Lowell,	101 Newbury Street,	Boston, Mass.
1919	Dr. W. H. Luedde,	311 Metropolitan Bldg.,	St. Louis, Mo.
1918	Dr. Hunter H. McGuire,	105 N. Braddock Street,	Winchester, Va.
1923	*Dr. S. H. McKee,	158 Crescent Street,	Montreal, Can.
1913	Dr. A. L. Macleish,	1101 Brockman Bldg.,	Los Angeles, Cal.
1891	Dr. F. W. Marlow,	731 University Block,	Syracuse, N. Y.
1923	*Dr. G. H. Mathewson,	202 New Birks Bldg.,	Montreal, Can.
1907	Dr. C. H. May,	698 Madison Avenue,	New York, N. Y.
1874	Dr. C. S. Merrill,	27 S. Hawk Street,	Albany, N. Y.
1908	Dr. H. S. Miles,	1339 Main Street,	Bridgeport, Conn.
1883	Dr. J. Lancelot Minor,	Bank of Commerce Bldg.,	Memphis, Tenn.
1916	Dr. John H. Ohly,	22 Schermerhorn St.,	Brooklyn, N. Y.
1908	Dr. W. R. Parker,	David Whitney Bldg.,	Detroit, Mich.
1922	*Dr. Luther C. Peter,	1529 Spruce Street,	Philadelphia, Pa.
1920	*Dr. Adolph O. Pfingst,	Francis Building,	Louisville, Ky.
1895	Dr. R. J. Phillips,	123 So. 39th Street,	Philadelphia, Pa.
1898	Dr. W. Campbell Posey,	2049 Chestnut Street,	Philadelphia, Pa.
1895	Dr. H. R. Price,	146 Remsen Street,	Brooklyn, N. Y.
1906	Dr. Brown Pusey,	7 West Madison Street,	Chicago, Ill.
1901	Dr. Alex. Quackenboss,	143 Newbury Street,	Boston, Mass.
1906	Dr. McCluney Radcliffe,	1906 Chestnut Street,	Philadelphia, Pa.

Elected	Name	Residence	Place
1885	Dr. Alex'r Randall,	2009 Spruce Street,	Philadelphia, Pa.
1901	Dr. R. G. Reese,	50 West 52nd Street,	New York, N. Y.
1912	Dr. W. G. Reynolds,	1165 Dean Street,	Brooklyn, N. Y.
1901	Dr. G. O. Ring,	17th and Walnut Streets,	Philadelphia, Pa.
1908	Dr. J. Norman Risley,	238 Union Street,	New Bedford, Mass
1920	*Dr. William H. Roberts,	461 E. Colorado Street,	Pasadena, Cal.
1899	Dr. Dunbar Roy,	Gr. Opera House Blk.,	Atlanta, Ga.
1875	Dr. John D. Rushmore,	129 Montague Street,	Brooklyn, N. Y.
1880	Dr. Robert Sattler,	30, The Groton,	Cincinnati, Ohio
1912	Dr. A. C. Sautter,	1421 Locust Street,	Philadelphia, Pa.
1923	*Dr. Hunter W. Scarlett,	230 South 21st Street,	Philadelphia, Pa.
1898	Dr. T. B. Schneideman,	2045 Chestnut Street,	Philadelphia, Pa.
1919	*Dr. M. J. Schoenberg,	103 E. 81st Street,	New York, N. Y.
1889	Dr. G. E. de Schweinitz,	1705 Walnut Street,	Philadelphia, Pa.
1895	Dr. P. N. K. Schwenk,	1417 North Broad St.,	Philadelphia, Pa.
1918	Dr. Wm. E. Shahan,	Metropolitan Bldg.,	St. Louis, Mo.
1913	Dr. C. E. G. Shannon,	N. E. cor. 17th & Walnut,	Philadelphia, Pa.
1905	Dr. John R. Shannon,	17 East 38th Street,	New York, N. Y.
1916	*Dr. Francis W. Shine,	35 West 52d Street,	New York, N. Y.
1911	Dr. J. F. Shoemaker,	1006 Carleton Bldg.,	St. Louis, Mo.
1902	Dr. Wm. A. Shoemaker,	1006 Carleton Bldg.,	St. Louis, Mo.
1902	Dr. Wm. T. Shoemaker,	109 South 20th Street,	Philadelphia, Pa.
1905	Dr. E. A. Shumway,	2046 Chestnut Street,	Philadelphia, Pa.
1918	Dr. Dorland Smith,	834 Myrtle Avenue,	Bridgeport, Conn.
1912	Dr. E. T. Smith,	36 Pearl Street,	Hartford, Conn.
1910	Dr. Albert C. Snell,	53 S. Fitzhugh St.,	Rochester, N. Y.
1909	Dr. F. M. Spalding,	128 Newbury Street,	Boston, Mass.
1911	Dr. Chas. N. Spratt,	900 Nicollet Avenue,	Minneapolis, Minn.
1884	Dr. Myles Standish,	51 Hereford Street,	Boston, Mass.
1923	*Dr. H. H. Stark,	Roberts-Banner Bldg.,	El Paso, Tex.
1903	Dr. Edw. Stieren,	Union Trust Bldg.,	Pittsburgh, Pa.
1900	Dr. Wm. M. Sweet,	1205 Spruce Street,	Philadelphia, Pa.
1917	Dr. William Tarun,	605 Park Ave.,	Baltimore, Md.
1888	Dr. Lewis H. Taylor,	83 So. Franklin Street,	Wilkesbarre, Pa.
1903	Dr. Edgar S. Thomson,	39 East 61st Street,	New York, N. Y.
1898	Dr. Jas. Thorington,	2031 Chestnut Street,	Philadelphia, Pa.
1911	Dr. Fred. T. Tooke,	368 Mountain Street,	Montreal, Canada.
1912	Dr. E. Török,	8 East 54th Street,	New York, N. Y.
1906	Dr. H. H. Tyson,	11 East 48th Street,	New York, N. Y.
1916	Dr. Derrick T. Vail,	24 East 8th Street,	Cincinnati, Ohio
1898	Dr. C. A. Veasey,	Paulsen Building,	Spokane, Wash.
1905	Dr. F. H. Verhoeff,	101 Newbury Street,	Boston, Mass.
1903	Dr. F. L. Waite,	68 Pratt Street,	Hartford, Conn.
1916	*Dr. Clifford B. Walker,	317 Main Street,	Springfield, Mass.

Elected	Name	Residence	Place
1893	Dr. J. E. Weeks,	20 East 53d Street,	New York, N. Y.
1914	Dr. Walter B. Weidler,	137 East 60th Street,	New York, N. Y.
1900	Dr. C. D. Wescott,	22 E. Washington St.,	Chicago, Ill.
1916	Dr. John M. Wheeler,	30 West 59th Street,	New York, N. Y.
1892	Dr. J. A. White,	200 E. Franklin Street,	Richmond, Va.
1919	*Dr. Lloyd B. Whitham	514 Cathedral Street,	Baltimore, Md.
1895	Dr. W. H. Wilder,	122 S. Michigan Blvd.,	Chicago, Ill.
1910	Dr. Carl Williams,	School L. & Greene St.,	Philadelphia, Pa.
1912	Dr. Edw. R. Williams,	338 Commonwealth Ave.,	Boston, Mass.
1893	Dr. Wm. H. Wilmer,	1610 I Street, N. W.,	Washington, D. C.
1906	Dr. J. Scott Wood,	172 Sixth Avenue,	Brooklyn, N. Y.
1923	*Dr. F. E. Woodruff,	Metropolitan Bldg.,	St. Louis, Mo.
1900	Dr. Hiram Woods,	842 Park Avenue,	Baltimore, Md.
1915	*Dr. H. W. Wootton,	319 Lexington Avenue,	New York, N. Y.
1881	Dr. J. P. Worrell,	20 South 7th Street,	Terre Haute, Ind.
1905	Dr. Wm. Zentmayer,	1506 Spruce Street,	Philadelphia, Pa.
1903	Dr. S. Lewis Ziegler,	1625 Walnut Street,	Philadelphia, Pa.

Total 180

HONORARY MEMBERS

1868	Dr. J. S. Prout,	Fishkill,	Dutchess Co., N.Y.

EMERITUS MEMBERS

1896	Dr. A. E. Adams,	The Inn,	Newburgh, N. Y.
1881	Dr. H. W. Bradford,		Wolfboro, N. H.
1874	Dr. Lewis S. Dixon,	232 Clarendon Street,	Boston, Mass.
1883	Dr. E. E. Holt	723 Congress Street,	Portland, Me.
1905	Dr. S. C. Maxson,	235 Genesee Street,	Utica, N. Y.
1869	Dr. Thomas R. Pooley,	26 Trinity Street,	Newton, N. J.
1899	Dr. H. O. Reik,	300 E. 30th Street,	Baltimore, Md.
1895	Dr. H. W. Ring,	185 Church Street,	New Haven, Conn.
1878	Dr. J. A. Spalding,	627 Congress Street,	Portland, Me.
1880	Dr. Samuel Theobald,	Cathedral & How'd Sts.,	Baltimore, Md.
1891	Dr. Edward Wheelock,	Industry,	Monroe Co., N. Y.

Whole number 192

IN MEMORIAM

DR. FRANCIS B. LORING, elected 1878

DR. WILLIAM V. MARMION, elected 1878

DR. THERON Y. SUTPHEN, elected 1887

DR. GEORGE M. GOULD, elected 1895

DR. JOHN HERBERT CLAIBORNE, elected 1898

DR. JAMES W. INGALLS, elected 1898

DR. JOSEPH L. DUNCAN, elected 1908

NECROLOGY

WILLIAM VINCENT MARMION, A.M., M.D.

W. K. BUTLER, M.D.
Washington, D. C.

Dr. William Vincent Marmion was born May 27, 1840, in Harper's Ferry, West Virginia, his father being Dr. Nicholas Marmion, and his mother, before her marriage, Miss Lydia Ingraham Hall, of Maine.

He was of Revolutionary descent, being the grandson of John Hancock Hall, the inventor of the first breech-loading rifle used in America, and a great-grandson of Colonel Esaias Preble, Colonel of the Minute Men of Cambridge, Massachusetts, a member of the Convention which ratified the Constitution of the United States.

He received his early education under private tutors, taking his college course at Mount St. Mary's, Emmitsburg, Maryland. Leaving college he went to St. Joseph, Missouri, where he studied and later practised law with his uncle, Judge Willard Hall, who was afterward Governor of Missouri.

He later returned East and entered the University of Pennsylvania, from which he received his degree in medicine in March, 1866. In June of the same year President Andrew Johnson appointed him a surgeon in the Navy, after an examination with an average of 99. He served on the Flagship "Monongahela," under Commodore Bissell, both here and in foreign waters, performing heroic service during a yellow fever epidemic in Jamaica. During this period an eye trouble which he developed induced him to study ophthalmology, and

he resigned from the Navy and went to Vienna, where he studied at the University and later in Paris, where he practised until 1872, when he returned to this country and established himself professionally in Washington, and is said to have been the first specialist in eye, ear, and throat diseases in that city.

He became a member of the American Ophthalmological Society in 1878, and continued his membership until his death. Those members of the Society who knew him will remember him as a man of fine physique, strong personality, and eminently skilful in his profession, so that he soon became a leader in ophthalmology not only in his own city but in a large outside circle.

He was married in 1880 to Miss Caroline Walker McClellan, sister of General John McClellan, United States Army, now retired.

In 1883 he received the degree of Master of Arts from Georgetown University.

He died at his residence, 13th and Fairmont Streets, N. W., Washington, D. C., May 24, 1922, at the age of eighty-two, after a long and tedious illness which confined him to the house for more than eight years. He had been a resident of the District for fifty years, and until failing health necessitated his retirement had been a conspicuous figure among the leaders of the local medical profession. Interment was in Arlington National Cemetery. He is survived by a son, William V. Marmion, a lawyer; a daughter, Edythe Marmion Brosius; three sisters, Misses Mary, Isabelle, and Annie Marmion; and three grandchildren, Caroline, Edythe, and John Brosius, Jr.



George Milbry Gould, A.M., M.D.

GEORGE MILBRY GOULD, A.M., M.D.

HOWARD F. HANSELL, M.D.
Philadelphia

George Milbry Gould died at Atlantic City August 8, 1922, in his seventy-fifth year. In his death the public and the medical profession lost a useful man. The education, training, ability, energy, and enthusiasm that made him great would, had these qualities been directed into commercial lines, have made his activities in life and his death the subject of sorrowful comment, and finally of extended obituaries in the public press; they would have made him a wealthy and an envied man. But they were expended in relieving the sufferings of human beings and advancing the welfare of humanity as an individual. His reward was the consciousness of the soundness of his theories and the practical usefulness of their evolution, the esteem and respect of his patients and of the medical profession. Through his varied personal career he came into contact with many individuals of all classes of life, and through his writings with a much larger circle. The reading public knew him after the first half of his life had passed as a man devoted to his profession for the good of those whose lives had been, and were being, spoiled for them by their uncorrected optical defects, and not for his own advancement. Early in his professional days he called attention to the correction of errors of refraction that were considered insignificant; and by his six volumes of Biographic Clinics found, satisfactorily to himself at least, that happiness and success were jeopardized by neglect of the careful, painstaking, thorough correction of the smallest degree. His numerous papers on this subject, based upon his personal experiences, not in hospital but in his private practice, were of immediate and direct benefit to the general practitioner and

to the oculist—to the former, by enlightening him as to the possible cause of his patient's symptoms, and to the latter by demanding and exploiting the advantages of systematic and expert refraction work. He thus awakened the public to a sense of appreciation of their eyes as important factors in the creation and continuance of ill health, and of the profession to the necessity of eliminating such causes. His writings were criticized and sometimes were the subject of caustic comment. Every enthusiast in any walk of life must go through the same experiences, and although he cannot always reach his goal, his efforts do not go unrewarded, and the world is better for his having lived in it. Dr. Gould was sincere. He believed in the doctrines he advocated. He was no advertiser. He practised and wrote for the benefit of others. He was a kind and charitable man. He invited would-be patients to consult him without thought of monetary compensation. He gave freely of his time and ability to the poorest patient. His manner or his work was independent of the patient's ability to pay. His object was to do good—everything else was secondary. He was as courageous in his epigrammatic writings and utterances as he was honest and sincere in his convictions. In spite of, or perhaps stimulated by, the criticisms of his colleagues, he persisted in his own way of doing good. He has had some imitators and has influenced some general practitioners by his frequently and forcibly expressed claims of the value of the correction of small errors of refraction; and that, "the more common symptoms of migraine and other diseases, usually unrecognized as of ocular origin, were curable by scientific spectacles."

His practice was principally limited to the correction of refraction, for he believed that was the important branch of his specialty. As an operator he had no reputation whatever. He never sought opportunities for surgery. No doubt he could have become a surgeon had he turned his attention

to it, for his mind was great enough to achieve any object toward which he aimed, but he chose to devote himself to refraction, which he considered the subdivision of his specialty of greatest benefit to his patients. The surgery of the eye, in his opinion, was mechanical, and required manual dexterity, whereas the study and practice of the misshapen human eye demanded the highest form of mental dexterity. Moreover, he felt that his "single duty was to prevent the *need* of surgery, and the evils of ocular and systemic diseases caused by eye-strain." His efforts were directed to smoothing the paths and increasing the usefulness of those who depended on the close use of the eye for their happiness and livelihood.

My personal association with him was of the pleasantest and ever a stimulation. It was edifying and instructive to me to discuss and argue over our differences. In our talks I was invariably impressed by his honesty and sincerity, and in my memories of him those two qualities stand out most prominently. Dr. Gould had no political ambitions, either within or without the medical profession. His qualities of character especially unfitted him for the career of a successful politician or diplomat. Sincerity and frankness and plain emphatic language are outside the precincts of a man whose aim is to talk much and say little.

Dr. Gould's personal history I have abstracted from the biographic sketch by Dr. Thomas Hall Shastid, which was published in the American Journal of Ophthalmology, 1923. George Milbry Gould was born at Auburn, Maine, November 8, 1848, the son of George Thomas and Eliza A. Lapham Gould. A remote ancestor was Robert Goold, who in 1663 emigrated to Hull, Mass., from Somerset, England. In early childhood George removed with his father and step-mother to Salina, Ohio. There and at Athens, Ohio, he studied in public and private schools. At the age of twelve years he enlisted in the Northern Army of the Civil War as a drummer

boy, serving from 1861 to 1862. Later he reënlisted and served the final year of the war. He received the degree A.B. in 1873 from Ohio Wesleyan University, and A.M. in 1892; also the Phi Beta Kappa Key.

Dr. Gould was twice married. His first wife was Harriet Fletcher Cartwright, of Pomeroy, Ohio, to whom he was married October 15, 1876; and the second wife, to whom he was married October 3, 1917, was Laura Stedman, of New York City, who survives him. No children were born of either marriage.

In 1874 he was graduated from the Harvard Divinity School, but chiefly because of ill health, which he later found to be caused by eye-strain, he did not become a minister, but went into business, and had the finest book and art store in the state of Ohio. Later, in 1885, in his search for a satisfying vocation, and also to discover the baffling cause of his own ill health, he entered Jefferson Medical College and was graduated in 1888, president of his class (quotation from a personal letter to the writer from the widow of Dr. Gould). He never practised general medicine, and immediately after graduating opened an office in Philadelphia as an ophthalmologist. Within the year he invented his cemented bifocal lenses, which have been used all over the world since. After twenty years of successful practice and an enormous amount of other medical work as editor and writer, he moved to Ithaca, N. Y., and three years later to Atlantic City, N. J., where he practised until his death.

Dr. Gould was ophthalmologist to the Philadelphia General Hospital, 1892–94; Editor, Medical News, 1891–95; Philadelphia Medical Journal, 1898–1900; American Medicine, which he founded, 1901–1906; Fellow of the College of Physicians of Philadelphia. Member, of the American Ophthalmological Society; of the American Academy of Medicine, of which he was president in 1895. He was Speaker, Ophthalmology, Congress Arts and Science, St. Louis Ex-

position. In 1917 he received the first Doyne Medal at the Ophthalmological Congress, Oxford, England. He was proffered the Editorship of the Journal of the American Medical Association, and also that of the British Medical Journal; but these appointments he declined. In 1909 Dr. Gould published a Bibliography, including his writings in ophthalmology, general medicine, and literature. The briefest outline of his work is incompatible with due regard for the length of this paper. The pamphlet is printed by Andrus and Church, Ithaca, and no doubt a copy of his medical publications may be secured from them. I will mention only one as an example of the popularity and success of nearly all others, namely, the Medical Dictionary, of which Dr. Shastid says one-half a million copies were sold.

Dr. Gould was over six feet in height, erect in carriage, springy and elastic in his gait. His conversational manner was brisk, decisive, and impressive. His recreations were scholarly: science, poetry, philosophy, music, and art. Practically he took no exercise, except, when possible, a daily walk. How he kept up his arduous, constant duties of practitioner, with an office full of patients all day long, of editor of a weekly journal, and of a prolific writer of essays and books, remained a puzzle to his friends. In concluding this imperfect biography, for I have omitted many interesting facts in the history of Dr. Gould because of the lack of space, I take the liberty of presenting verbatim the last page of a letter written to me by his widow, whose devotion to him and to his memory is sacred:

"You spoke of my estimate of my husband: How can I give that, except as it is reflected from the Biography I hope adequately to write? For to me, my husband was the most remarkable man I ever met; one who combined the humanity of a Lincoln with the resolute vigor and courage of a Roosevelt. Although I would not compare him to any one, because he was supremely himself. . . . these qualities

I hope to portray, for many wonderful anecdotes, etc., are being sent to me by friends and patients.

"Perhaps you would care to say that Dr. Gould never wished a formal office, for that was always a living part of his home, where patients were welcomed more as friends; and such was the atmosphere that on entering a confidence and a hope were inspired, even before the patient met my husband. Then his greeting was invariably so genuinely hearty and sympathetic that the patient was comforted before any examination had begun. Of course, you know his zeal: it mattered not whether there was to be any remuneration at all; the one thing that mattered was, he had to save *that* pair of eyes, and the health of *that* patient. Refraction was to him also a creative art; and he brought to it the genius of the artist with the spirit of a missionary."

JOHN HERBERT CLAIBORNE, M.D.

W. E. LAMBERT, M.D.
New York City

John Herbert Claiborne was born in Louisburg, North Carolina, on June 29, 1861, the son of John Herbert Claiborne, an eminent physician of Petersburg, Virginia, and Sara Alston Claiborne. He attended preparatory school at Petersburg, Va., and was a graduate in arts from the University of Virginia, subsequently taking the degree of Doctor of Medicine in the Medical Department of the same University.

After graduating in medicine, he came to New York, where he entered the New York Polyclinic and Bellevue Medical School, at the completion of which course he became the private assistant of Dr. Gruening, remaining with him in this capacity for two years.

From the fall of 1885 to the summer of 1886 Dr. Claiborne traveled extensively in Europe, devoting himself to the further study of the eye and ear. In 1886 he returned to the United States and engaged in practice in New York City.

John Herbert Claiborne, M.D.

He was Instructor in Clinical Ophthalmology at Cornell University Medical School; Surgeon to the New Amsterdam Eye and Ear Hospital; Professor of Ophthalmology at New York Polyclinic; and Instructor in Ophthalmology at Columbia University.

Dr. Claiborne was a member of the American Medical Association, New York State Medical Society, New York County Medical Society, New York Academy of Medicine, American Ophthalmological Society, Academy of Ophthalmology and Oto-Laryngology, New York Ophthalmological Society, Medical Society of Virginia, and the Harveian Society. He was ex-President of the Section on Ophthalmology of the Academy of Medicine.

Dr. Claiborne made some very important contributions to medical literature, among them being: "Cataract Extraction," 1909; "Some Experiments on Rabbits made with a View to Obtaining a Stump for the Accurate Fitting of Glass Eyes," 1896; "The Effect of the Extrinsic Poisons on the Eye," 1897; "Treatment of Trachoma with a Modification of Knapp's Roller Forceps," 1903; "Causes, Prevention and Management of Myopia," 1903; "Experiments to Determine the Value of Collargolum and Antistreptococcic Serum in Infected Wounds of the Eye," 1904; "Infantile Amaurotic Family Idiocy: a Report of a Case and its Autopsy," 1899; "The Axis of Astigmatism," 1904; "A Chart for the Axis of Astigmatism," 1909; "Experiments to Determine the Value of Formalin in Infected Wounds of the Eye," 1903.

Before the Spanish-American War Dr. Claiborne served five years as trooper and line sergeant in Squadron A, National Guard, State of New York, and in 1898 volunteered and went as second lieutenant, New York Volunteers. He successively went through the grades of second lieutenant, first lieutenant, and regimental adjutant, receiving on October 15, 1898, his honorable discharge as line captain. Dr. Claiborne was a member of the Naval and Military Order of the Span-

ish-American War; Military Order of Foreign Wars of the United States of America; also of the University, Union, and Fencers Clubs. He wrote a brochure on his experience during the war. He was the author of "Three Months' Experience in Camp Thomas, Spanish-American War, 1899," and "On a System of Lighting Ships and Light-Houses in Substitution for the Ones at Present in Use," in the United States Naval Institute Proceedings, 1908.

Dr. Claiborne was a man of unusual energy, of charming personality, and he had a host of friends both in and out of his chosen profession. For two terms he was the popular President of the Virginians, during which time he most successfully conducted the affairs of that well-known Society. He leaves a widow and one son.

MINUTES OF THE PROCEEDINGS

FIFTY-NINTH ANNUAL MEETING

Colorado Springs, Col., June 19, 1923.

The Fifty-ninth Annual Meeting of the Society was held at the Broadmoor, Colorado Springs, Colorado, June 19, 20, and 21, 1923.

The opening session was called to order at 9.20 a. m. by the President, Dr. W. H. Wilmer, Washington, D. C., who made the following address:

This Society at its last meeting conferred a great honor upon me. It is vain to attempt to "gild with words" my deep appreciation of the action of this "ancient and honorable" body. That it is honorable, is shown by its splendid record, beginning with the early Fathers of American ophthalmology, whose names are on the membership list, and continuing through the intervening years. It is more ancient than many of its members realize, being the oldest national ophthalmological society in the world. Only one other special society, the Ophthalmologische Gesellschaft of Heidelberg, is its senior, and that by only a few months. In England the Ophthalmological Society of the United Kingdom was founded in 1880, and the Section of Ophthalmology of the Royal Society of Medicine in 1912. The first Transactions of the French Society of Ophthalmology (Société Française d'Ophtalmologie) were published in 1883, and of the Belgian Society of Ophthalmology (Société Belge d'Ophtalmologie) in 1895.

But the American Ophthalmological Society came into being during the latter part of the unhappy struggle of the Civil War. On January 9, 1864, eight men met in New York to effect the organization, and on June 7 of the same year the first scientific meeting of the Society was held.

At the second meeting of the Society in 1865 a report on the Progress of Ophthalmology was read by Dr. Jeffries, of Boston. He closed his address with the following words: "We have, at least, by the very formation of this Association, shown that we are anxious to learn, by mutual intercourse and interchange of thought and criticism, and that we have in view the one great object of our specialty, the restoration of sight."

It is our duty to do our part in perpetuating this spirit. Many members of the Society feel this can best be accomplished, at least in part, by the creation of an endowment fund to be used for the advancement of the science and art of ophthalmology. The value of such a fund is obvious. The Ophthalmological Society of the United Kingdom recognized the value of having one to be used for illustrating its Transactions; the Section of Ophthalmology of the American Medical Association has the Knapp Fund; and the Academy of Ophthalmology and Oto-Laryngology a sum of about $40,000. Realizing the need in this Society for something of this kind, one of the envisioned and honored members presented in 1919 a fund to pay for the Medal for Research for the American Ophthalmological Society.

An endowment fund could be raised if each member pledged himself to give one hundred dollars outright or in yearly installments of ten dollars or more. This fund could be further increased by bequests, by special gifts, or by the assistance of some of the great foundations of this country. The income from this fund could be applied to a fellowship for special ophthalmic research. It is earnestly hoped that the Society will look favorably upon this constructive policy. There is an ancient proverb which is as applicable to science as it is to the body politic, "Where there is no vision, the people perish."

This Society is as national in its scope as it is in its name. It is now in the noontide of its strength, where it may look back with justifiable pride upon its achievements in the past, and forward to the future in the certain hope of greater usefulness and wider activity. As an earnest proof of this, it has crossed the Mississippi and the plains, for the first time in the fifty-nine years of its existence, to enjoy the hospitality and the friendships, the beauty and the inspiration of this great western country, where the gardens are those of the Gods, a cañon is the "Divine Abyss," while the trees and the peaks "rest their heads among the stars."

The Chair appointed Dr. George F. Libby, Denver, to act as Auditing Committee.

The following papers were read and discussed:

1. "Hydrophthalmos (Buphthalmos or Infantile Glaucoma): Report of a Case with Microscopic Findings." Drs. Samuel Theobald and C. A. Clapp, Baltimore.

Discussed by Drs. George F. Libby, Denver; F. Phinizy Calhoun, Atlanta; William Zentmayer, Philadelphia; E. C. Ellett, Memphis; T. B. Holloway, Philadelphia; Marcus Feingold, New Orleans; John Green, Jr., St. Louis; L. V. Stegman, Battle Creek, Mich.; and C. A. Clapp.

2. "Report of Two Experiences with Acute Glaucoma." Dr. Hiram Woods, Baltimore.

Discussed by Drs. Edward Jackson, Denver; C. A. Veasey, Spokane, Wash.; Allen Greenwood, Boston; Arnold Knapp, New York City; and Hiram Woods.

3. "Iridectomy in Glaucoma: A New Technic." Dr. Ervin Török, New York City.

Discussed by Drs. W. H. Wilder, Chicago; George S. Derby, Boston; and Ervin Török.

4. "An Operation for Blepharoptosis with the Formation of a Fold in the Lid." Dr. Robert G. Reese, New York City.

Discussed by Drs. Carl Fisher, Los Angeles, Cal.; W. B. Lancaster, Boston; Ben Witt Key, New York City; George S. Derby, Boston; and William Zentmayer, Philadelphia.

5. "Duct Conservation in Lacrimal Abscess." Dr. A. E. Ewing, St. Louis.

Discussed by Drs. Hiram Woods, Baltimore; Allen Greenwood, Boston; Arthur J. Bedell, Albany, N. Y.; J. W. Charles, St. Louis; and A. E. Ewing.

6. "A Report of the Changes Found in the Eyes of Rabbits Following the Injection of Living Tubercle Bacilli into the Common Carotid Artery." Dr. William C. Finnoff, Denver.

Discussed by Drs. Eugene M. Blake, New Haven, Conn.; Lucien Howe, Buffalo; James A. Patterson, Colorado Springs; Hiram Woods, Baltimore; Marcus Feingold, New Orleans; Allen Greenwood, Boston; T. B. Holloway, Philadelphia; Edward Jackson, Denver; W. H. Wilder, Chicago; E. V. L. Brown, Chicago; and William C. Finnoff.

7. "Melanotic Epibulbar Tumor Dispelled by the Use of Radium." Dr. William H. Wilder, Chicago.

8. "Recurrent Pigmented Growth at Limbus." Dr. W. H. Luedde, St. Louis.

The papers of Drs. Wilder and Luedde were discussed by Drs. Arnold Knapp, New York City; T. B. Holloway, Philadelphia; William Zentmayer, Philadelphia; Allen Greenwood, Boston; and W. H. Wilder.

9. "A Case of Large Round-Cell Sarcoma of the Upper Eyelid." Dr. Charles E. G. Shannon, Philadelphia.

The following, who were present at the meeting, were invited to be guests of the Society and take part in the discussions:

Drs. Hans Barkan, San Francisco; Conrad Berens, New York City; Melville Black, Denver; W. T. Brinton, Denver; Edward H. Cary, Dallas, Texas; E. F. Conant, Denver; John M. Foster, Denver; F. S. Halsted, Denver; J. C. Heinrichs, St. Louis; L. L. Herriman, Alamosa, Col.; Guy H. Hopkins, Pueblo, Col.; George W. Jean, Santa Barbara, Cal.; J. W. Kimberlin, Kansas City, Mo.; C. L. LaRue, Boulder, Col.; Albert N. Lemoine, Kansas City, Mo.; Joseph S. Lichtenberg, Kansas City, Mo.; T. C. Lyster, Los Angeles, Cal.; John S. McCaw, Denver; E. E. McKeown, Denver; John O. McReynolds, Dallas, Texas; H. Moulton, Fort Smith, Ark.; E. R. Neeper, Colorado Springs; D. H. O'Rourke, Lt., M.C.U.S.N., Denver; Jas. A. Patterson, Colorado Springs; R. E. Robinson, Waverly, Iowa; H. H. Stark, El Paso, Texas; Louie V. Stegman, Battle Creek, Mich.

Executive Session, June 19th

The executive session was called to order at 8.30 p. m. by the President, Dr. W. H. Wilmer.

In presenting his report the Secretary-Treasurer suggested that the Minutes of the last meeting, as published in the Transactions, be accepted as the records of the meeting, and their reading be dispensed with, which was agreed to. In his report the Secretary-Treasurer said:

I think it is interesting to note that we have few members now who joined the Society prior to 1880; in fact, only seven are on the active list. One is an original member, Dr. W. H. Carmalt, of New Haven; two were elected in 1874; one in 1875; one in 1876; and two in 1878, one of whom remains the youngest of all and never misses a meeting—Dr. Lucien Howe.

It was a source of pleasure this year not to be compelled to resort to a note to meet our printing obligations. The Society is clear of debt and has a balance in the treasury of $397.13.

The report of the Secretary-Treasurer was accepted and filed, after the Auditing Committee had certified to its correctness.

Dr. W. Gordon M. Byers, chairman of the Committee on Prize Essays for Medical Research, made the following report:

The Committee on Prize Essays recommends that the Society's medal be given this year to Dr. Alexander Duane, of New York City, in recognition of his high professional attainments, his numerous and uniformly sound contributions to medical education and ophthalmic practice, and his valuable investigations in the domain of ophthalmology.

The Committee recommends further:

That the awards be of an international character.

That the principles governing in this award, namely, character and professional attainments, work in the domain of medical education and of ophthalmic practice, and original investigation in the field of ophthalmology, shall govern in future awards.

That, if the foregoing recommendations meet with the approval of the Society as shown by their adoption of this report, the committee for the ensuing year be hereby instructed to elaborate and present at the next meeting of the Society a scale of values for the principles enumerated that shall govern future awards.

On motion, duly seconded, the report was adopted.

Dr. W. H. Wilder made the following report of the American Board for Ophthalmic Examinations:

In regard to the work of the Board for the past year I will say that since the last meeting of this Society we have held two examinations, one in St. Louis at the time of the meeting of the Ameri-

can Medical Association, and another in Minneapolis at the time of the session of the American Academy of Ophthalmology and Oto-Laryngology. Then we examined candidates personally and gave them written examinations in the eight departments of ophthalmology. Also, as is customary, we certificated at the Board meeting certain individuals whose applications had been up for consideration, and at the end of last year the total number of persons in this country who has been certificated by the Board was 359.

The Board contemplates in the future holding additional examinations at certain times and places that may be convenient for groups of applicants who possibly find it inconvenient to attend the examinations which heretofore we have conducted at the time of these national meetings. We have held these examinations at these times largely as a measure of convenience for candidates, who could combine the examination with attendance at these meetings, and also because the examiners found it a greater convenience and it did not involve so much expense for additional travel. But I think in the future we shall have to provide for these special examinations by examiners who will be delegated by the Board, because there is naturally an increasing number of persons in this country becoming aware of the fact that they must have these qualifications and the certificate of the American Board for Ophthalmic Examination before they are eligible either to this Society or to the Academy, and as this number increases the duties of the Board will become more and more onerous.

I think the members of this Society should be cognizant of the fact that the members of this Board have done wonderful service in their loyalty to the cause by the faithfulness with which they have attended examinations. We have never had a meeting at which we did not have a quorum, and the examination conducted this year at San Francisco will be our thirteenth. A number of these examinations, even during the war, were attended by every single member of the Board.

In the absence of other members of the Committee on An International Congress of Ophthalmology, Dr. W. H. Wilmer briefly reported the successful termination of the Congress and the satisfaction of the participants, both foreign and American.

The report of the Committee on Undergraduate Teaching of Ophthalmology was presented by the chairman, Dr. W. Gordon M. Byers. The full report of the Committee, with supplementary reports of individual members of the Committee, will be found on page 315. The Committee indicated that its report was preliminary, and asked to be continued for another year.

It was moved by Dr. W. B. Lancaster that the report be accepted, and the Committee continued. Motion carried.

The report of the Committee on Graduate Teaching of Ophthalmology was presented by Dr. Edward Jackson. The full text of the report is printed on page 320.

It was moved by Dr. W. H. Wilder that the report be accepted and the Committee continued. Motion carried.

Dr. W. B. Lancaster, Chairman of Council, made the following report:

The Council recommends the following named candidates be elected as Associate Members:

Dr. Hunter W. Scarlett, Philadelphia.
Dr. Conrad Berens, New York City.
Dr. Frederick E. Woodruff, St. Louis.
Dr. Harry S. Gradle, Chicago.
Dr. Sylvester Judd Beach, Portland, Maine.
Dr. S. H. McKee, Montreal, Canada.
Dr. Geo. H. Mathewson, Montreal, Canada.
Dr. H. H. Stark, El Paso, Texas.

A number of other candidates were referred to the Council for 1924.

The Council recommends for emeritus membership:

Dr. Samuel Theobald, Baltimore, Md.
Dr. A. E. Adams, Newburgh, N. Y.
Dr. H. W. Bradford, Wolfboro, N. H.
Dr. E. E. Holt, Portland, Maine.

The American Academy of Ophthalmology and Oto-Laryngology invited this Society to take part in the formation of a National

Council. The following is the resolution introduced at the American Academy:

> "Believing that the general welfare of the public and that of ophthalmology, otology and oto-laryngology can best be served by the creation of some central representative committee chosen by the various existing accredited special societies;
>
> "*Be it resolved*, That the Council of the American Academy of Ophthalmology and Oto-Laryngology appoint such delegates who shall join with members appointed from the various other societies for the purpose of forming such a National Council.
>
> "This National Council shall concern itself with all matters concerning the welfare of the special branches and that of the public in relation to the practice of such specialties. Among its various functions it shall take measures necessary to:
>
> "a. The establishment and maintenance of higher medical standards for the practice of the special branches.
>
> "b. For the proper influencing of legislation.
>
> "c. For the education and enlightenment of the general public through whatever channels it may find proper."

The Council reports favorably upon this request of the American Academy of Ophthalmology and Oto-Laryngology that this Society appoint a member to act upon this National Council.

The Council entirely approves and endorses the ideas of the President concerning the establishment of an Endowment Fund.

The Council recommends, in addition to the usual assessment of $10.00, that an extra assessment of $5.00 be made on each member of the Society for the ensuing year.

The following nominations were made:

President, Dr. Alexander Duane, New York City.

Vice-President, Dr. Cassius D. Wescott, Chicago.

Secretary-Treasurer, Dr. T. B. Holloway, Philadelphia.

For the American Board for Ophthalmic Examinations: Dr. Fred. T. Tooke, Montreal, Canada, to serve for three years.

As nominees for the Board of Governors of the American College of Surgeons: Drs. Alexander Quackenboss, C. A. Veasey, and F. Phinizy Calhoun.

The Council names Hot Springs, Virginia, as the place of meeting in 1924, the time to be announced at a later date.*

* The next annual meeting will be held May 26, 27, and 28, 1924.

Upon motion, duly seconded, the report of Council was accepted.

It was moved that the names recommended for emeritus membership be concurred in, and that these names be added to the present list. Motion carried.

The nominations of the Council for the American Board for Ophthalmic Examinations and as nominees for the Board of Governors of the American College of Surgeons were adopted.

The Chair announced, in the absence of any objections, the election of Drs. Hunter W. Scarlett, Conrad Berens, Frederick E. Woodruff, Harry S. Gradle, Sylvester Judd Beach, S. H. McKee, Geo. H. Mathewson, and H. H. Stark as Associate Members.

The recommendation of an assessment of $15 for the current year was adopted.

The Society also adopted the recommendation of Council that the next annual meeting be held at Hot Springs, Virginia.

It was moved that it is the sense of this Society that an Endowment Fund should be started. Motion carried. A total of $710 was subscribed at the meeting, of which $410 was announced by the President as including his subscription and the contributions of persons to whom he had mentioned the subject of the proposed Endowment Fund.

It was moved that the President appoint a member to serve on the National Council. Carried. The Chair appointed Dr. E. C. Ellett, Memphis, Tenn.

The President was also directed to appoint a member of the Committee on Pathology. The Chair appointed Dr. F. H. Verhoeff, of Boston.

The Secretary announced the following deaths during the year:

Dr. Francis B. Loring, Washington, D. C., elected 1878.
Dr. William V. Marmion, Washington, D. C., elected 1878.

Dr. Theron Y. Sutphen, Newark, N. J., elected 1887.
Dr. George M. Gould, Atlantic City, N. J., elected 1895.
Dr. John Herbert Claiborne, New York City, elected 1898.
Dr. James W. Ingalls, Brooklyn, N. Y., elected 1898.
Dr. Joseph L. Duncan, Pittsburgh, Pa., elected 1908.

The Chair appointed Drs. W. K. Butler, Howard F. Hansell, and W. E. Lambert as a Committee to prepare Memoirs for publication in the Transactions.

The Chair announced the following Committees:

Council: Drs. Walter R. Parker, Walter E. Lambert, Howard F. Hansell, E. C. Ellett, and George S. Derby.

Committee on Theses: Dr. Marcus Feingold, to serve for three years; Dr. Arnold Knapp, to serve for two years; and Dr. E. V. L. Brown, to serve for one year.

Committee on Program: Drs. Wm. T. Shoemaker, W. B. Lancaster, and the Secretary.

Committee on Publication: Drs. H. Friedenwald, John Green, Jr., and the Secretary.

Committee on Prize Essays for the Medal for Research of the American Ophthalmological Society: Dr. Allen Greenwood, to serve for three years; Dr. John E. Weeks, to serve for two years; and Dr. Lucien Howe, to serve for one year.

Representatives on the American Board for Ophthalmic Examinations: Dr. Fred. T. Tooke, to serve for three years; Dr. Hiram Woods, to serve for two years; and Dr. William Zentmayer, to serve for one year.

Committee on Undergraduate Teaching of Ophthalmology: Drs. W. Gordon M. Byers, E. V. L. Brown, Arnold Knapp, George S. Derby, and W. C. Finnoff.

Committee on Graduate Teaching of Ophthalmology: Drs. Edward Jackson, F. H. Verhoeff, and T. B. Holloway.

Committee on Pathology: Dr. F. H. Verhoeff, as a representative of this Society.

Committee to Investigate and Revise the Classification of Certain Retinal Conditions: Drs. Edward Jackson, F. H. Verhoeff, Marcus Feingold, and W. Gordon M. Byers.

Committee to Investigate the National Safety Code for the Protection of the Head and Eyes of Industrial Employees: Drs. Nelson M. Black, W. B. Lancaster, and Walter R. Parker.

National Council: Dr. E. C. Ellett, as a representative of this Society.

The next order of business was the consideration of amendments to the Constitution and By-Laws, offered at the last meeting, and printed in the Transactions:

CONSTITUTION

Upon motion of Dr. Lancaster Article III, Section 3, as amended, was adopted. The amended Section reads as follows:

ARTICLE III, SECTION 3: When all other credentials and qualifications of a candidate for membership have been favorably passed upon by the Council he shall be notified by the Secretary to prepare a thesis on some subject chosen by himself, or submit in lieu thereof original papers previously published, at the discretion of Council. The thesis must be presented within two years. If the name of any candidate is not favorably reported to the Council by the Thesis Committee before the second annual meeting after he was notified to present a thesis, the name of such candidate shall be dropped from the list of candidates, but he may again be proposed for membership at the same or a subsequent meeting of the Society.

BY-LAWS

Dr. Wilder moved that Article II, Section 1, as amended, be adopted. Carried. The amended section is as follows:

ARTICLE II, SECTION 1: All nominations of candidates for membership shall be presented in writing to the Secretary-Treasurer, signed by two members of the Society, before or at the annual meeting, and the names so presented shall be read by the Secretary-Treasurer at an Executive Session, with the names of the proposer and seconder. It is desirable that at least one of the sponsors should be from the same locality as the candidate.

The amendments to Article III, Section 5, were adopted, so that the section reads as follows:

ARTICLE III, SECTION 5: The Council shall be the Nominating Committee for officers. It shall consider the qualifications of all

candidates proposed for membership in the Society, their scientific attainments, and also the report of the Committee on Theses. It shall investigate all charges against members and take suitable action thereon, except as this may conflict with Art. VI, Sections 1 and 2. It shall have the power to fill any vacancy that may occur in any office of the Society between one annual meeting and the next. It shall act on all matters pertaining to the welfare of the Society not otherwise provided for by the Constitution and By-Laws. It shall nominate a member each year to serve for three years on the American Board for Ophthalmic Examinations. It shall meet the day before the annual meeting to act upon nominations for membership and to transact other business that may come before it. It may hold other meetings before or during the annual meeting, at the call of the Chairman. In the absence or incapacity of the Chairman the next member of the Council in term of service shall automatically succeed to the temporary Chairmanship. A majority of the members of the Council shall constitute a quorum.

The amendments to Section 6, and the change in the numbering of the Section, so that it shall be Section 7, were adopted. The new section is as follows:

Article III, Section 7: The Publication Committee shall consist of three members, one of whom shall be the Secretary-Treasurer. It shall decide which papers read before the Society shall appear in the Transactions. It shall have power to require any author of a paper read before the Society so to edit or abbreviate his article as to bring it within proportions suitable for publication in the printed Transactions. Any member has the right of appeal to the Council.

The proposed amendments to Article III, Section 7, referring to the Program Committee, were lost. It was agreed that the numbering of this Section should be changed from Section 7 to Section 6.

Upon motion of Dr. Lancaster Article III, Section 8, was amended to read as follows:

Article III, Section 8: The Committee on Theses shall consist of three members, one appointed each year to serve for a term of three years. It shall receive information regarding the scientific

qualifications of all candidates for membership referred to it by the Council; it shall consider all their publications as well as the theses submitted and shall report its opinion to the Council.

Dr. Lancaster moved that the amendments as a whole, apart from Article III of the By-Laws, referring to the Program Committee, be adopted. Carried.

The Secretary was directed by vote to cast the ballot of the Society for the various officers and members of committees nominated by Council, and the President announced their election.

The Secretary read the following communication from Dr. Luther C. Peter, Secretary of the American Academy of Ophthalmology and Oto-Laryngology:

A year and a half ago a department on pathology was organized by the American Academy of Ophthalmology and Oto-Laryngology as a phase of the Academy's activities in affiliation with the Army Medical Museum. It was designated the Section on Pathology. This department has been in active operation for over a year and during this time over one hundred ophthalmic specimens were received and examined. The specimens received are examined by a curator, designated by the Surgeon General and by pathologists selected from the Academy's membership. In view of the expected increase in the material which will be sent to the Museum the Surgeon General has already set aside another officer and another technician to take care of the work and has arranged with the committee of the Academy to add more men if the necessity demands it.

In order to make the museum a national affair and to facilitate the handling of the increased material, the Academy's committee has found it necessary, first, to separate the Ophthalmic and Oto-Laryngologic Sections of Pathology, each department to proceed to functionate separately but in a similar manner. Second, in order to make this a national museum, a resolution was offered at the last meeting of the Academy instructing the Secretary to communicate with and invite the co-operation of the American Ophthalmological Society and the Ophthalmic Section of the A. M. A. To this end, I am requested to ask that you present the matter to your executive officers in order that they may take such action as, in their judgment, seems best. It is desired that a com-

mittee be appointed to confer with the Academy's committee, of which Dr. Gradle is chairman, in order that this Museum of Ophthalmic Pathology, in affiliation with the Army Medical Museum, may become a strictly national museum.

WEDNESDAY MORNING, JUNE 20th

The Meeting was called to order at 9.15 o'clock by the President, Dr. W. H. Wilmer.

Under the heading of "Exhibition of Cases and New Instruments and Apparatus," Dr. W. E. Shahan, St. Louis, exhibited the thermophore mentioned in his paper on "Selective Thermotherapy."

Dr. William C. Finnoff, Denver, presented five animals with different types of tuberculosis of the eye. One showed a lesion of the iris; one a lesion of the cornea; one atrophic spots on the iris following an old tuberculous iritis; and two choroidal patches.

Dr. Lucien Howe presented charts and drawings showing variations of the insertion of the extra-ocular muscles.

Dr. Edward Jackson, Denver, exhibited slides of glioma of the retina, showing the difference in staining qualities of the cells, their grouping, and the relation to the tissues of the eye.

The following papers were then read and discussed:

10. "Demonstration of Pathologic Slides."

a. "Siderosis Bulbi." Dr. Brown Pusey, Chicago.

Discussed by Dr. Nelson M. Black, Milwaukee, Wis., and Dr. Brown Pusey.

b. "A Case of Extensive Tuberculosis of the Eye." Dr. W. Gordon M. Byers, Montreal, Canada.

Discussed by Dr. Wm. C. Finnoff, Denver, Col.

c. "Persistent Hyaloid Artery." Dr. Wm. C. Finnoff, Denver, Col.

11. "Osteoma of the Orbit." Dr. Arthur J. Bedell, Albany.

Discussed by Dr. C. A. Veasey, Spokane, Wash.

12. "A Case of Adenocarcinoma Probably Arising from the Lacrimal Gland." Dr. Lee Masten Francis, Buffalo.

Discussed by Drs. E. E. Jack, Boston, and W. Gordon M. Byers, Montreal.

13. "A Case of Encapsulated Angioma of the Orbit." Dr. W. Gordon M. Byers, Montreal, Canada.

14. "Posterior Transillumination of the Eyeball." Dr. George S. Derby, Boston.

Discussed by Drs. E. C. Ellett, Memphis; W. E. Lambert, New York City; J. S. Lichtenberg, Kansas City, Mo.; George W. Jean, Santa Barbara, Cal.; and George S. Derby.

15. "Selective Thermotherapy." Dr. W. E. Shahan, St. Louis.

Discussed by Drs. John Green, Jr., St. Louis; Arnold Knapp, New York City; W. H. Wilder, Chicago; Lee M. Francis, Buffalo; and W. E. Shahan.

Executive Session

On motion of Dr. J. W. Charles, the Society went into executive session.

Dr. W. E. Lambert offered the following amendment to Article III, Section 6, of the By-Laws:

Following the word "offered" insert "not more then twenty-six to be read at the meeting of the society, all in excess of this number to be read by title."

The section as amended to read as follows:

Article III, Section 6: The Program Committee shall consist of three members, one of whom shall be the Secretary-Treasurer. *It shall select from the papers offered not more than twenty-six to be read at the meeting of the Society. All in excess of this number to be read by title.* It shall arrange the order of presentation of papers to be read before the Society. It may indicate special subjects for consideration and discussion, and invite members to report on these subjects at a subsequent meeting of the Society. *Any member has the right of appeal to the Council.*

Dr. Allen Greenwood offered the following amendment to Article VI, Section 3, of the By-Laws:

To omit the following words, beginning on Line 4: "Or who shall fail for five years to contribute to the scientific proceedings of the Society by proffer of a paper or participation by discussion acceptable to the Council."

The amended Section to read as follows:

Section 3. Any member or associate who shall be absent from regular meetings for three consecutive years without valid excuse shall be dropped from the roll, honorary members, emeritus mem-

bers, members of twenty years' standing or those then serving in the Army or Navy being excepted. An excuse for absence is valid only when a member is absent from the country or ill, or when there is illness of a member of his immediate family. This By-Law shall be printed in every call for the Annual Meeting.

The amendments will come up for action at the next annual meeting of the Society.

Dr. G. E. de Schweinitz, President of An International Congress of Ophthalmology held in Washington, April, 1922, presented the following report of Dr. Luther C. Peter, Treasurer of the Congress:

RECEIPTS

1. Contributions from members of the General Committee	$1,215.15
2. Membership subscriptions	10,901.22
3. Interest on bank deposits and other incidentals	294.86
4. Sale of Transactions	95.00
5. Contributions from members to defray deficit	2,511.91
Total Receipts	$15,018.14

DISBURSEMENTS

1. Printing: Pre-Sessional Volumes, programs, Transactions, stationery, etc	$10,649.72	
2. Secretarial expenses of committees	450.00	
3. Postage, telegrams, and other incidental expenses	706.24	
4. Local Entertainment Committee in Washington, expenses of guests, reporters, banquet, meeting halls, etc.	3,136.61	
Total Disbursements		14,942.57
Cash Balance		$75.57

Since the meeting of this Society the Secretary has received the following official notice from the Secretary of the International Congress of Ophthalmology postponing the Congress which was to be held in 1925:

The Committee of British Ophthalmologists, appointed to organize an International Congress in 1925, finds, with regret, that it is unable to do so in accordance with the conditions under which the British invitation was accepted by the Washington Ophthalmological Congress in 1922. It will be remembered that at Washington it was decided that the next Congress should be strictly international and that German should be one of the official languages. The Committee has since been informed that the Société Française

d'Ophtalmologie, the Société d'Ophtalmologie de Paris, and the Société Belge d'Ophtalmologie have passed resolutions to the effect that they feel themselves unable to participate in a Congress if Germans are invited. The Committee is of opinion that to proceed with the Congress in these circumstances would tend to perpetuate a schism in the ranks of ophthalmology and militate permanently against the progress of the science which all desire to promote. The Committee has, therefore, reluctantly decided to postpone the Congress.

Dr. Allen Greenwood moved that the Chair appoint a committee to investigate and revise the classification of certain retinal conditions as referred to by Dr. Edward Jackson. Motion carried.

The Chair appointed on this committee: Drs. Edward Jackson, F. H. Verhoeff, Marcus Feingold, and W. Gordon M. Byers.

Dr. Nelson M. Black moved that the Chair appoint a committee of three, or not more than five, to investigate the matter of the National Safety Code for the Protection of Heads and Eyes of Industrial Employees. Motion carried.

The Chairman appointed on this committee: Drs. Nelson M. Black, W. B. Lancaster, and Walter R. Parker.

The Executive Session adjourned, and the scientific program was continued with the reading of the following papers:

16. "Malignant Disease of the Retina." Dr. Edward Jackson, Denver.

17. "Autopsy Report of a Case of Bilateral Glioma Retinæ, with Gliomatous Involvement of the Iris." Dr. Arnold Knapp, New York City.

Papers of Drs. Jackson and Knapp were discussed by Drs. Francis Lane, Chicago, and Edward Jackson.

18. "Siderosis Bulbi with Dilated Inactive Pupil. Recovery of Pupillary Activity after Removal of Foreign Body." Dr. Nelson M. Black, Milwaukee.

Discussed by Drs. Marcus Feingold, New Orleans; W. M. Sweet, Philadelphia; Arthur J. Bedell, Albany, N. Y.; T. C. Lyster, Los Angeles, Cal.; and John W. Burke, Washington, D. C.

THURSDAY MORNING, JUNE 21st

The meeting was called to order at 9 o'clock by the President, Dr. W. H. Wilmer. The following papers were read and discussed:

19. "Supplementary Notes on Lipæmia Retinalis. Effects of Insulin." Dr. Wm. F. Hardy, St. Louis.

Discussed by Drs. Francis Lane, Chicago, and George W. Jean, Santa Barbara, Cal.

20. "The Significance of Deep Ocular Pain in Retinal Detachment." Dr. J. W. Charles, St. Louis.

21. "Bilateral Detachment of the Retina in Two Successive Pregnancies." Dr. Emory Hill, Richmond, Va.

The papers of Drs. Charles and Hill were discussed by Drs. Archibald L. Macleish, Los Angeles; C. A. Clapp, Baltimore; Allen Greenwood, Boston; John Green, Jr., St. Louis; W. B. Lancaster, Boston; E. V. L. Brown, Chicago; and J. W. Charles and Emory Hill.

22. "Observations on Phacoanaphylactic Endophthalmitis." Drs. Albert N. Lemoine, Kansas City, Mo., and Alexander E. MacDonald, Boston, Mass. (by invitation).

Discussed by Drs. W. B. Lancaster, Boston; George S. Derby, Boston; Arnold Knapp, New York City; W. H. Wilder, Chicago; W. H. Wilmer, Washington, D. C.; and Albert N. Lemoine.

23. "Monocular Diplopia with Especial Reference to that Associated with Cerebral Lesions." Dr. William Zentmayer, Philadelphia.

Discussed by Drs. J. W. Charles, St. Louis; W. B Lancaster, Boston; and William Zentmayer.

24. "Metastatic Choroiditis from Focal Infection." Dr. Allen Greenwood, Boston.

Discussed by Drs. Carl Fisher, Los Angeles; E. C. Ellett, Memphis; W. H. Wilder, Chicago; Emory Hill, Richmond, Va.; and Allen Greenwood.

25. "Optic Atrophy Manifested by Visual Disturbance Following Distant Hemorrhage." Dr. D. F. Harbridge, Phoenix, Arizona.

Meeting adjourned.

The following members were present and registered at the Fifty-ninth Annual Meeting:

Bedell, Arthur J.
Black, Nelson M.
Blake, Eugene M.
Brown, E. V. L.
Burke, John W.
Byers, W. Gordon M.
Calhoun, F. Phinizy
Charles, J. W.
Clapp, C. A.
Curdy, R. J.
Derby, George S.
Ellett, E. C.
Ewing, Arthur E.
Feingold, Marcus
Finnoff, William C.
Fisher, Carl
Francis, Lee Masten
Green, John, Jr.
Greenwood, Allen
Harbridge, D. F.
Hardy, Wm. F.
Hill, Emory
Holloway, T. B.
Howe, Lucien
Jack, E. E.
Jackson, Edward
Key, Ben Witt
Knapp, Arnold
Lambert, W. E.
Lancaster, W. B.
Lane, Francis
Libby, George F.
Luedde, W. H.
McGuire, Hunter H
Macleish, A. L.
Parker, W. R.
Pusey, Brown
Reese, R. G.
deSchweinitz, G. E.
Shahan, Wm. E.
Shannon, C. E. G.
Smith, Dorland
Sweet, William M.
Tarun, William
Török, E.
Veasey, C. A.
Waite, F. L.
Wilder, W. H.
Wilmer, William H.
Woods, Hiram
Zentmayer, William

HYDROPHTHALMOS (BUPHTHALMOS OR INFANTILE GLAUCOMA)—REPORT OF A CASE WITH MICROSCOPIC FINDINGS

SAMUEL THEOBALD, M.D., AND C. A. CLAPP, M.D.
Baltimore, Md.

We are presenting this subject to you for consideration for three reasons: First, because the subject has been brought to the attention of this Society only twice previously: first in 1880, when Dr. H. D. Noyes reported a case, of apparently secondary glaucoma, which was cured by total removal of the iris; and next, in 1898, by Dr. W. B. Johnson, who reported three cases in the same family, none of which was inflammatory; secondly, because of the rare clinical picture and, lastly, on account of the unusual autopsy findings, with the microscopic study.

While early writers used the term buphthalmia somewhat indiscriminately, Saint Yves, in 1722, gave a rather complete description of the condition, and Mackenzie, about one hundred years later (1830), described it still more accurately, although it remained for Mauthner, in 1867, to ascertain its glaucomatous nature.

The horizontal diameter of the buphthalmic cornea, according to Gross, has a maximum of 23.5 mm., with a mean of 16 mm. Iridodonesis is frequently present, and the media are usually clear despite the increased tension, which, however, is not as high as in adult glaucoma, since the external tunics of the eye yield more readily to the intra-ocular pressure. It occurs at birth in about 50 per cent. of the cases, and the great majority of the other cases develop before the third year, although occasionally it is delayed as late as the four-

teenth year. It is usually present as a family malady, although direct inheritance is rare. Laquer considers consanguinity a decided etiologic factor, having found it present in about one-third of his cases.

While the cornea is generally clear and often of normal thickness in the center, the periphery is usually thinned. Occasionally the increased ocular tension causes a diffuse haze of the cornea, as in acute adult glaucoma. As to the sclera there seems some difference of opinion, some reporting thinning while others an actual hyperplasia. The iris usually shows some atrophy and degeneration. The ciliary body is often atrophic and at times shows evidence of inflammation. The choroid often shows degenerative changes. The retina, in early cases, is nearly normal, but later shows atrophy.

The mechanism of the condition seems to be under dispute. While many theories have been advanced, those which have been given most credence fall into three groups.

Treacher Collins believes that there is an imperfect separation of the iris from the cornea, and that this is the result of an abnormal persistence of the prenatal condition of the ligamentum pectinatum, and he cites microscopic specimens which show bands of tissue stretching between the base of the iris and the cornea. Reis, Romer, Gross, and others have found an absence of the canal of Schlemm, either in whole or in part, and they believe this to be the cause of the increased intra-ocular tension.

Weeks and Mayou have observed cases in which posterior and anterior synechiæ were present, and which apparently were factors in causing the increased tension with the resulting enlargement of the globe.

The case which we wish to present is as follows: The child, a colored male, was born in the Maternity Ward of the Johns Hopkins Hospital on December 15, 1922, by operative breech delivery. The child breathed spontaneously and cried well, and had received no external injury. The eyes were observed to be prominent and

the cornea cloudy, no other external anomalies. Patient was seen by Dr. Theobald on December 17th, who made the diagnosis of buphthalmos, and on December 19th the following notes were made. Both lids were slightly edematous with protrusion (Fig. 1), due to enlargement of the eyeballs. The prominence of the cornea of the right eye as measured by the exophthalmometer was 17 mm., while that of the left eye was 18 mm. Both corneæ were cloudy (Fig. 2), with irregular elevations of the epithelium—the horizontal diameter of the right was 13 mm., that of the left 14 mm. The upper half of the right cornea was fairly clear, so that the pupil, which was moderately contracted (with eserin), could be seen; the anterior chamber was very deep. The left cornea was so cloudy that the pupil could not be seen, the cloudiness being greater in a horizontal band across the center, which apparently was partly due to incomplete closure of the lids. There was considerable circumcorneal injection present and the tension estimated by the finger was 50–60 mm. Hg.

As the normal amount of prominence and the diameter of the infant cornea were in question, measurements of normal infant eyes were made. These gave an average of 10 mm. with the exophthalmometer and 8 mm. as the diameter of the cornea.

A note by Prof. J. Whitridge Williams was as follows: Immediately after birth the unusual prominence of the eyes attracted attention, and, on inspection, they were found to bulge very greatly beyond the usual level. On opening the lids both corneæ were observed to be partially opaque and the eyeballs were more tense than normal.

The protrusion of the eyes was such as to remind one of the condition following sinus thrombosis, but palpation of the fontanelles showed no apparent increase in intracranial pressure.

The opacity of the cornea momentarily suggested the possibility of an intra-uterine gonorrheal infection, but smears gave negative results.

The child made a very bad impression. The temperature was persistently subnormal. It lost weight steadily for the first seven days, and then began to gain in the usual manner, so that at the time of death, December 27, 1922, it had reached within 30 gm. of its birth weight. Up to the day of death the child acted normally in all respects, cried, suckled, and made the usual movements without any signs of paralysis or other impairment.

Autopsy Report.—The autopsy report by Dr. W. G. MacCallum

is given in part as follows: Frog-like appearance of face with prominent eyes suggests anencephalia, although the frontal bone is well formed.

Opening of the skull showed the intracranial cavity to be filled with about 200–250 cc. of a chocolate-colored fluid, the brain being reduced to a small nodule 4 by 3 by 2 cm.

Microscopic Examination.—The corneal epithelium is of nearly normal appearance at the periphery, consisting of from five to eight layers of cells and in general having well-stained nuclei. As one approaches the center of the cornea, the thickness of the epithelial layer varies, and the nuclei seem gradually to undergo degeneration, their places being taken by vacuoles (Fig. 3), so that near the center of the cornea there are few nuclei seen, and even the protoplasm assumes a granular appearance. The surface of the epithelium is wavy and irregular, this being more pronounced over the central portion, where the degeneration is most marked. The area of greatest irregularity of surface and degeneration of the cells corresponds to that portion which clinically appeared steamy and cloudy.

The substantia propria is of normal thickness around the periphery, but shows a very decided thinning just above the center of the cornea (Fig. 4). There seems to be an undue separation of the fibers of the substantia propria, but this may be the result of fixation. The endothelial cells upon the inner surface of the cornea are thinned and elongated and Descemet's membrane is thrown, more or less, into waves.

The ciliary bodies consist of small atrophic masses, the inner portion consisting of ciliary processes, being long and finger-like, with an outer layer of epithelial cells, immediately beneath which is a dense layer of pigment, the center of the processes being composed of loose connective-tissue cells.

The iris is exceedingly atrophic and thinned, the outer portion consisting of hardly more than a well-marked pigment layer on the posterior surface, with a few stroma cells and blood-vessels, the pupillary margin being considerably thicker and showing a few muscle cells.

The Filtration Angle: The angle between the cornea and base of the iris varies considerably in the different sections, some showing an extension back to the filtration spaces, although never back of them, as occurs in normal eyes, while in other sections there is a very decided incomplete separation at this point, which would

Fig. 1.—Shows bulging of eyelids; fairly well-formed brow.

Fig. 2.—Lids retracted, showing large size of cornea with cloudiness.

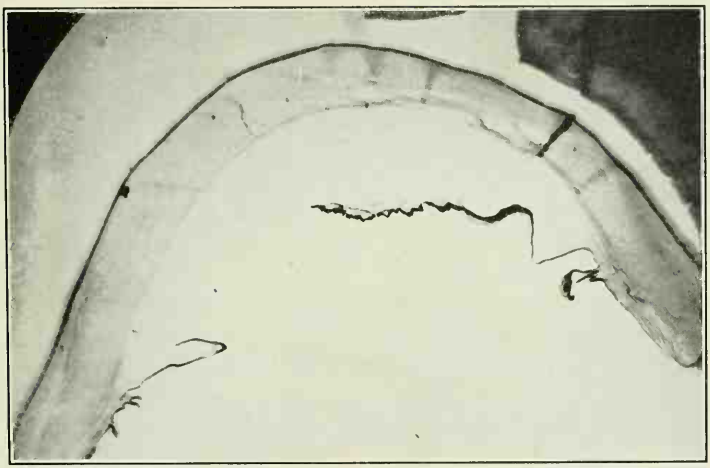

Fig. 3.—Anterior segment of eye. Cornea of normal thickness except above center; iris and ciliary processes extremely atrophic.

Fig. 4.—Corneal epithelium under high power, showing clear areas, probably edema.



Fig. 5.—High-power view of filtration angle. Root of iris adherent far forward. Filtration spaces small and far back.

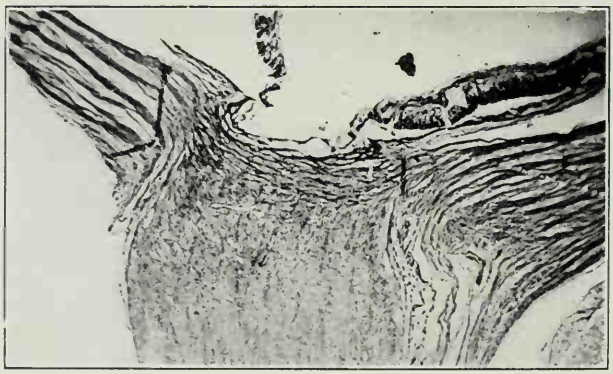

Fig. 6.—Low power of optic nerve, with only moderate cupping. Retina nearly normal. Choroid and sclera thinned.

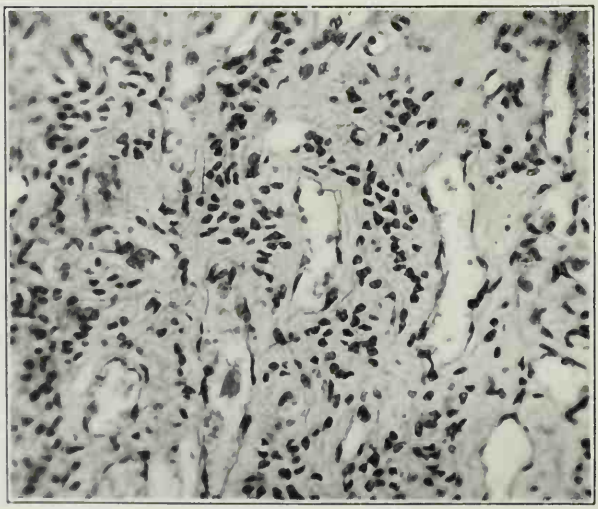

Fig. 7.—High power of optic nerve, with distorted nerve tissue, reticular spaces, and large number of blood-vessels.

confirm the theory advanced by Mr. Treacher Collins of an incomplete separation of iris from the cornea or a prenatal condition of the ligamentum pectinatum. This is shown very conclusively in some sections (Fig. 5), where the iris is adherent to the cornea for some distance in front of the atrophic ciliary body. The separation of the iris from the cornea, it may be remarked, is more complete in the normal fetal eye at six months.

The retina is practically normal. The choroid is thin and its spaces filled with red blood-cells. Very few pigment cells are found in the choroid, although the pigment layer of the retina is well marked. The sclerotic is thinned, with considerable separation of its fibers—this again may be due to fixation.

The optic nerve shows very curious changes. There is some cupping but not pronounced (Fig. 6). It resembles more the cup of extreme atrophy than of glaucoma, as the shelving is not precipitous.

The cribriform membrane is made up of loose connective-tissue cells, below which is seen a distorted optic nerve, made up largely of thin-walled blood-vessels, with a large number of neuroglia cells and few axis cylinders (Fig. 7).

After careful study of these sections we think we are justified in our belief that this case resulted from an incomplete separation of the cornea from the iris, rather than an absence of the canal of Schlemm.

Contrary to many previous reports as to thinning of the cornea at the periphery with normal thickness at the center, this case corresponds to one reported by Seefelder,* which showed thinning at the center with normal thickness at the periphery. The peculiar degenerative changes in the optic nerve are probably not due to the increased tension but to the anencephalia. J. Meller† has reported a somewhat similar condition.

While the claim of heredity has been made as an etiologic factor, we could obtain no evidence that such was the case in this instance, although the family history was very unsatisfactory.

Finally, we suggest a more careful nomenclature for these

* Arch. f. Ophth., ciii, p. 1.

† Arch. f. Ophth., vol. xcii, p. 34.

cases and believe hydrophthalmos or buphthalmos should be used for those cases of increased tension and general enlargement of the eye resulting from a congenital defect, and classifying those due to injury or an inflammatory condition as "secondary glaucoma of childhood," as both clinically and pathologically they are quite distinct, and the present method of classifying all as hydrophthalmos or buphthalmos is very confusing and unscientific.

DISCUSSION

DR. GEORGE F. LIBBY, Denver, Colo.: A white girl baby of four and one-half months was brought to me for examination on November 27, 1913, on account of congenital blindness. The eyes were prominent and stary, pupils moderately dilated, the anterior chambers very shallow, the lenses cataractous, and the tension stony hard. The child was very defective mentally. There was no history of blindness in the family. A diagnosis of congenital binocular buphthalmia was made; and, in the absence of active inflammation, no treatment was instituted.

In January, 1914, there was no apparent change; but two months later the anterior chambers were seemingly deeper and the tension slightly reduced, and there was light perception.

By June, 1915, the anterior chambers were restored, and the tension of the right eye was only slightly elevated, that of the left being normal. The pupils were of normal size; small objects were perceived. Convergent squint was developing.

At this time Dr. A. E. Ewing saw the child, concurred in the diagnosis, and agreed as to the advisability of non-operative, conservative treatment (no drugs) for the present; discission to be done in two or three years.

In June, 1917, Dr. W. H. Crisp made a V-shaped opening in the left capsule. Lens substance protruded through this rent. Several other free discissions were made, with very moderate reaction.

In January, 1919, the right lens capsule was freely needled, there being no lens substance. Atropin was instilled after the needlings, without ill effects. No iritic adhesions were present. Plus 10 spherical lenses seemed to help the vision and mentality to some extent.

Death occurred on May 15, 1919, after a month's severe illness. One lung was found almost destroyed by tuberculosis (which the

father had contracted many years before the child's birth), and the other lung was badly involved. As the child was healthy looking and very active, none of the many physicians who had been consulted suspected tuberculosis.

The spontaneous relief of the glaucoma is to be explained, I think, by a delayed development of Schlemm's canal.

DR. F. PHINIZY CALHOUN, Atlanta, Ga.: I wish to present an unusual case of buphthalmos in connection with the report presented by Dr. Clapp. This eye was removed from a thirteen months' old white child. The father, an ignorant white country man, delivered the mother of the child, and at birth he discovered that the right eye was protruding, and this increased as the child grew older. On account of the eye being very irritable, it was deemed necessary to enucleate it. The opposite eye was normal.

The unusual feature about this case is the extreme size of the globe. The weight is about 22 gm.; the anteroposterior diameter is 40 mm., and the transverse, 35 mm. On section the iris was found adherent to the posterior surface of the cornea, there was an absence of the canal of Schlemm, and there was complete atrophy of the ciliary body.

Cantonnet reported a similar case in 1912. His measurements were: anteroposterior diameter 42 mm., and transverse 30 mm.

DR. WILLIAM ZENTMAYER, Philadelphia: Some years ago I placed on record a microscopic study of a case of congenital glaucoma in which there was a congenital coloboma of the iris and an entire absence of the canal of Schlemm. I believe that in a majority of the cases on record that have been studied microscopically an anomaly of Schlemm's canal has been found. So many of my cases had been in colored people that I thought perhaps the condition was more common in this race and that congenital syphilis might be a factor in the production of the prenatal condition, but a questionnaire sent out through the country indicated that there is apparently no such connection.

DR. E. C. ELLETT, Memphis, Tenn.: The accompanying microphotographs are of the right eye of a boy, aged seven years, which was removed in 1914. The eye had been enlarged all his life and showed the usual changes of buphthalmos, with a corneal diameter of 15 mm., and opaque lines in the cornea, such as are said to be due to ruptures in Descemet's membrane. Tension 57. The left eye was normal. The sections show the extreme cupping of

the disc, the apparently open anterior chamber angle, which is, however, filled with fetal tissue, and the absence of the canal of Schlemm. For comparison, the angle of a glaucomatous eye of an adult is also shown, in which the angle is closed and the canal of Schlemm present. These sections are quite similar to the illustrations in Elliot's book. In looking over some other sections of eyes removed for a variety of conditions, a number were found in which the canal of Schlemm was not to be seen (Figs. 1, 2 and 3).

DR. WILLIAM ZENTMAYER, Philadelphia: Dr. Holloway spoke to me about a case we saw in consultation; I hope he will refer to it.

DR. T. B. HOLLOWAY, Philadelphia: This case was brought to me in consultation. A third opinion was desired, and Dr. Zentmayer was consulted, and he subsequently operated.

The child was about three weeks of age when the mother noticed the prominence of the right eye. It was quite evident at the time of my observation, but in the left eye there was only an increase in the diameter of the cornea. There was no cupping, but each disc appeared to be hyperemic.

For a year or more a child with a unilateral buphthalmos, which in my experience is unusual, has been coming to the University Hospital. The child is about four years of age. Nothing has been done in an operative way and there has been no advancement of the condition and the other eye has remained normal.

It has been my good fortune to see quite a number of these cases, because there are always eight or ten of this character in the Pennsylvania Institution for the Instruction of the Blind at Overbrook. I have seen all kinds of variations in the tension—at times a typical buphthalmic eye with plus tension on one side while the other eye was much smaller, undergoing atrophy, with minus tension.

DR. MARCUS FEINGOLD, New Orleans, La.: I should like to place on record a clinical symptom which I noticed about one year ago on a two-year-old Italian child with bilateral buphthalmos—a symptom which up to that time was entirely unknown to me as being characteristic of the disease. It was almost impossible to open the child's eyes, and the moment the lids were pried apart a gush of tears would come out. Under pilocarpin treatment alone lacrimation and blepharospasm disappeared.

DR. T. B. HOLLOWAY, Philadelphia: Dr. Feingold's statement

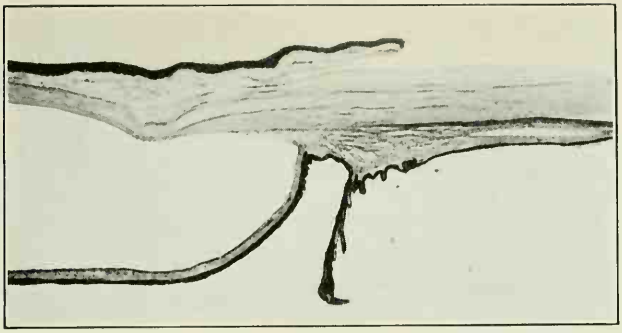

Fig. 1.—Angle of the anterior chamber in buphthalmic eye, showing the open angle filled with fetal tissue and the absence of the canal of Schlemm. Ellett.

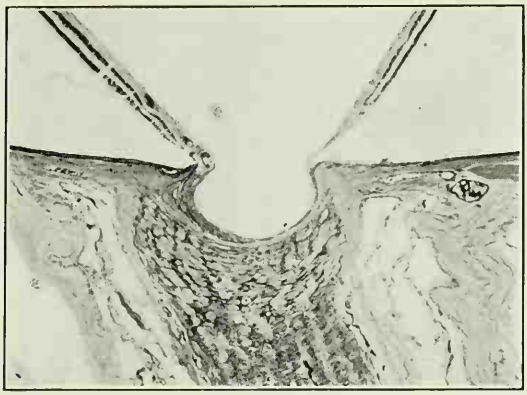

Fig. 2.—The cupped disc of buphthalmic eye. Ellett.

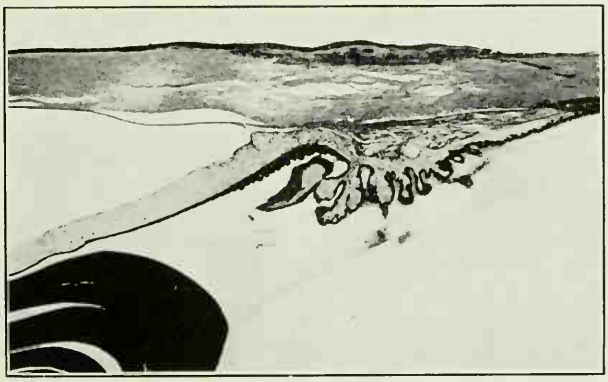

Fig. 3.—Angle of anterior chamber of an adult glaucomatous eye, showing the canal of Schlemm. Ellett.

recalls that in a number of cases I have had under observation this same symptom has been present, and all too frequently you encounter the associated annoying and aggravating reflex sneezing. I remember several children in which this was most persistent, induced as soon as their heads were raised and attempts were made to open the eyes. Holocain was efficient in checking this.

DR. JOHN GREEN, JR., St. Louis, Mo.: I should like to place on record a case that has some interesting features. A boy was first seen at the age of two days with typical bilateral buphthalmos. Miotics were used until the child was three years old; then an Elliot trephining on one eye was done, which was followed by a reduction in tension. A year later the child developed a pneumococcus infection of both conjunctivæ. The non-operated eye developed a corneal ulcer and was lost. The trephined eye recovered. A younger sister of the patient has unilateral buphthalmos.

DR. L. V. STEGMAN, Battle Creek, Mich. (by invitation): An interesting case of double buphthalmos came to our clinic about five years ago, and has been under observation at intervals since that time. The child was ten weeks old when brought to us, and weighed 5¾ pounds—one-quarter pound more than at birth. The mother said that at birth the eyes protruded like marbles. The obstetrician, a surgeon and an oculist who saw the child shortly after birth diagnosed the condition as inflammatory glaucoma. At our examination there was slight injection of the conjunctival and ciliary vessels, the cornea was opalescent, and the iris could not be descried. The ocular tension was high. A double iridectomy was performed and seemed to relieve the pain at once, as the child stopped crying and his food agreed with him. Two and a half years later he walked toward the light to play and seemed to see his hands. There were searching movements of the eye; intraocular tension low; eyeballs sunken.

He is now five years old and is failing to make normal mental and physical progress. It is impossible to make out the relations between the periphery of the iris and the cornea. The eyeballs are more sunken, with dark circles about them. There is a white band across the dry and lusterless cornea below the center. It is a question whether this white xerotic band is due to general malnutrition and deficiency of vitamins, or to local trophic changes in the regressive eyes. I asked about his diet and learned that he ate only what he desired, namely, tapioca, potatoes with a little butter,

and occasionally an eggnog. The question arises, had the dietary imbalance, the lack of vitamins, anything to do with the lack of further development of the eyes?

DR. C. A. CLAPP (closing): Just a word about anencephalia. Dr. W. G. MacCallum was very much interested in the case and made a diagnosis of anencephalia from the general formation of the head. I thought this an error and that the prominence of the eye was due to enlargement of the eyeball and not to the receding brow which shows in anencephalia. To verify this we went into the museum and found any number of cases of anencephalia with prominent eyes, but none having the enlarged eyeballs.

Heredity has been brought forward as an etiologic factor, and undoubtedly it is, for several instances have been found in one family. In this particular case the family history is very unsatisfactory, but we could find no evidence of anencephalia.

The child did not have lues, according to serologic tests of both mother and child.

As to the glaucomatous cup—my glaucomatous cups have a great deal more excavation than this showed. The nerve-cells themselves and the entire nerve are almost free from normal nerve tissue, and I am inclined to think, while I agree it is open to question, that the cupping is chiefly due to lack of nerve tissue rather than to increased pressure. It was impossible to ophthalmoscope this case, the cornea being too cloudy for that purpose.

REPORT OF TWO EXPERIENCES WITH ACUTE GLAUCOMA

HIRAM WOODS, M.D.
Baltimore, Md.

The symptom-complex called glaucoma assumes such varying aspects, seems to possess so many and such unexpected facilities for taking us by surprise, that cases varying from the strictly orthodox kind seem worthy of note. It is to two such cases I wish to call attention.

CASE I.—Mr. H., Lawyer.

Eye History.—Has been under my care since 1900, when I made

his first refraction correction (R.E.,+0.25 cyl. ax. 80°; L.E.,+ 0.25 cyl. ax. 95°); presbyopia, +0.87 sph. each. From then on to the glaucomatous attack in 1920 he was seen at intervals for changes in his presbyopia. The necessity for the changes was usually indicated by pain on near work rather than poor vision. At various times his field was taken and found normal. Besides these refraction changes, natural to his time of life, he had, in Sept., 1919, a right subconjunctival hemorrhage. This led to a thorough systemic examination, which was essentially negative. Blood pressure was 140/85; the first molar on the right upper jaw was thought to be infected and was extracted. These temporal pains were the only items in his history which could possibly be interpreted as prodromes of glaucoma.

Glaucomatous Attack in the Right Eye.—Feb., 1920; he was now sixty-seven years of age. On the afternoon of Feb. 13th, while working in his office, he experienced some blurring of vision and slight discomfort in the right eye. During the evening he had three successive painful attacks with this same blur. They lasted only a few minutes. He went to bed at his usual time and could then see perfectly. At 2 A. M. he was awakened by violent pain in the right eye. I saw him about 8 A. M., when examination showed deep conjunctival and circumcorneal injection, cornea "steamy," pupil two-thirds dilated and inactive: fundus could not be seen. Tension (digital) was fully +3. The eye could not be "pitted." Nothing was to be gained by the use of the tonometer. Vision = 15/200 (hazy). For two and one-half hours I used eserin (one to four grains to the ounce) every fifteen minutes without visible effect on the pupil. Vision fell to recognition of moving hand at two feet. I advised operation as soon as possible, but expressed the wish to have someone see the case with me. Dr. Harry Friedenwald kindly responded at once. Operation was done early in the afternoon. The pupil had contracted slightly as compared with the morning. The patient thought vision was a little clearer.

No special preparation for general anesthesia had been possible. The eye was cocainized and was insensitive to forceps and keratome; but the latter, though new, had apparently a dull point, so I used a cataract knife, making the puncture and counter-puncture about one mm. back of the limbus. Then gas was administered. As soon as the iris was grasped in the forceps and before traction, there was a gush of blood, apparently from the iris tissue. Blood

did not "trickle" out, it came in a spurt, flooding the entire field of operation and cheek. I held on to the iris, which I could not see. An assistant wiped away enough blood to enable me to get an instant's glimpse of the limbus section and forceps. A bit of iris was drawn out and excised through the blood with increase in hemorrhage. I kept up gentle pressure with my hand for several minutes before bleeding ceased. Of course, the anterior chamber filled and remained so; but there were no further complications and recovery was uninterrupted. The iridectomy is not ideal. There is a tag of iris about 2 mm. long hanging from the upper edge of the temporal side of the coloboma, but the operation was not done for cosmetic purposes.

Three weeks later, with correction of the post-operative astigmatism, vision was 20/20 with practically normal field. There was a slight narrowing in the upper temporal quadrant. Since operation there has been no visual loss in either eye.

Glaucomatous Attack in the Left Eye.—On the 24th of November, 1920 (a few days over nine months after the attack in the right eye), Mr. H. came for inspection. He felt "uneasy," but could hardly say why. He had posted himself on glaucoma and knew it was a "bilateral" disease; that sooner or later the other eye would probably be involved. I found no change in the operated eye and nothing to excite suspicion in the other. Tension felt normal to fingers. I tried to reassure him and purposely omitted the tonometer. This mental anxiety is worthy of note because of the sequel of events which quickly followed. He did not see me the next day. The following morning, the 26th, he described pain in the left eye "similar to that before the attack in the right." Nothing was to be observed externally, vision was 20/20 in each eye, and the fields were not contracted. The left pupil was not dilated and showed normal direct, consensual, and convergence reactions; but the tonometer (Schiötz) registered 55. He was excessively anxious and expressed the unusual wish that, if he was to have glaucoma anyway, this might be an attack and then after operation he could dismiss it. He was given eserin and forbidden work. The next day the left eye was painful; no hyperemia. Vision = 20/20. Concentric contraction of field for white and colors, about 10°. He had been using eserin, grains four to the ounce, since the day before, when the tonometer registered 55. Two drops of a two per cent. solution of holocain were put in the left eye for tonometric anesthesia. I stood by the

patient and did not lose sight of the eye for a second. Two or three minutes after instillation of the holocain I saw the left eye suddenly flush and the pupil dilate. I felt the globe harden. It was a most astounding sight. In a fraction of a second the pinhead pupil seemed to leap to maximum dilatation. I felt that operation was imperative, but he was unable to drop everything at the moment. As vision was unaffected, I consented to use eserin for a day or two. The next day the eye was slightly injected, pupil "pinhead," tension 24, and central vision 20/15. The same was true of the two following days. Thus, three days passed with normal tension and unimpaired vision. After another twenty-four hours tension rose to 45, in spite of miosis, without loss of visual acuity. The next day tension was 30. Iridectomy was done on the left eye the following day under the same anesthesia as before. About ten o'clock at night I was informed that Mr. H. was in agony. I went to him at once and never saw a man in greater pain. It was neither hysterical nor the nervous discomfort which sometimes follows the use of a local anesthetic as the effects wear off. There was just the desperate burying of the head in the pillow, the quiet, uncomplaining, struggling effort to endure. Nothing wrong could be seen, so far as I felt justified in looking. From my standpoint, I had operated upon an eye with normal vision because of uncontrollable hypertension and malignant glaucoma seemed, at least, very probable. In course of time, morphia somewhat quieted him. The pain lasted, coming in paroxysms of gradually lessening severity, for three days. He was given as much salicylate of soda as he could stand, beginning with 10 grains every three hours, and increasing to 20, beyond which we could not go. After this, recovery went on without interruption. There is still normal vision. It is worthy of note that Mr. H. went through an attack of broncho-pneumonia this past winter without any eye trouble.

CASE II.—Mr. J., Hebrew, aged fifty-one years, merchant.

Eye History and Condition.—Four years previous to my first examination, Oct. 25, 1919, at the age of forty-seven, he consulted the late Dr. Robert L. Randolph for blurred vision in the right eye. The left eye had never been in trouble. Dr. Randolph corrected the refraction error for reading only. When I first saw Mr. J. his vision was, R.E., 20/40, with +1.00 sph.; L.E., 20/20, with +1.00 sph.⊂+1.25 cyl. ax. 180°. Presbyopia was +1.75 sph.

Tension, right eye, was 30 by the tonometer. Pupil a little larger than left, normal reactions, both eyes. Typical glaucomatous cup in right papilla. Field limits: 10° above, 40° laterally, and 65° below. Left eye, tension and field normal, negative fundus and media. He declined operation.

From October, 1919, to July 1, 1920, he came fairly regularly for examinations, then he ceased. About nineteen months later, February 22, 1922, I was summoned to the patient's home by his physician, Dr. Charles L. Larned. The patient had had grippe from the 5th to the 13th of February, when facial erysipelas developed. The lids were swollen and hard; there existed a mucopurulent conjunctivitis; the left cheek and ear were edematous, with a line of demarcation sharply drawn on the cheek. He told me that up to the beginning of his illness, February 5th, he had been able to read with the right eye, but was conscious of a defect in the field. He had had no difficulty with the left eye. He did not use his eyes during the attack of grippe, and since the onset of the erysipelas his face and eyes had been covered with cloths. He had no pain, but on the day before (February 21st) he discovered that he could not see. Vision was reduced to doubtful light perception in the right eye and to the moving hand in the left. Both pupils were dilated 8 mm. or more in diameter and inactive. Tension was at least plus 2 to the fingers. It was impossible to use the tonometer. Operation under these conditions was out of the question. Pilocarpin, three grains to the ounce, was ordered to be used every two hours. At 8.30 the next morning the pupil was somewhat smaller, condition otherwise the same. Eserin solution, four grains to the ounce, was ordered to be used every hour. That evening the tension was 90 right and 60 left. Eserin was continued for six days, and the salicylates given internally. March 1st, at 8 A. M., tension was 60 each. V.L.E. = l. p.; R.E., doubtful. With a view of reducing conjunctival irritation, I used, in the left eye, one drop of a one to one thousand adrenalin solution. Within a few minutes the pupil, which had slightly contracted, suddenly dilated to about 6 or 7 mm. (estimated). March 2d, at 8 A. M., pupil unchanged; V. = light projection, each eye.

I did an iridectomy on both eyes under ether. The left iris was shoved tightly against the periphery of the anterior chamber, but the keratome entered without trouble. A fairly good iridectomy was obtained. In the right eye the iris was friable. Only a small iridotomy was possible. Recovery was uncomplicated. On March

22d he could see to get about alone. In May, two months after operation, he had 20/30, and since September, 1922, has had 20/20 with his post-operative correction, +2.50 sph. ⌔ +2.50 cyl. ax. 180°.

The right eye obtained nothing from the operation save reduced tension. In September, 1922, he claimed seeing the moving hand. I have heard from him recently that he remains well.

Comments.—In the first case, was pain accompanying the series of presbyopic changes important? I confess that since I had this case I have paid more attention to this symptom, but so far have not been able to associate it with impending glaucoma. A second question is, was the free use of eserin during the morning of the day of the first operation (on the right eye) conducive to the hemorrhage? Naturally, as the pupil contracted and iris tissue expanded to, at least, a moderate degree, there was more room for blood in the iris. In view of the outcome and of the further fact that acute first attacks usually recover, might it have been better to delay operation? May be so: the way both cases endured acute tension for several days, when delay was unavoidable, would seem to indicate that no harm would have resulted if we had waited. However, this was the nearest approach to fulminating glaucoma that has ever come my way, and I fear that in another such case I should do just as I did in this. But I am open to conviction.

It was my good or bad fortune to have the left eye under observation when the acme of the attack was reached. I am convinced that the holocain had nothing to do with it. Then came three days of relief, unimpaired vision, and normal tension. Suddenly, in spite of full miosis, the tension flew up. Why? I do not know. Then came the agonizing pain after operation and, finally, recovery. I incline to the belief that the post-operative pain was just the climax of the acute glaucomatous process which went on in spite of the operation, but which was finally suppressed by the iridectomy.

In the second case, loss of the eye from infection would

have almost certainly followed operation during the erysipelatous outbreak. I cannot see that there was anything to do but wait and use miotics. Yet there was no pain from either the eye or erysipelas. Doubtless the latter was the exciting cause of the glaucoma in an eye whose fellow had already had the disease. Although the left eye was blind and, for a period of at least nine days, tension varied from 40 to 90, no permanent harm was done and iridectomy seems to have effected a complete cure.

A word about dilatation following use of adrenalin. Arnold Knapp has published a short paper on "The Action of Adrenalin on the Glaucomatous Eye."* By quotations from various authors he shows that adrenalin has no effect on the normal pupil, that there is apt to be dilatation from its use in diabetes or Graves' disease, that the adrenalin pupillary reaction has "diagnostic importance" in "insufficiency of internal pancreatic secretions," that the stimulation to the radiating fibers of the iris comes through the sympathetic system and causes dilatation; that the post-ganglionic fibers carry inhibitory impulses to the pupil which normally prevent dilatation; that if adrenalin "dilates the pupil, the post-ganglionic fibers, inhibiting the dilator pupillæ, have been eliminated."

Its effect on tension varies from nothing to decrease or increase. He tested the effect of adrenalin in 65 cases of primary glaucoma with these results: 1. The pupil dilated in 60 out of 65. 2. The tension was unaffected in 40, decreased in 20, and increased in 5.

He thinks that "hypotony results from the relief of mechanical causes and that in some glaucomas there is a retention of aqueous in the posterior chamber and by dilatation of the pupil by adrenalin this stasis is corrected." While this is undoubtedly sound reasoning, it is equally true that if the mydriasis of adrenalin or any agent pushes the iris further back in the already narrowed filtration angle, an *increase* of

* Trans. Amer. Ophth. Soc., xix, 1921, p. 69.

tension may follow. In my case miotics did not neutralize the adrenalin dilatation. This is contrary to usual observations. Further, in Knapp's series there were 15 cases showing glaucoma in only one eye. In 12 of these 15 adrenalin dilated the pupil in the supposedly normal eye. He suggests that a susceptibility to adrenalin may be present before clinical signs of glaucoma appear and, by inference at least, pupillary response to adrenalin may give us warning.

Dr. Knapp's studies suggest throughout a relationship between primary glaucoma and the sympathetic nervous system. It is not going far afield to extend the inquiry to vascular changes, vasomotor stimulation, or inhibition. In my first case in one eye there were evidently surcharged iridic vessels and operative hemorrhage; in the other eye sudden episcleral injection, dilatation of the pupil, and rise of tension. Were these merely the result of previous hypertension or of vascular dilatation from some unknown cause? In my second case there were adrenalin dilatation of the pupil and rapidly increasing tension. These, in the light of Dr. Knapp's findings, must have come from inhibition through the sympathetic system. It is surely possible that the vascular phenomena in the first case came from similar influence—inhibitory vasomotor influence. This affects prognosis.

Both patients were relieved by an operation thought to act chiefly, if not solely, through improving drainage. If that is all, *i. e.*, if hypertension and vascular phenomena were secondary to defective drainage, we have probably gotten the upper hand, but if the sequence of events is the other way, and some pernicious vasomotor influence is still there, permanency of recovery is less certain. We have sad knowledge of the fact that often the best executed operation fails to cure permanently. We reason on tension because it is the best guide we have; but, all the same, we have a subconscious conviction that there are other things in glaucoma beside hypertension, and if we stop there we are not at the bottom of the problem.

DISCUSSION

DR. EDWARD JACKSON, Denver, Col.: Dr. Woods' observation of the rapid, striking changes of the two eyes in his first case is extremely interesting. It is probably an exaggerated instance and an explanation of what occurs in acute glaucoma as a rule. It forces upon us a factor in glaucoma that certainly we have neglected for many years, but which now is beginning to attract the attention it deserves, and that is the vascular factor. The rapid changes which occur in these cases, to my mind, are impossible on the theory of simple defective drainage. The dilatation of the blood-vessels within the scleral corneal coat, particularly in the choroid, seems to be the rational explanation of exacerbations. That may occur quickly, as under Dr. Woods' observation, or more slowly. But one such case, observed as this one was, certainly has great value in the light it throws on our understanding of glaucoma.

DR. C. A. VEASEY, Spokane, Wash.: About twenty years ago I reported before the Section on Ophthalmology of the College of Physicians of Philadelphia a case in which there was restoration of useful vision in a complicated case of acute inflammatory glaucoma of ten days' duration with visual acuity reduced to the perception of light. The history elicited at that time showed a similar attack had occurred six years before in the other eye, and that in spite of continued medicinal treatment by a competent oculist the vision was entirely lost.

Immediately following a broad peripheral iridectomy on the eye which had been blind for ten days, the tension was at once restored to normal, the anterior chamber quickly reformed, and the patient recognized large moving objects, but it was noted that the lens was quite opaque and markedly swollen. This condition continued *in statu quo* for about two months, when the patient appeared with the lens enormously swollen, the anterior chamber shallow, the iris inflamed and attached to the anterior capsule, and marked intra-ocular tension. The lens was extracted, tension was immediately reduced, and the patient subsequently obtained 5/40 vision.

This patient seemed to illustrate, like those of Dr. Woods, that, even though intra-ocular tension has been present for a long time and the patient practically blind, it is much wiser to operate, because in a certain number of cases useful vision will be restored.

DR. ALLEN GREENWOOD, Boston, Mass.: One interesting feature in Dr. Woods' report is illustrated by the cases of acute glaucoma

that follow within a few hours, in the opposite and apparently normal eye, after operating upon an eye for acute glaucoma. That has been my experience in two cases of acute glaucoma. The eye was operated on one day, and the next morning on making a visit I found the patient in great pain, the other eye having developed an attack of acute glaucoma that did not yield readily to eserin or pilocarpin, but demanded immediate operation.

DR. ARNOLD KNAPP, New York: The difference in behavior of glaucomatous eyes to adrenalin is very interesting. While the reduction in tension can be definitely explained by the fact that the opening of the pupil permits egress of aqueous retained in the posterior chamber, we do not know how to explain the increase in tension which follows the instillation of adrenalin in a small percentage of cases.

DR. HIRAM WOODS (closing): I think Dr. Greenwood's explanation is correct. I have never had a case of glaucoma developing in a sound eye after operation on the other, but I follow the time-honored method of using a miotic (eserin) in the other eye.

As to why the tension went up after adrenalin, of course it is more or less guesswork. Dr. Knapp in his paper states he considered the fall of tension after use of adrenalin as due to mechanical reasons, fluid coming from the posterior chamber after the pupil dilated under adrenalin; but it would not dilate unless it was a glaucomatous eye. If you have glaucoma, making adrenalin dilatation possible, and if dilatation takes place after adrenalin is used, the effects will depend largely upon the extent of your dilatation and the condition that is there. Any mydriatic might dilate the pupil just enough to let out fluid; but if the iris is pushed still farther back into the filtration angle by adrenalin or anything else, you could easily have a rise of tension. In this case the iris was found shoved back into the periphery, and that happened after adrenalin had been used. My idea is that the man first had glaucoma, which made adrenalin dilatation possible. Adrenalin was used, and, the dilatation coming on, the iris got beyond control and went back into the filtration angle. Of course, that is more or less hypothetical, but it is the only explanation I can give.

IRIDECTOMY IN GLAUCOMA: A NEW TECHNIC

E. TÖRÖK, M.D.
New York

Iridectomy is still the classic operation for glaucoma, and is the one which is performed in preference to other procedures in all cases where its performance promises success.

There are many theories advanced to explain the mode of action of iridectomy. Most of these are only of historic interest and therefore not enumerated in this paper. The one which is generally accepted is based upon the theory that the maintenance of normal intra-ocular pressure is accomplished by the aqueous being drained off through the spaces of Fontana by the Schlemm canal, thus having a continuous flow. Pathologic examinations of glaucomatous eyes show that the spaces of Fontana in glaucoma are obstructed so that the aqueous cannot be drained. This obstruction may be due to the root of the iris being pressed against the posterior surface of the cornea without being adherent to it, or the root of the iris may be solidly glued to the posterior surface of the cornea by organized plastic exudate. This organized plastic exudate may also entirely fill and obliterate Schlemm's canal.

Now, pathologic examinations of glaucomatous eyes, where iridectomy was successfully performed, but which were enucleated for some other reason, have shown that the reduction of tension was obtained either by the opening of the passage at the iritic angle for the exit of the fluid or by the formation of a new channel by means of a cystoid scar. Therefore, a successful operation for glaucoma must either reëstablish the natural channel of drainage or form a new permanent channel. This, according to Elschnig, can be obtained by

either detaching the root of the iris from the periphery of the cornea or incising it, thereby producing a direct communication between aqueous and Schlemm's canal. The opening between the anterior chamber and Schlemm's canal must be large so that a sufficient quantity of aqueous may be drained off through it to maintain normal intra-ocular pressure. The reëstablishing of this communication can be obtained by a large peripheric iridectomy, by means of which the root of the iris is detached from the cornea and then excised so that it cannot reattach itself again.

This is the universally accepted theory nowadays as to the mode of action of iridectomy in glaucoma. It is self-evident, therefore, that iridectomy in glaucoma will not be successful if the root of the iris is not detached by reason of faulty technic. These are the cases where a second properly performed iridectomy reduces the tension permanently. It also will be unsuccessful when the root of the iris cannot be detached owing to too firm adhesions. These are the cases where, although the iridectomy was performed correctly according to our present technic, the iris tears off anteriorly to the adhesion so that its root remains behind and the iris angle stays obstructed. Finally, iridectomy will be a failure even though the root of the iris is detached and excised when Schlemm's canal is obstructed by organized plastic exudate, thereby losing its patency.

These latter cases are usually met with in patients suffering from chronic inflammatory glaucoma of long duration, especially if they have had one or more acute attacks. Iridectomy is not in order in these cases, but one of the operations which establishes a new channel of drainage, such as the Lagrange operation or the trephining.

Now, there is no doubt in my mind that iridectomy is a safer operation than that of either Lagrange or Elliot, and therefore preferable to either one. Suffice to mention iridocyclitis and late infections, and I believe that with the

exception of the last group mentioned above, where Schlemm's canal is not patent, iridectomy, if we succeed in detaching the root of the iris and excising it, will produce a permanent drainage of the intra-ocular fluid.

As mentioned above, iridectomy, performed according to our present technic, will result in failure in a certain group of cases (where there is firm adhesion between root of iris and cornea) from the iris tearing off at the anterior edge of the adhesion, leaving the root of the iris behind and not establishing a communication between the aqueous and Schlemm's canal, although the latter is patent. This I attribute to the faulty technic of iridectomy as it is performed to-day. The fault lies in the incision and in the manner in which the iridectomy is performed. Theoretically, the incision is to be made 2 mm. behind the limbus, that is to say, exactly at the junction of cornea and sclera; it is never made there but always anteriorly to this point. This can easily be ascertained by entering the anterior chamber with an iris spatula after incision and pushing the spatula backward toward the corneoscleral junction, holding it close to the posterior surface of the cornea. The angle where cornea and sclera meet can easily be felt and will be found quite a distance behind the upper lip of the wound. Under such circumstances the incision will either lie in front of the root of the iris or it will go through the adherent portion of the iris, bisecting it. When excising the iris, either the entire root, or if bisected, its posterior portion—*i. e.*, the one that blocks the iritic angle—will be left behind.

As far as the iridectomy is concerned, the fault in technic can be found partly in the manner in which the iris is grasped with the forceps, and partly in the way it is excised with the scissors. The forceps are introduced at right angles to the wound and the iris grasped. The traction exerted upon the iris will be parallel with the horizontal meridian of the cornea and a considerable distance away from its root; it can have

no effect in helping to detach the adhesion. Later, when the iris is pulled out, the traction is exerted from the pupillary margin toward the adhesion; traction in this direction will have no effect upon the adherent portion of the iris. Finally, when the iris is excised with the scissors, the fold is first cut at the right-hand end of the wound; then with a slight traction it is pulled over into the left-hand end of the wound, where it is excised with the second cut of the scissors. The traction thus exerted will be parallel with the adhesion and therefore will

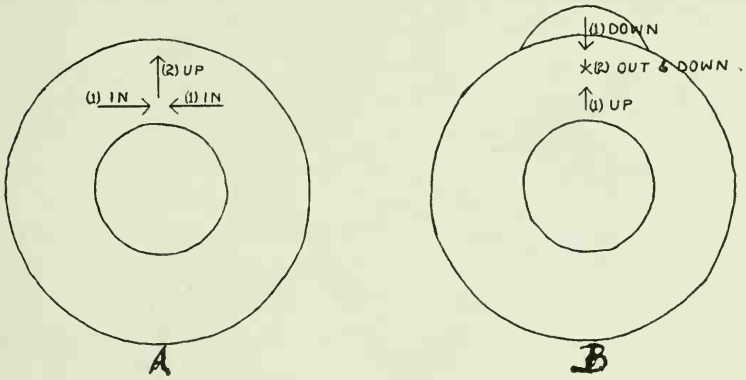

Fig. 1.—Schematic representation of traction in—A, present technic; B, new technic. 1, Shows direction in application of forceps. 2, shows direction of traction in delivery of iris.

tear the iris off along the anterior edge of the adhesion, leaving the root behind and the iritic angle blocked (Fig. 1).

The root of the iris will be removed by this technic only in cases where the adhesions are very weak and loose, or are not affected by connective tissue but by fresh plastic exudate, as in an acute attack of glaucoma.

These faults in technic may be remedied by (1) making the incision with the Graefe knife instead of the keratome; (2) detaching the root of the iris with a spatula before making the iridectomy; (3) grasping the iris with the iris forceps parallel to the vertical meridian of the cornea.

Following these suggestions, an iridectomy on a glaucomatous eye will be performed as follows: The eyeball is fixed in the limbus at either end of the horizontal meridian of the cornea with a double fixation forceps, such as Schweigger's or one similar to it. This will greatly facilitate the section, as it will eliminate the rotation of the eyeball, a complication which is most disturbing. The incision is made above, puncture and counter-puncture being in the sclera, and the section terminating behind the limbus with a conjunctival flap. It is similar to the one made in the Lagrange operation,

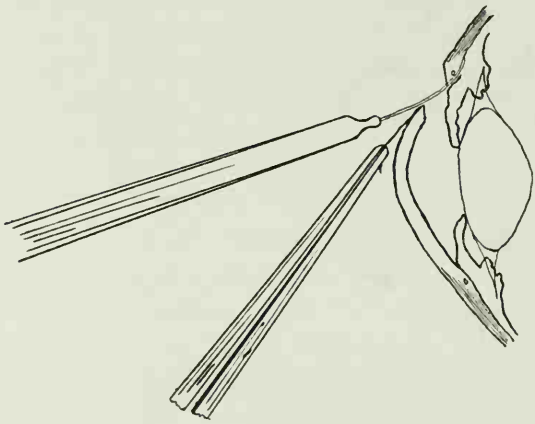

Fig. 2.—Detaching the adherent root of iris.

but not carried quite as obliquely through the sclera, the cutting edge of the knife having been turned forward when the corneoscleral junction (2 mm. behind the limbus) is reached. If the iris prolapses after incision, it should be carefully replaced. The conjunctival flap is now grasped with an anatomic forceps and gently pulled forward, making the wound gape thereby. With an iris spatula, holding it always in close contact with the sclera, the root of the iris is detached throughout the whole extent of the wound and, if one wishes, the spatula can easily be pushed still further forward

between ciliary body and sclera as far as the suprachoroidal space (Fig. 2). The ciliary body is thereby detached and a cyclodialysis from the anterior chamber performed. If one always keeps the spatula in close contact with the sclera, there is no danger of injuring the ciliary body or losing vitreous.

The assistant now takes the anatomic forceps and keeps the wound gaping by means of traction on the conjunctival flap and the surgeon grasps the iris with the iris forceps. This is done by introducing the forceps parallel with the wound,

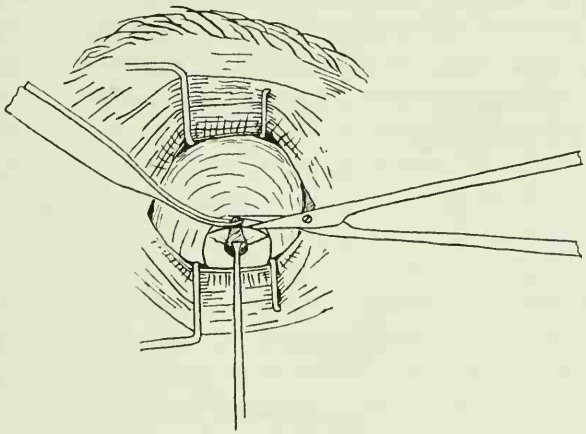

Fig 3.—Excision of iris, showing application of forceps, delivery of iris, and position of scissors.

one blade being placed near the root of the iris, the other one a few millimeters below. The forceps is now closed and the iris drawn out, gentle traction being exerted forward and slightly downward toward the patient's feet, and excised with two sweeps of the scissors. The scissors are held parallel with the wound and placed upon its posterior lip by holding them slightly tilted so that one blade is actually in the anterior chamber (Fig. 3). The pillars of the coloboma are now replaced if necessary, the conjunctival flap smoothed out, and a bandage applied.

Now, the advantages of this technic as I see them are as follows:

1. The incision with the Graefe knife will give a good, large peripheric incision with a conjunctival flap of any desired size. The knife will be less liable to injure or even bisect the adherent root of the iris, and the wound obtained will readily gape, thereby facilitating the subsequent manipulations with the spatula.

2. The detaching of the adherent portion of the iris from the cornea before iridectomy will assure us of opening up the iris angle and reëstablishing communication between the aqueous and Schlemm's canal. It is logical to assume that this manipulation will be successful in all cases, with, perhaps, the exception of those of long-standing chronic glaucoma where the iris is much atrophied and friable. Under these circumstances the spatula probably will not penetrate between the root of the iris and the sclera so that no actual detachment will take place; it will, however, tear the iris and the trabeculæ of the pectinate ligament, thereby opening up the iritic angle and establishing the desired communication between the aqueous and Schlemm's canal similar to the action of an anterior sclerotomy, with the exception that the subsequent excision of the iris will prevent the closure of the opening thus obtained. This is an important point, as it would speak in favor of this method as compared with anterior sclerotomy.

As mentioned above, the spatula may be carried forward between ciliary body and sclera as far as the suprachoroidal space, thereby performing a cyclodialysis and opening up the suprachoroidal space also, giving still another channel for the draining off of the intra-ocular fluid. I mention this with the full knowledge of the fact that pathologic examinations have shown that in cyclodialysis the ciliary body does not remain detached from the sclera but becomes firmly adherent to it again; the beneficial effect of this operation being

attributed to the opening up of Schlemm's canal rather than to the communication between anterior chamber and suprachoroidal space. Here again, then, the fact that the iris is excised would be a point in favor of this operation as compared with cyclodialysis, as no reattachment can occur.

Elliot, speaking about the "new operations for glaucoma," says the following: "It is admitted that the later the case the worse the prognosis, and that this in part, perhaps in large part, depends on the fact that the advance of the iris, owing to its adhesion to the sclerocornea, makes the attainment of a uvea-free fistula more difficult and more hazardous" If this be so, then it would seem to me that detachment of the root of the iris before iridectomy in trephining, as well as Lagrange's operation, would be a great advantage and would give us a permanent fistulous opening in a greater number of cases. The manipulations with the iris spatula can easily be performed through the trephine opening and also through the wound.

3. The technic of the excision of the iris, together with detaching it from the sclera, will secure the opening of the iritic angle by removing the root. To grasp the iris parallel with the vertical meridian of the cornea and draw it out with gentle traction forward and slightly downward will tend to pull the iris away from the sclerocorneal junction and bring its root within the action of the blades of the scissors. This is still further facilitated by holding the scissors slightly tilted. The previous detachment of the adhesion will absolutely eliminate the possibility of tearing off or cutting off the iris along its anterior attachment to the cornea and sclera.

I have so far performed this operation within the past year and a half on 27 eyes, and the results obtained are quite satisfactory. Of course, time is too short and material too limited to draw any conclusions from them. The operation, however, seems logical to me and the result so far encouraging enough to warrant its publication and recommendation to

the medical profession. The technic does not present any special difficulties or any special dangers.

DISCUSSION

Dr. W. H. Wilder, Chicago: I think this technic proposed by Dr. Török offers some very useful points for consideration. Unquestionably in many glaucomas of long standing the difficulty with iridectomy, as he has stated, is that even if it is done fairly well the iris, because of its friability, may be torn away, leaving a little tag still obliterating the filtration angle. In cases which are more recent, in which the iris root is not so firmly adherent to the cornea, the chances of success are better because we are able by iridectomy to get the iris clear up to its root.

The operation of iridectomy, by a sort of dialysis, has always appealed to me ever since I had the privilege of working with Edward Nettleship. He performed an iridectomy, whether with a keratome or a Graefe knife, by making the corneal incision close to the root of the iris. He then drew the iris out, cut it radially up to the root at one end of the wound, and tore it loose at the root up to the other end of the corneal wound, where he cut off the piece. That is an extremely valuable method of iridectomy where the iris is not too friable. In some cases there will be more or less hemorrhage, but in my experience it has given me better results than the old method of making the excision entirely with the scissors.

The suggestion of Dr. Török of combining the principle of cyclodialysis with the iridectomy, or at least separating the root of the iris from the cornea so that the iridectomy could be complete, seems to be a valuable one, and may improve the results in those difficult cases of chronic glaucoma where we know iridectomy does not come up to expectations and fails so lamentably at times.

Dr. George S. Derby, Boston, Mass.: I should just like to ask if Dr. Török intends to pull the insertion of the iris away from the ciliary body in order to bring it into the field where an iridectomy may be performed?

Dr. Ervin Török: Yes.

AN OPERATION FOR BLEPHAROPTOSIS WITH THE FORMATION OF A FOLD IN THE LID

ROBERT G. REESE, M.D.
New York

This procedure is indicated in congenital ptosis due to either defect in development or entire absence of the levator, and in old cases of acquired ptosis which cannot be cured in any other way, whether the lid is devoid of wrinkles or not. It is also effectual in ptosis myopathica.

I have operated by this method in 18 cases of congenital ptosis, and in three cases of inveterate acquired ptosis, and the results have been better than those obtained by any of the numerous methods I have employed.

The operation performed, as here described, corrects the backward pose of the head by permanently elevating the lid and exposing the pupil, thereby restoring the function of the eye. No lagophthalmos is produced during sleep, and the cosmetic effect is materially enhanced by the formation of an extensive fold in the lid.

Operation.—The brow and lids are washed with soap and water, and painted with tincture of iodin, U.S.P. A general anesthetic is seldom necessary, so that the lines of the incisions are injected subcutaneously with a solution of novocain, 2 per cent., with 5 drops of solution of adrenalin 1 : 1000 added to each c.c.

After ten minutes insert a Jäger horn plate beneath the upper lid, and make a curvilinear incision through the skin only, from one extremity of the lid to the other, so that the center of the curve will be 6 mm. from the lid margin, and the extremities of the incision 4 mm. from the lid margin (Fig. 1).

The upper and lower portions of the skin adjacent to the incision are dissected from the subcutaneous tissue 4 mm. above and 2 mm. below (Fig. 1).

An incision is then made beneath the skin and 2 mm. below the lower margin of the curvilinear incision down to the tarsus, and parallel to the lid margin from one extremity of the lid to the other. A second incision is made beneath the upper skin flap and joining the extremities of the first incision, so that the central portion of this crescentic area lying between these two incisions will be 6 mm. vertically (Fig. 2).

The sides of this crescentic area are dissected from the tarsus, leaving 10 mm. of the central area in its normal attachment to the tarsus, thereby forming two lateral flaps (Fig. 3). The skin and subcutaneous tissue above this central portion of the crescentic area are dissected from the un-

Fig. 4.—Double-edged knife—blade, 35 x 4 mm., and 1 mm. fenestra near its point.

derlying tarsus and tarso-orbital fascia, 6 mm. vertically and 15 mm. horizontally, in order to allow the flaps and the 10 mm. attached portion to be drawn up beneath them, so that they will become adherent to the tarso-orbital fascia and convex border of the tarsus (Fig. 3). Enter a double-edged knife (Fig. 4) just above and external to the crest of the eyebrows and push it downward, hugging the tarso-orbital fascia, so that its point emerges at the side of the 10 mm. attached central portion of tissue, at an angle of 25 degrees (Fig. 5).

A suture is passed through the end of the flap, and the ends threaded in the fenestra situated near the point of the double-edged knife (Fig. 5), so that by withdrawing the knife the flap is pulled up and the thread protrudes through the opening above the brow (Fig. 6). An analogous procedure is done

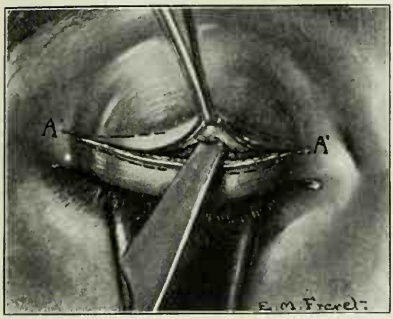

Fig. 1.—A A′, Line of incision through the skin only. Dotted line shows amount of dissection of skin from subcutaneous tissue.

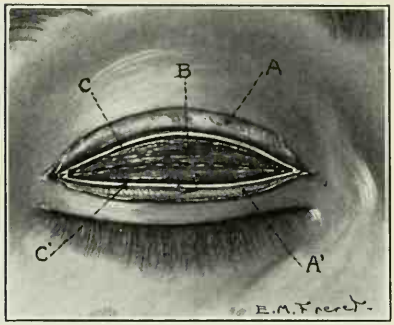

Fig. 2.—A A′, Everted skin. B, Crescentic area composed of subcutaneous cellular tissue and a portion of the orbicularis. Dotted line shows position of primary incision through the skin. C C′, Incisions through the subcutaneous cellular tissue and orbicularis, down to the anterior surface of the tarsus.

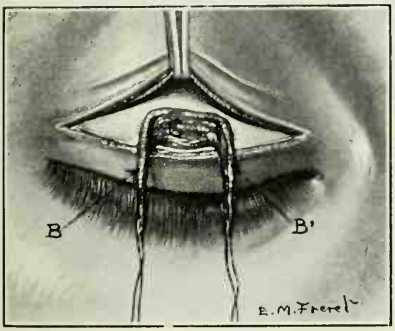

Fig. 3.—A, Forceps holding up the dissected area of skin and subcutaneous tissues from the convex border of the tarsus and tarso-orbital fascia. B B′, The two lateral flaps dissected from the tarsus. Sutures passed through their distal ends. C, 10 mm. of tissue in its normal attachment to the middle of the tarsus.

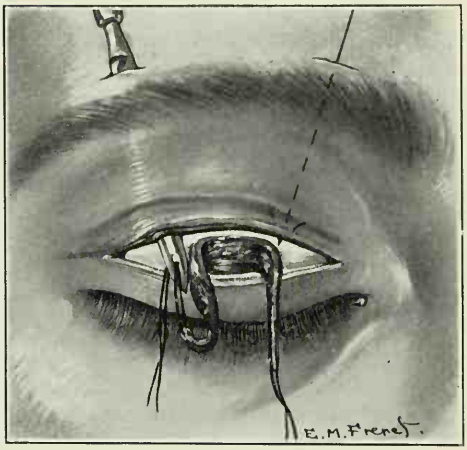

Fig. 5.—Entrance of the double-edged knife, and its emergence at the external side of the 10 mm. attached tissue with the thread from the external flap in the fenestra. The arrow shows the entrance, direction, and emergence of the knife on the internal side.

fig. 3

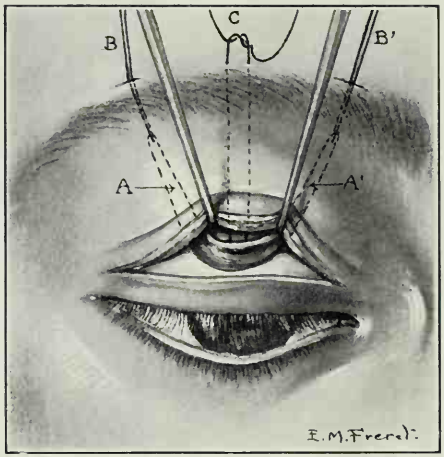

Fig. 4

Fig. 6.—A A′, Flaps lying on the tarso-orbital fascia. B B′, Flap sutures emerging through the openings above the brow. C, Anchor suture, with its loop on anterior face of attached tarsal tissue, and its emergence above the crest of the brow.

Fig. 5

Fig. 7.—A, Entrance of suture through the opening of skin and flap. Excess flap to be excised. B, Tied suture holding the inner flap, approximating the skin. C, Anchor suture tied over rolled gauze. D D′, Adjusted skin incision showing extensive fold.

on the inner side, above the eyebrows, with the same knife, avoiding the supra-orbital nerve (Fig. 6). One needle of a double-armed, twisted silk thread is entered 2 mm. below the upper central border of the 10 mm. portion of attached tarsal tissue, as an anchor suture (Fig. 6), and passed upward beneath the subcutaneous tissue, emerging above the crest of the eyebrows; the other needle is entered the same way, 3 mm. horizontally from the entrance of the first needle, and carried upward in the same manner, forming a loop on the anterior surface of the tarsal attached subcutaneous tissue (Fig. 6). The thread is tied over a piece of plain rolled gauze, and drawn up sufficiently to produce a marked lagophthalmos (Fig. 7).

The lateral flaps are drawn through the openings above the brow with the threads, so that they lie smoothly on the tarso-orbital fascia and without producing any traction on the lid (Fig. 7). A suture is then passed from above downward through the upper edge of the skin opening, protruding flap, and lower edge of the skin opening, and the excess of flap excised (Fig. 7). The suture is tied after the flap is allowed to recede below the skin surface, in order that it may become adherent to the subcutaneous surface, and is not interposed between the margins of the incision, thus avoiding a puckered scar. The curvilinear opening in the lid is adjusted, and no sutures are used (Fig. 7). Borated vaselin is applied abundantly for protection and to prevent desiccation of the cornea. Rubber tissue and plain gauze are used and a bandage is applied. It is advisable to inspect the eye after twenty-four hours and use borated vaselin as a protection at each daily dressing.

There should be considerable lagophthalmos after the operation, which will disappear in a few days.

In the after-treatment it is important that the sutures are not removed too early, otherwise the elevation of the lid may not be sufficient; and, moreover, the union between the

tarso-orbital fascia and the flaps would not be firm enough; consequently, the sutures are removed after seven days.

The bandage may be left off after four days, but the sutures should then be covered with adhesive strips.

The contraction of the frontalis pulls on the submerged flaps, raising the tarso-orbital fascia and tarsus, simulating the action of the levator, and the lid does not become everted in its elevation, but hugs the globe normally. The displacement of a portion of the orbicularis does not impair its normal function of closing the lid, so that lagophthalmos during sleep is prevented, and the reflex palpebral closure is preserved.

If the skin of the lid is redundant, which is not usually the case, a segment may be removed, although an excess of skin improves the cosmetic result rather than otherwise.

In eight of my first operations dermic flaps were used, and in each instance a sebaceous cyst formed along their course, notwithstanding the epithelial surface was scarified and scraped, a procedure advocated and practised by me fifteen years ago when the Tansley-Hunt was my operation of choice.

I am adding the histories of four cases, three of which were operated on by other operators:

CASE 1 (Fig. 8).—Operated on by Dr. C. E. O'Connor, of Kingston, Ontario, who kindly supplied me with the photographs and the following history:

Male, aged thirty-three years. Congenital ptosis of both eyes. Had Gillet de Grandmont operation on both eyes ten years ago, and the result was as shown in Fig. 8, A.

August, 1921, Reese ptosis operation on both eyes. B, Two months after operation.

CASE 2 (Fig. 9).—Operated on by Dr. Ben Witt Key, of New York, to whom I am indebted for the photographs and the following history:

Male, aged thirty-five years. Monocular congenital ptosis and paralysis of the right superior rectus. Reese ptosis operation December, 1922.

A B

Fig. 8.—A B





A B C

Fig. 9.—A B C (Ptosis operation six weeks after Reese resection, superior rectus, O.D.).

A B

Fig. 10.—A (June 28, 1922). B (July 14, 1922).

A B

Fig. 11.—A B.

A, Before operation.
B, After operation. Frontalis in repose.
C, Frontalis in action.

CASE 3 (Fig. 10).—Operated on by Dr. Ben Witt Key, who kindly supplied the photographs and the following history:
Male, aged thirty-six years. Bilateral congenital ptosis.
A, Before operation.
B, Three weeks after Reese's ptosis operation.

CASE 4 (Fig. 11).—Female, aged sixteen years. This was the first case I operated on. Bilateral congenital ptosis and paralysis of the inferior rectus, with convergent strabismus of the right eye. V.R.E., 20/200 unimproved; amblyopia exanopsia. V.L.E., 20/20. First operation December, 1916. Dermic flaps were used. Sebaceous cysts formed along these submerged flaps in the course of six months, and were dissected out.

January, 1917, Reese resection of the external rectus and tenotomy of the internal rectus were performed.

December, 1918, ptosis operation, as here described, performed on both eyes.

A, After the first operation, as no photograph was taken before the operation.
B, Five years after the second operation.

DISCUSSION

DR. CARL FISHER, Los Angeles, Cal.: I think we are in need of an improved operation for blepharoptosis, and it seems to me that Dr. Reese's operation meets certain objections which we have found to the older methods. The Motais operation, although far the best cosmetically, carries the risk of muscle imbalance. The Tansley-Hunt type is bad cosmetically, and those of the Hess type require extensive undermining of the skin, which means that extraordinary efforts at asepsis will sometimes fail and the operation have to be done over under more difficult conditions.

The cosmetic effect is quite as important as the correction of the ptosis, in the patient's mind, and this is largely dependent on the position of the fold of the lid: it must be close to the ciliary edge. I remember a curious series of three sisters, all having marked epicanthus and blepharoptosis, giving them an Oriental appearance although they were Scandinavians; they attributed the deformity to the fact that their mother had lived in Japan previous to

their birth. The Hess operation corrected the ptosis nicely, but they were not well pleased with the result because the lid-folds were a little too far from the border.

Dr. Reese's operation requires very little undermining, which I think is a good point.

DR. W. B. LANCASTER, Boston, Mass.: We can divide cases of ptosis, from an operative point of view, into three classes. In one class we have a levator which has some power left; that is the commonest type. There are a great many such cases which are rather disfiguring, but not incapacitating; and usually they are not operated upon. Very much improvement can be produced in these by what amounts to an advancement of the levator, and that is the excision of a good part of the tarsus. No visible scar is left if the excision is done through the conjunctiva. Dr. Reese's operation is not so well suited to this group.

In another group of cases we have no power in the levator, but we do have in the superior rectus. Heretofore the most perfect cosmetic results in these cases have been obtained by utilizing the superior rectus according to the method of Motais, or some similar procedure.

In the third group we have no power in either the levator or the superior rectus, and must depend upon the frontalis, as Dr. Reese would do even in the first two groups. Then comes the question of utilizing the frontalis. About six years ago I devised an operation for utilizing the frontalis by a strip of the fascia lata transplanted over the site. Since then several other operators, without knowing about my work, have utilized the fascia lata. I should like to recommend that method once more. It is easy to perform. The fascia lata is very much thicker than the tissue which Dr. Reese utilizes. A strip of suitable size is simply attached to the tarsus below by a mattress suture, run up under the skin and the other end attached to the frontalis above. It is unyielding and firm and you can count on its holding. If you should get an overeffect, you can then do a tenotomy.

This case [showing pictures] was done about two months ago. The first picture shows the patient facing a bright light, so the eyes are not wide open. The second picture shows the patient trying to open his eyes as wide as he can; and the third shows the eyes closed. This patient had total paralysis of the superior rectus, so that when the lid was raised by the operation for ptosis, and the

sclera was exposed above the eye, the cosmetic effect was bad. I warned him that this would obtain and that he must consent to two operations, one for the lid and one for the eyeball. We then did a transplant of one-half of the external rectus and one-half of the internal rectus to the superior rectus, so that one eye matches the other. This patient said that before the operation he had slept all his life with this eye open, and that he never had any injury to the cornea from the exposure. The eye is blind. This picture showing the eye closed indicates that the operated eye does not close as well as the other, but he claims that was the case before the operation. For details of technic see Trans. Amer. Acad. Ophth. and Oto-Lar., 1919, page 235.

DR. BEN WITT KEY, New York City: I have performed this operation six times on five patients, one of these being a double congenital ptosis. All but one case had limited motility upward, and one of these had no motility upward. I have used general anesthesia in these cases because the swelling and redundancy due to sufficient local anesthesia interferes with the extreme elevation of the lid, places excessive tension on the muscle flaps, and masks the normal relation of the parts.

To me the essential points in the procedure are: First, the primary incision should be made at a distance from the lid margin, varying from 3 to 6 mm., depending on the location of the lid-fold in the fellow eye, and should be carried temporalward to a point on a line running horizontally through the external canthus—this in order to complete the fold of the lid outward and to prevent puckering of the skin. Second, suspension of the lid is by a swinging action adjusted by each muscle flap, thus replacing the levator as to position and to some extent in action. An anchor suture is helpful in supporting the muscle flaps and in making perfect the contour of the lid. Third, in some cases where the brow is large and the skin redundant, it is important to remove a strip of skin to prevent overlapping and to allow more room for elevation. Sutures are rarely necessary to close the skin-flaps, because the flaps fall in natural position for healing. Fourth, I have found it important in making the channels under the brow, through which the muscle flaps are drawn, to carry the knife deeply and from side to side, making them broad but not continuous into one channel either above or below. This is done for the double purpose of preventing the crowding and increased tension on the muscle flaps, and

also to add whatever benefit is secured by a readjustment of the lid-folds in the healing process, as is obtained after the Hess operation.

The method is suitable in any form of ptosis, but especially adapted where the superior rectus is affected. The procedure is simple and rapidly performed. No scar remains. A lid-fold can be secured similar to that of the fellow eye. Elevation of the lid is definitely determined and closure of the lids is complete.

DR. GEORGE S. DERBY, Boston, Mass.: It seems to me that Dr. Lancaster has pointed out one of the difficulties of Dr. Reese's modification of the Motais operation. The little loops which you make to carry the orbicularis through are not so easy to pull through at times, and it was my misfortune in one case, perhaps through clumsy handling, to pull off one side of the muscle, which leaves one in rather a difficult situation. I think Dr. Lancaster's suggestion that we might use the fascia lata instead of the muscle is very good indeed.

DR. WILLIAM ZENTMAYER, Philadelphia: I would like to speak of a ptosis operation introduced by a general surgeon in Philadelphia, Dr. John B. Roberts, in which the procedure is reversed. He brings down two flaps from the frontalis muscle. In a case of congenital ptosis of very marked degree in which other operators had failed, he secured a very good result. The operation is extensive.

DUCT CONSERVATION IN LACRIMAL ABSCESS

A. E. EWING, M.D.
St. Louis, Mo.

The crudeness of our knowledge with regard to the anatomy of the lacrimal duct is doubtless the reason why the probe has acquired its unpleasant reputation as an instrument of torture both with patients and physicians in the treatment of lacrimal abscess and other lacrimal obstructions. Because of the difficulty in dissecting the duct it is seldom seen and studied in its natural state during our student period. After leaving the anatomic room few of us return later for closer investigation.

Our present means of decalcification has enabled us to clear away the haze in the management of this class of cases so far as concerns the anatomy, as is demonstrated in the accompanying illustrations, natural in size, from photographs of decalcified specimens.

There are two cross-sections of the duct, Figs. 1 and 2, which show the relation of the soft tissue to the bony wall; two anteroposterior sections seen from the nasal side which show the size of the lacrimal sac and the entrance of the canaliculi into the sac. In one of these, Fig. 3, the valve of Hasner is a membrane surrounding a large round opening into the nasal fossa at the lower margin of the inferior turbinate articulation. In the other, Fig. 4, this valve is anatomically perfect, as is demonstrated by the flexible probe which lies in the duct and passes through the valve from the articulation of the inferior turbinate to the normal depression in the outer nasal wall, which is the exit of the duct. Also in this figure the entrance of the canaliculi into the sac is shown by a probe which enters through the upper canaliculus. There are five lateral sections which show the duct from the front. One of these, to the left in Fig. 5, has a large round opening into the nasal fossa. The others have more or less perfect valves of various lengths. The one containing the probe illustrates the valve held away from the nasal wall by the probe, Fig. 8. In Fig. 5, left eye, the size and course of the canaliculi from the puncta to the sac are clearly depicted.

As the illustrations represent the actual size and length of the lacrimal passage they are guides in the selection of probes, the majority of which are too long and too straight and those ordinarily employed are too large. The large probe injures the tissues of the passage from the punctum to the valve of Hasner. The probe that is straight or in line with the anteroposterior plane of the duct will cause pain by pressing on the outer wall of the nose. It may even crush through this wall into the antrum. The long probe is a cruel instrument be-

cause it punches into the floor of the nose and causes excruciating pain. Probes should be so constructed that their length from the finger plate will not permit them to touch the floor of the nose. When in use, the tips should be curved toward the median line, sometimes sharply, as indicated in Fig. 9, C2, taken from two cases in each of which this curve was necessary in order to enter the nasal fossa.

DESCRIPTION OF THE ILLUSTRATIONS OF THE LACRIMAL PASSAGES

Fig. 1.—Horizontal sections through the lacrimal sac and duct. In the upper right section one looks upward into the sac. In the other sections one is looking downward into the sac and duct. In the two upper sections the entrance of the canaliculi into the sac is shown. The sections illustrate the relation of the mucous and submucous or soft tissues of the duct to the bony wall, the white ring being the soft tissue within the bony wall.

Fig. 2.—Horizontal sections through the lacrimal sac, the duct, and the valve of Hasner (V. H.). They illustrate the relation of the soft tissue to the bony wall, the outer dotted ring being the bony wall.

Fig. 3.—A lateral view of the right lacrimal sac and duct from the nasal side. The anterior boundary of the sac is indicated by the dotted line. In the upper left portion of the sac the entrance of the canaliculi is shown by the short, nearly vertical dark line. The exit of the duct into the nasal fossa is a large round opening in the mucous membrane—an imperfect valve of Hasner (V. H.). Just below this to the left is an opening into the antrum, and to the right a cross-section of the lower turbinate. This was a large duct with a thin mucous and submucous lining.

Fig. 4.—A lateral view of the left lacrimal sac and duct seen from the nasal side. It illustrates the lacrimal sac, the entrance of the canaliculi into the sac (indicated by a probe passed through the upper canaliculus), the soft tissues of the duct, and an anatomically perfect valve of Hasner. The valve is shown by the flexible probe that lies in the duct and passes through the valve from the articulation of the inferior turbinate to the normal depression in the outer nasal wall, which is the exit of the duct.

Fig. 5.—A front view of two lacrimal sacs and ducts. The right duct has a large round exit into the nasal fossa in a fold of mucous membrane. The valve in the left duct was normal but was cut away in making the section. The vascularity of the soft tissues within the duct is here illustrated. The size and direction of the left canaliculi and their entrances into the sac are very well depicted.

Fig. 6.—A front view of the lacrimal sac and duct. The tissues in front of the canaliculi were cut away in order that their direction might be outlined. The soft tissues within the duct and the possibility of a crooked duct are well indicated. The valve of Hasner extends far down on the nasal wall.

Fig. 7.—A front view of the lacrimal sac and duct. It shows a straight duct which is well supplied with mucous and submucous tissue.

Fig. 8.—A front view of the lacrimal sac and duct. A flexible bulb probe lies in the sac and duct. The nasal end of the probe holds the valve of Hasner (V. H.) away from the nasal wall. It should be noted that the nasal end of this probe curves to the median line. Were the probe straight, it would enter the antrum, yet this is a reasonably straight duct.

Fig. 1

Fig. 2

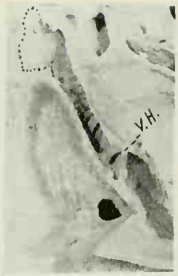

Fig. 3

Fig. 4

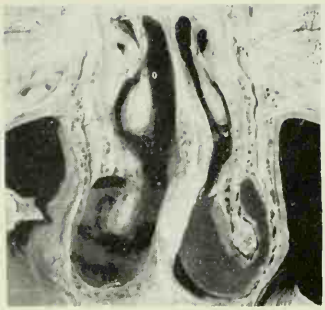

Fig. 5

Fig. 6

Fig 7

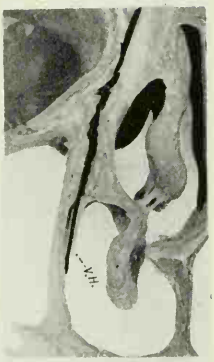

Fig. 8

The lacrimal passages, eight illustrations, natural size.
Figs. 1 and 2 are cross-sections; 3 and 4 are anteroposterior sections; 5, 6, 7, and 8 are lateral sections.

A glance at the five illustrations seen from the front will demonstrate the correctness of this observation. Even in the very straight duct of Fig. 7, a straight probe would injure the nasal wall after passing the articulation of the turbinate if it

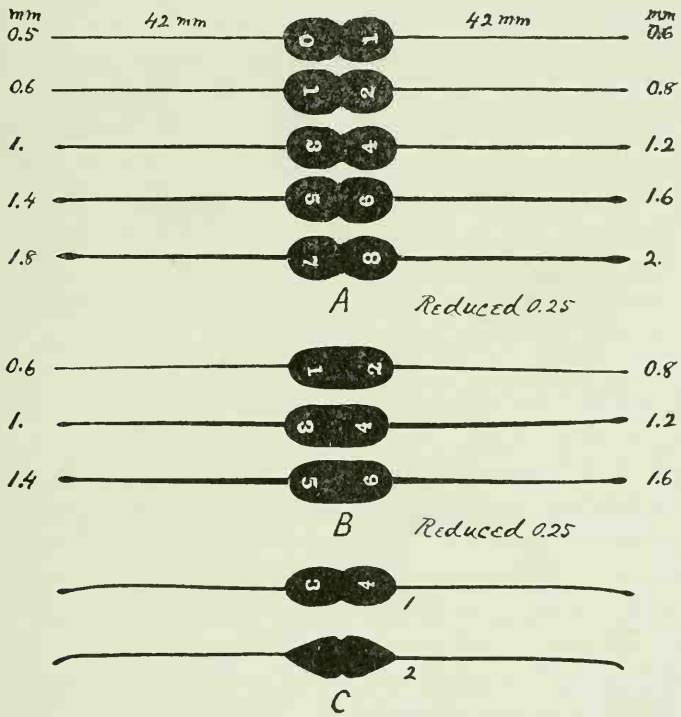

Fig. 9.—*A*, Silver bulbous probes tipped with solder. *B*, Whalebone flexible probes with bulbous tips. *C*, 1, The nasalward curves usually required in order safely to pass through the majority of lacrimal ducts. 2, Probes showing the nasalward curves that were necessary in two cases in order to open obstinate strictures at the lower end of the ducts.

were pushed to the floor of the nose; in the crooked duct of Fig. 6, it would pass directly into the antrum. This is further demonstrated by the curve of the flexible probe in the duct of Fig. 8. Usually a slight curve nasalward in the metal probes is all that is necessary, as shown in Fig. 9, C1. The flexible

probe will follow the natural channel. As seen from the side the probe should be straight instead of bent forward, which is the usual custom. A probe bent forward will become entangled at the entrance of the sac into the bony duct or at the articulation of the lower turbinate and maxillary bones.

The sizes of probes to be used in each case should be governed by their ease of passage through the canaliculus. Usually a probe which is 1 mm. or 1.2 mm. in diameter will pass without force. On this basis, probes should be constructed with a gradation in sizes of one-fifth of a millimeter in diameter using the 1 mm. size as the standard. The accompanying probes, Fig. 9, A, are constructed with this gradation, the 0 being any size less than 0.5 mm., as these sizes readily pass the puncta and canaliculi. They can be constructed to any size desired by using for the shaft hard drawn silver, gold, or steel (piano) wire, and for bulb probes by tipping the points with solder. In order to protect against their being pushed into the floor of the nose, their length from the finger plate should not exceed 45 mm. In several ducts that have been measured the distance from the puncta to the floor of the nose has varied from 42 to 45 mm., the majority of instances showing the shorter length. For this reason I have assumed 42 mm. as a harmless length for the probes, and yet a length that will extend below an anatomically perfect valve of Hasner when the probe has been entered from either punctum.

The bulb probes suggested by Travers, 1824, and in 1867 adopted by Dr. Williams, are superior to those of Bowman because they more readily locate strictures and they injure the lacrimal passage only in the region of the strictures.

Other valuable probes are those made from whalebone, either of the Bowman or the Travers type, as they may be obtained in any size, and if too stiff they are easily softened by boiling. In the bulbous form they are especially useful for diagnosis, little or no pain being caused by their introduction. Frequently they are curative without resorting to metal

probes. Their length may be gaged by substituting for the metal finger plate a finger hold made from the rubber tire mending substance known as "tire putty," or fixing a finger plate to the probe by means of the putty. This is easily applied and after it is fixed it resists both alcohol and boiling. Such probes are shown in Fig. 9, B.

Previous to dilating the punctum or dividing it for the entrance of a probe there should always be thorough anesthesia. This may be accomplished in ten or fifteen minutes with cocain or holocain or both combined. The upper canaliculus should always be the choice, as it is shorter and the arc of the curve for entering the bony duct is only about half the arc when the lower canaliculus is chosen. Also the lower canaliculus is the chief drainage canal, and should be carefully protected from injury. If the incision is resorted to, it should extend along the canaliculus for a length not greater than 3 mm. Such an incision is harmless as it does not interfere with the valvular function of the lacrimal sac. It is best performed with a curved Weber knife, the edge of the knife being directed backward in order to conceal the incision beneath the lid margin.

Following the dilatation or the incision, the sac and the duct should be anesthetized by means of cocain, 5 per cent., injected with a syringe. For this injection I prefer the Shahan syringe because it is so readily sensitive to pressure. At the same time that the duct is anesthetized the nasal region of the affected side should be anesthetized with a solution of 5 per cent. cocain in an adrenalin solution of 1–4000 by means of a swab, in order to anesthetize the nasal end of the duct and also shrink the inferior turbinate so that the end of the probe may be seen on the outer wall of the nose after it has been successfully passed.

In its manipulation the probe should be introduced horizontally in the manner usually described, until the nasal wall is reached, the finger end should then be raised to a vertical

position and the probe end should be guided into the duct by pressing the forefinger over the sac. Usually it is best to massage strictures. This is easily accomplished with a bulb probe. The location and the number of strictures should be noted in the record for future reference and comparison.

The nasal tip of the probe should always be observed with a head-mirror as a guard against provoking a false passage. Care should be exercised not to do any syringing immediately after the probe has been passed, as the fluid might extravasate into the soft tissues of the orbit and cause an unfortunate swelling. It is best to wait for the syringing until the next day or sometimes two days. However, the duct and the sac should be kept clean by means of a mild collyrium and pressure, and, if the canaliculus has been incised, the incision should be reopened daily with a small probe for a week or ten days until epithelium has covered the edges of the wound.

Syringing should be resorted to when pus or mucus is present. For this purpose the solutions that give greatest relief are mercurochrome 2 per cent., zinc sulphate 0.5 solution, and the silver salts. The latter should not be used frequently for fear of argyrosis. Anesthesia should always precede the syringe.

The employment of probes is often discouraging because they frequently do not accomplish an immediate result. As a rule, however, there is an immediate improvement, especially when it is taken into account that these ducts are chronically poisoned. By eliminating the poison the swelling along the duct will subside and new epithelium will partially or completely cover the injury of the probe in the structure. If partially, a second probing should be resorted to in six or eight weeks, not earlier than this, as time between probings should be given for chronic swelling to subside and for new epithelium to be established. As is shown by the size of the puncta, any small opening that can be obtained will establish drainage. By careful persistent treatment this may be

accomplished in any case except displacement through injury or where there is malignancy.

For my anatomic material I am indebted to Dr. Robert J. Terry, Professor of Anatomy at Washington University, for two of the specimens, and for the remainder to Dr. Greenfield Sluder, Clinical Professor of Laryngology and Rhinology in Washington University, who has always made a point of having a large decalcified supply on hand for the use of his students and assistants. For selecting the material I wish to acknowledge the assistance of Dr. W. B. Hoover and Dr. M. F. Weymann, and also the aid of the latter in sectioning and mounting the specimens.

DISCUSSION

DR. HIRAM WOODS, Baltimore, Md.: I want to endorse what Dr. Ewing said about the extent of territory we sometimes go through in the use of the probe; and I wonder if we do not often invade that territory unnecessarily. A good many years ago the late Dr. S. D. Risley, to whom we owe so much, said to me, "Do not disturb the punctum if you can help it, its suction is very important." I have noticed frequently in epiphora that it is not always necessary to go down into the duct at all. I have again and again found that when I introduced a No. 1 Theobald probe into the sac, through the punctum and canaliculus, it would here and there strike some kind of obstruction. I do not know what produced the adhesions or narrowings, but if you push the small probe through them, and thus open the canaliculus, many cases of epiphora need no further treatment.

DR. ALLEN GREENWOOD, Boston, Mass.: I wonder if I am voicing the opinion of ophthalmologists today when I say that we are not using probes as we used to? I certainly am not.

It is not seemly for me to offer suggestions to a man of Dr. Ewing's standing, but "Duct Conservation in Lacrimal Abscess" to me means absolutely leaving the duct alone until the abscess is cured. Then the duct is not often disturbed except in cases of incurable epiphora, and in epiphora the majority of cases can be cured by medicinal means, possibly by the use of mercurochrome or sulphate of zinc with massage of the sac. Most of my cases of epiphora

today are leaving my care after such treatment without probing. In fact, if a patient comes to me with lacrimal abscess it is cured as far as possible and nothing is done toward probing the duct. I do use a probe occasionally, but do not begin to use probes as I did twenty-five years ago. I am sure I probe 75 per cent. less than I did in the early days. In the presence of lacrimal abscess if you cannot cure the sac by proper syringing, drainage, or what not, exenteration of the sac seems to me the proper procedure. If, however, you have a case of simple epiphora which you cannot cure by simpler means, then, of course, probing is in order.

DR. ARTHUR J. BEDELL, Albany, N. Y.: Many of these cases of epiphora have a watery eye mainly because of a nasal defect which is passed over. That nasal defect may not be gross: it may consist of nothing but a deviated septum with contact, or it may be an edema of the mucous membrane.

I also recall to your minds a drug which I still believe is very efficient, that is ethylhydrocuprein. It is extremely valuable in connection with lacrimal sac abscess.

DR. J. W. CHARLES, St. Louis, Mo.: Following Dr. Greenwood's ideas on conservatism in the handling of these cases, may I suggest that it is possible in selected cases to teach a member of the family to irrigate the sac at home? It sounds rather bold, but I have recently taught a father to treat his eight-year-old child at home because daily visits were out of the question. This child now comes once a week, and always I can express mercurochrome from the sac, showing that the father is doing efficient work.

DR. A. E. EWING (closing): I have had no experience with exenteration. I have seen it done a number of times, usually with final results which were unsatisfactory.

Nasal defects are always corrected. All patients are sent to nasal men before I do anything when there are indications of nasal complications. As to the syringe, no one uses a syringe more than I do, and I am free to say that a number of cases get well by syringing alone. I remember a case with a fistula a half-inch long, and with simple syringing with twenty per cent. argyrol once a day for two weeks it was cured. After the second or third syringing the fistula closed and at the end of a week the argyrol was passing through the duct and the man entirely recovered. When such cases do not recover from the syringing, the pus can be controlled by a judicious employment of the probe.

A REPORT OF THE CHANGES FOUND IN THE EYES OF RABBITS FOLLOWING THE INJECTION OF LIVING TUBERCLE BACILLI INTO THE COMMON CAROTID ARTERY

WILLIAM C. FINNOFF, M.D.
Denver, Colorado

Friedrich and Nösske[1] were evidently the first investigators to discover tuberculosis occurring in the eyes of animals which had been inoculated with tubercle bacilli. A report of their work was published in 1899. They studied the changes that occurred in the bodies of animals following the introduction of living bacilli of high virulence into the arterial circulation. Rabbits were used and the material was injected into the left ventricle of the heart; tuberculosis of the iris and other organs of the body developed. Their attention was centered on general tuberculosis and not on the ocular changes. They used the eye only as an index to the degree of infection and noted that the presence of iritis indicated a severe generalized disease.

Stock,[2] in 1903, was the first person to describe in detail the symptoms and pathology of experimental tuberculosis of the eye in animals. In the course of his experiments to determine the etiology of sympathetic ophthalmia and endogenous uveitis, he injected tubercle bacilli into the auricular veins of rabbits and found that, in a number of animals, a characteristic iritis and choroiditis occurred. In his series the first manifestations were observed between thirteen and fifteen days after the inoculation. In some animals the lesions healed in two or three months and left scars in the iris and choroid. His experiments proved conclusively that some

types of uveitis are due to tuberculosis. Since Stock's work was published, other investigators have studied this subject.

In a paper read before this Society at its last meeting I described a technic for producing experimental tuberculosis, and in the present essay the results which were obtained after following this method are described.

Emulsions consisting of clumps of living tubercle bacilli were injected into the common carotid artery of rabbits, and lesions in the eyes developed in all of the animals which were inoculated. All types of bovine and human bacilli were used, and the quantity injected was varied. The lesions naturally occurred sooner and with greater severity in the rabbits which were infected with large doses of virulent organisms. When avirulent bacilli were used, the incubation period was longer, and the ocular disease was less severe. Bovine bacilli are more pathogenic for rabbits than human bacilli, and they produce a more violent form of ocular tuberculosis. The quantity of bacilli (in the emulsions) which was used in the experiments varied from 0.2 to 10 mg. Ocular lesions occurred on the side injected, without exception, in the 46 animals which were used in this series. Only two of the rabbits showed evidence of disturbance of the brain. The majority of them developed pulmonary, hepatic, and a more or less generalized tuberculosis. They usually died before the eye condition had run its full course. Out of the whole series, three animals recovered and showed healed lesions in the eye. This contrasts strikingly with the results which we have obtained after the injection of dead bacilli. In the latter experiments the animals usually lived, and the ocular disease ran its full course. A paper covering this phase of the investigation will be read in the near future.

In this series in which living bacilli were used the average incubation period of ocular tuberculosis was a little over six days. This is a much shorter period than was reported by Stock in his series of experiments. The closer proximity of

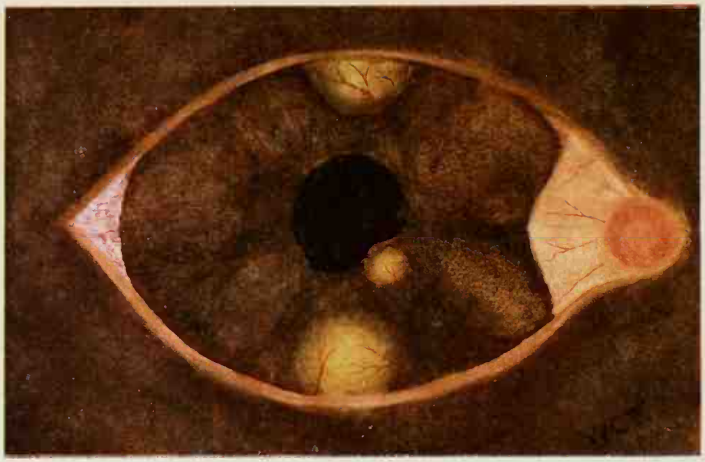

SHOWING RIDGED IRITIS AND CASEOUS TUBERCLES

PLATE I

RABBIT'S FUNDUS, SHOWING EARLY TUBERCLES OF CHOROID

PLATE II

the carotid artery to the eye and the use of a clumped emulsion account for this difference. Out of the 46 animals that were used, the incubation period was as follows: First twenty-four hours, 3 animals; second day, 4; third day, 1; fourth day, 12; fifth day, 2; sixth day, 4; seventh day, 7; eighth day, 4; ninth and tenth days, none; eleventh day, 7; twelfth day, 1; thirteenth day, none; fourteenth day, 1.

The ocular changes are described in the order of their occurrence. In the majority of animals the first change was a contraction of the pupil in the eye corresponding to the side which had been injected. It was frequently seen several days before the appearance of other manifestations. Contraction of the pupil occurs after other irritating substances have been injected into the carotid artery, and the essayist is inclined to believe that this is the result of either mechanical or chemical irritation and is not specific to tuberculosis.

The first striking changes were usually seen in the iris. They varied with the severity of the attack. In the more acute form, hemorrhages occurred into the iris and anterior chamber, and a turbid aqueous was occasionally seen on the day following the inoculation. This phenomenon has also been observed after the introduction of other irritating substances into the arterial circulation and was probably the reaction to an irritant and not specific.

As a rule, characteristic symptoms of tuberculosis were not seen until after the fourth day, when the iris became irregularly thickened in the form of pronounced ridges, which were triangular in shape, with their base directed toward the ciliary portion of the iris and the apex toward the pupil. To this form, which occurred in most cases, I have given the name of ridged iritis (Plate I). In the severe cases, very fine blood-vessels appeared on the surface of the ridges. Serous exudates were also seen on the lens capsule at the pupillary border of the iris, in the region of the ridges. In the less severe cases an avascular ridged iritis was the only change that occurred

in this portion of the eye. It was seen in the three animals which recovered, and the terminal result was a uniform atrophy of the iris stroma. In the remainder of the animals the condition was progressive, and a few days after the onset of ridged iritis, grayish-yellow, round and oval areas were seen pushing through the iris stroma. They were usually located in the base of ridges at the upper and lower pole of the iris. Occasionally, one developed near the pupil. The nodules increased in size rapidly and finally pushed through the iris stroma and protruded into the anterior chamber. New formed blood-vessels ran over the surface of the majority of the nodules (Plate I). In some cases these masses filled the angle of the anterior chamber and were associated with opacification of the adjacent cornea. Microscopically, the nodules were found to be caseated tubercles in the iris (Fig. 1). In most of the animals the nodules gradually increased in size and remained vascular. In some of the milder cases they developed to a certain point, and with the exception of the disappearance of blood-vessels on the surface of the mass, they remained stationary during the remainder of the animal's life. All of the animals in which caseous tubercles in the iris occurred died of generalized tuberculosis or other complications before healing had taken place, and no further changes were seen in the iris.

In the fulminating cases a general stippled haziness of the cornea appeared a few days after the onset of the ridged iritis. This progressed rapidly, and in two or three days the whole cornea became white and resembled coagulated albumin (Figs. 2 and 5). A dense network of blood-vessels soon appeared in the whole circumference of the cornea at the limbus. They continued to invade the substantia propria from the periphery toward the center, and in about ten days' time the whole cornea became vascular. The vascularity of the cornea resembled the so-called salmon patch of human interstitial keratitis (Fig. 3). Sections of the eye, in these cases,

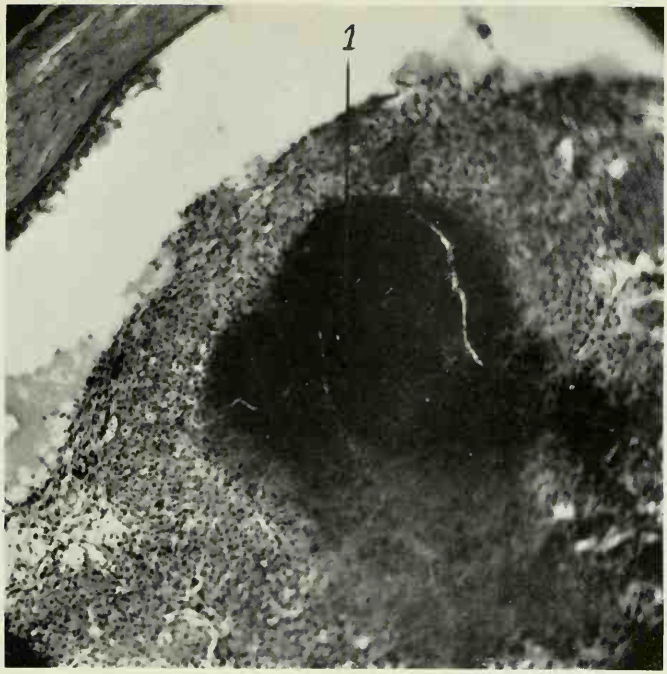

Fig. 1.—1, Area of caseation in the iris.

Fig. 2.—Opacification of the cornea with a ring of newly formed blood-vessels at the limbus. Early conjunctivitis with a small quantity of secretion on the margin of the lower lid

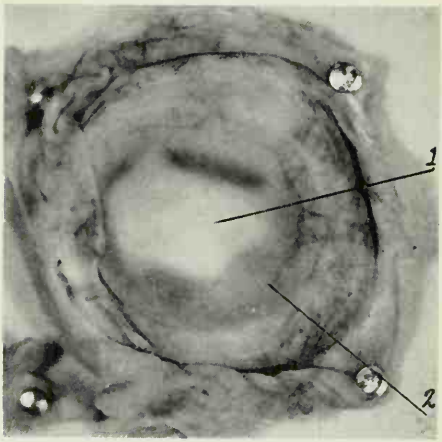

Fig. 3.—Enucleated eye. 1, Center of opaque cornea. 2, Outer darker area due to dense infiltration of substantia propria with fine blood-vessels.

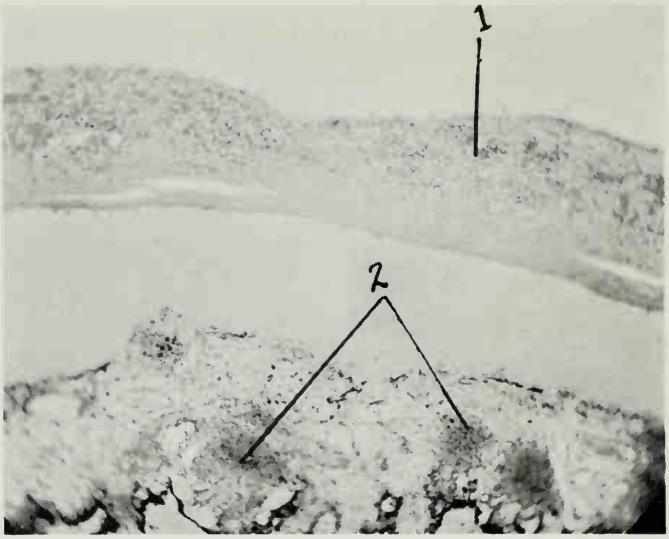

Fig. 4.—Loss of corneal substance due to necrosis of anterior layers in its center. 1, New-formed blood-vessels and cellular infiltration in substantia propria of cornea. 2, Beginning tubercles in iris.

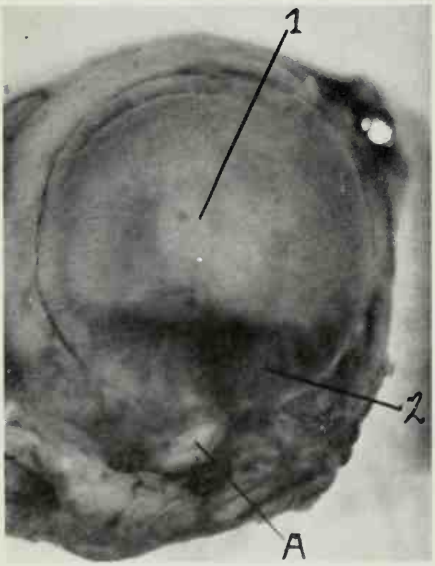

Fig. 5.—A, Ulcer of bulbar conjunctiva. 1, Opacity in corneal center. 2, New-formed blood-vessels in cornea.

Fig. 6.—Characteristic conjunctival secretion. Mild case.

show necrosis of the center of the cornea with new formed blood-vessels, leukocytes, and fibroblasts in the substantia propria toward the periphery (Fig. 4). This type of corneal involvement is not confined to tuberculosis. It occurs after the injection of other substances which alter the nutrition of the cornea. Corneal changes simulating human corneal tuberculosis did not occur in any of the animals which had been inoculated with living tubercle bacilli. However, changes of this nature have been observed in animals in which dead bacilli were used. The findings in these cases will be described in a subsequent paper.

Conjunctivitis occurred in all of the animals that had corneal tuberculosis. It was usually a later manifestation than the lesions which have just been described. In the severe cases it began at the time that the corneal opacities appeared. In the milder cases it did not appear until after the fourteenth day. In the beginning the conjunctiva was severely congested and thickened, and a small quantity of secretion was seen. Red and yellow nodules then appeared in the conjunctiva. In some of the animals these nodules resembled phlyctenules. In several instances the elevations broke down and formed small irregular ulcers. In two animals ulcers of the bulbar conjunctiva near the limbus occurred (Fig. 5). Later, the secretion became thicker and more profuse. The secretion did not resemble pus. It was thicker and white in color, resembling in appearance and consistency casein in sour milk (Fig. 6). In 9 out of 20 smears tubercle bacilli were found in the secretion.

Ulcers of the lid occurred in four animals. They were first observed at the time of the onset of the conjunctivitis. They were located at the lid margin, and in the beginning were seen as small round elevations which soon broke down and formed ulcers. The ulcers were irregular excavations with mouse-eaten edges. The surface was covered with dirty-gray necrotic material, through which small red points of

granulation tissue protruded. They were chronic in nature, and none healed before the animals died.

Episcleritis was also a late manifestation. It occurred in three animals and appeared after the fourteenth day.

Choroiditis was not seen ophthalmoscopically until after the fourteenth day. It was observed in all the animals in which opacities of the media did not interfere with the ophthalmoscopic examination. Ill-defined oval patches, which were lighter in color than the surrounding fundus, were the first changes which occurred. These soon became yellow in color, without any disturbance of the pigment (Plate II). From ten days to two weeks after the development of the yellow patches pigment granules began to appear on the surface of the masses, and the tubercles became clearly circumscribed. The changes from this point were very gradual, and in the three animals which survived it was possible to follow the steps from active inflammation to atrophy. The pigment which was seen on the surface of the tubercle gradually moved toward the periphery of the lesion and was deposited there. In the atrophic stage the lesions were seen as brilliant white, round and oval areas, with a few pigment granules scattered over the surface, and pigment banked up at the margin of the lesion, or as irregular peppered patches of pigment.

Histologically, the sequence of events in the background of the eye were: first, an infiltration of the choroid with epithelioid cells (Fig. 8). In some sections clumps of bacilli were found in the center of the lesion. In the early stage the pigment epithelium was not disturbed. This corresponded to the first change that was seen in the living eye with the ophthalmoscope (Plate II). Later, small round cells surrounded the collection of epithelioid cells, and the pigment epithelium then showed degeneration and proliferation. The retina then became disintegrated and lost its normal appearance. The pigment cells and pigment granules migrated for-

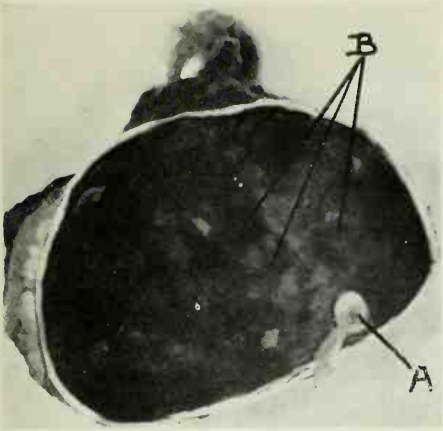

Fig. 7.—Photograph of the posterior portion of the eye from which the retina has been removed. A, Atrophic patch in choroid with a tag of retina adhering to the scar. B, Scattered patches of disturbed pigment.



Fig. 8.—Showing early stage of tuberculosis of choroid. 1, Retina. 2, Proliferated pigmented epithelial cells. 3, Epithelioid cells. 4, Sclera.

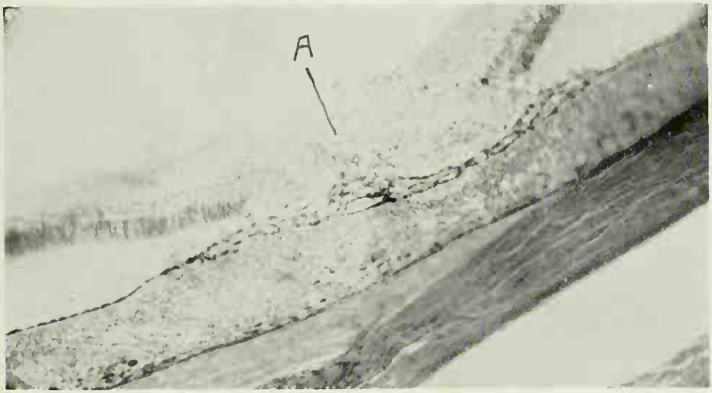

Fig. 9.—Showing choroidal tubercle, proliferation of pigment, and degeneration of retina. A, Complete absence of retinal elements.

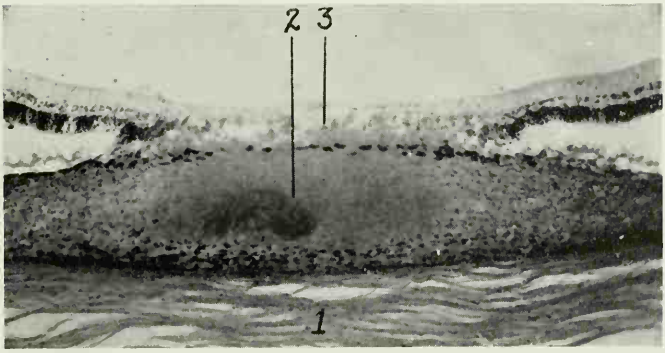

Fig. 10.—Caseous area in choroid with thinning of pigment epithelium over center of tubercle. Atrophy of retina over caseous area. 1, Sclera. 2, Caseated area in choroid. 3, Atrophied choroid.

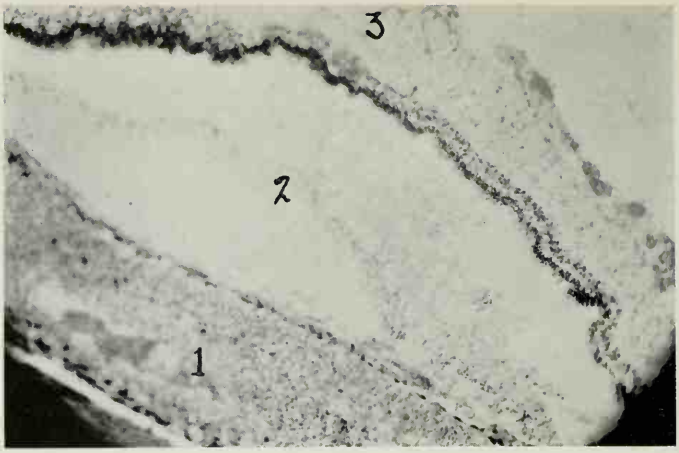

Fig. 11.—Showing detachment of the retina by a sero-cellular exudate in front of choroidal tubercle. 1, Choroidal tubercle. 2, Serous exudate. 3, Retina.

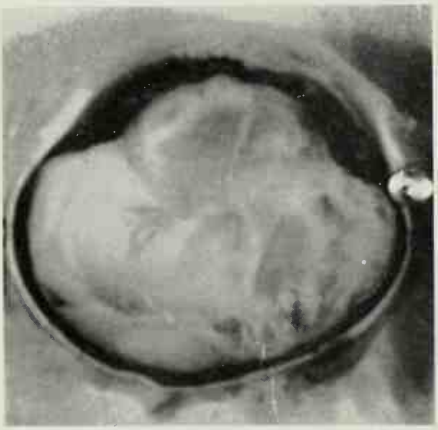

Fig. 12.—Generalized uveitis with dense white exudate in vitreous.

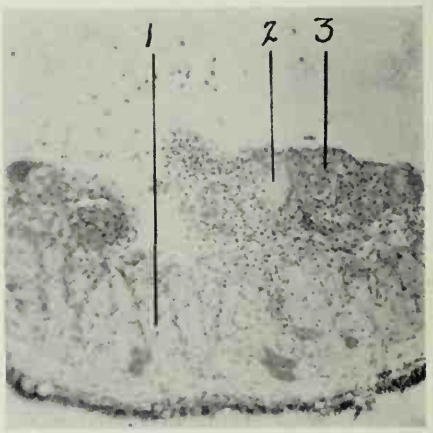

Fig. 13.—Showing perivasculitis of the retinal vessels. 1, Nerve-fiber layer of retina. 2, Retinal vessel. 3, Epithelioid cells.

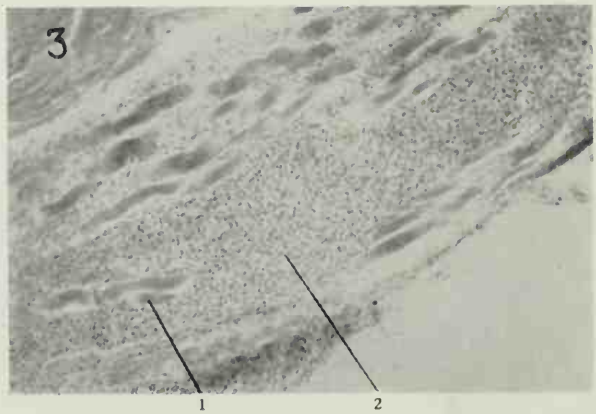

Fig. 14.—Infiltration of extraocular eye muscle with epithelioid cells. 1, Muscle-fiber. 2, Epithelioid cells. 3, Sclera.

ward (Fig. 9). This corresponded to the second stage of the ophthalmoscopic picture. The next stage was caseation in the center of the lesion, with complete atrophy of the retina over the caseous area and disappearance of some of the pigment in the center.

Often localized detachments of the retina occurred over choroidal tubercles. These were seen as brilliant, pearl-like areas in the fundus. They gradually increased in size in the severe cases. The detachments were due to a serocellular exudate which separated the retina from the infiltrated choroid (Fig. 11).

A generalized severe uveitis occurred in the majority of the animals. The vitreous became cloudy and obscured the fundus for ophthalmoscopic examination. In sections of these eyes a severe generalized uveitis, with marked thickening of the choroid, ciliary body, and iris, was always found (Fig. 12).

Tuberculosis of the retinal vessels was observed in only one of the 46 animals. It was seen ophthalmoscopically as a gray, perivascular exudate surrounding the retinal vessels. Choroidal and iris tuberculosis were also present. The animal had lost weight and was killed on the sixteenth day after the inoculation, so that the specimen might be obtained before the animal died. Microscopic examination of sections of the eye revealed the presence of a marked perivasculitis (Fig. 13). In one of the veins an endothelial thrombus was in its formation, and the vein was half obstructed by newly proliferated endothelial cells from the inner wall of the vein.

A tubercle was found in an extra-ocular muscle in one of the sections (Fig. 14). Sections also revealed extension of tuberculosis from the interior of the eye through the sclera into the extra-ocular structures.

This series of experiments confirmed Stock's conclusions and proved that tuberculosis of hematogenous origin attacks all the structures of the eye excepting the lens.

The practical conclusions that are drawn from these experiments are summarized as follows:

Hematogenous eye infections with living tubercle bacilli are of a severe and progressive type, and with few exceptions do not correspond to the types of ocular tuberculosis which occur in the human being. In the exceptional, milder cases, tubercles of the iris and choroid run a course which is similar to that seen in the human being.

The first objective symptoms are seen in the iris, next in the cornea, then the conjunctiva and lids, and then the choroid. The typical iris findings are ridged iritis and caseous tubercles. The tubercles of the iris usually have blood-vessels running over their surface.

Corneal changes that are typical of tuberculosis do not occur frequently after the injection of living tubercle bacilli.

The results that have been obtained in these and later experiments emphasize the well-known clinical fact that tuberculosis of the eye, which occurs in subjects who have an active tuberculosis elsewhere in the body, is usually severe and progressive and frequently necessitates enucleation of the eyeball, while the chronic types occur in persons who have either a mild or latent tuberculosis.

For a practical experimental study of the nature of tuberculosis of the eye as it usually occurs in the human being it is necessary to use small doses of avirulent living or emulsions of attenuated or dead tubercle bacilli.

The author wishes to express his appreciation for the helpful co-operation which he has received from Dr. H. J. Corper, and to the Research Department of the National Jewish Hospital for Consumptives in Denver, which institution has made it possible to carry out these experiments.

REFERENCES

1. Friedrich and Nösske: Kreislauf Ziegler's Beiträge, 1899, p. 470.
2. W. Stock: Klin. M. f. Augenh., 1903, Bd. 1, p. 228.

DISCUSSION

DR. EUGENE M. BLAKE, New Haven, Conn.: I have had the pleasure of examining a great many of the rabbits' eyes in which Dr. Finnoff has produced tuberculous lesions. His results are striking in two points in particular: one, the production of patches resembling phlyctenules, which to my mind usually occur in the tuberculous, and, secondly, the formation of isolated patches of choroiditis, strikingly like those seen in adolescents. I think the latter are now generally regarded as being of a tuberculous nature.

DR. LUCIEN HOWE, Buffalo, N. Y.: I had the pleasure of spending an afternoon with Dr. Finnoff studying these animals, and I think we get from the presentation here only an imperfect idea of the amount of time and patience necessary to obtain these results. But here they are—a revelation. It is fine that we have among us some who care to undertake such work. When we realize that the large majority of us have had at some time some form of tuberculosis, it does seem incumbent upon us clinicians to observe a little more carefully those inflammations of the eye whose causes are obscure, and endeavor to determine their possible relation to that disease.

DR. JAMES A. PATTERSON, Colorado Springs (by invitation): I would like to mention some characteristic bulbar forms of tuberculosis. A recent case of bulbar conjunctivitis in a human being showed very distinct, crater-like excavations penetrating to the sclera and eroding it. This was assumed, because after healing, which was accomplished by dichloracetic acid, there was a pigment area seen at the bottom of the crater. In discussing the case with Dr. Jackson, he expressed the opinion that the crater-like excavation was rather characteristic.

DR. HIRAM WOODS, Baltimore, Md.: Dr. Finnoff was kind enough to go over his work with me the other day in Denver, and, as I understand, he is aiming to find out what tuberculosis can do with eyes. Apparently it can do almost anything. There have been two points brought out here today, one by Dr. Finnoff and one by Dr. Blake, which I should like Dr. Finnoff to speak of more fully.

Dr. Blake's point is that, from the experiments, phlyctenular

conjunctivitis is shown to be the result of tuberculosis. They undoubtedly show that phlyctenular conjunctivitis is often the result of tuberculous infection, but do they show that the clinical presence of phlyctenular conjunctivitis necessarily means a tuberculous cause? I think there is a difference between knowing a thing when we see it, and knowing, when we see it, that it must have been caused by certain agents.

The other point is this: With living bacilli he proved the etiologic connection between certain eye lesions and tuberculosis. I would like to ask if he has gone a step further and cured some of these lesions by tuberculin and the injection of dead bacilli. After all, that is what we want to get out of it as clinicians, just what good tuberculin is to us.

DR. MARCUS FEINGOLD, New Orleans, La.: Before making my remarks, I should like to remind the audience of the repeated statements that have been made by all of us from New Orleans, that we do not see any tuberculosis of the eye in New Orleans in spite of the large percentage of negroes in our population. I have now to modify that statement. Recently a patient of one of my colleagues came under my observation showing a bilateral iritis characterized by innumerable small and larger yellowish, gelatinous-like nodules. The patient had an apical affection and pleural exudate verified by the *x*-ray, but at the same time a strongly positive Wassermann reaction. He improved somewhat under mixed treatment, but glaucoma in the left eye demanded interference.

Because of the patient's race, my friend had to refer him to my service at the Charity Hospital, where I performed an iridectomy on the left eye. The piece of iris removed showed nodules such as described by Dr. Finnoff. The histologic examination, though, showed no caseation in the nodules and no tubercle bacilli, though the sections were stained accordingly. A part of the specimen was stained for spirochetæ and none was found. The nodules contained some epithelioid cells, but mostly lymphoid cells. In the other eye—the better one—some of the nodules disappeared during the treatment, and the iris, under atropin, retracted to the periphery in places; one or two nodules that formerly had been situated in the pupillary margin were now found stranded on the anterior capsule, isolated and away from the iris. I have great fear that the left eye will ultimately have to be enucleated. Since this observation I discovered a nodule in the left iris of a lady who had

been under my observation for six years for bilateral uveitis of unknown cause.

DR. ALLEN GREENWOOD, Boston, Mass.: I would like to ask Dr. Finnoff one question which possibly Dr. Jackson, from his wider experience, will answer. Is there much ocular tuberculosis in patients they see with general tuberculosis? We find in the East that patients with pulmonary tuberculosis rarely have ocular lesions. Patients with bone tuberculosis and other forms of chronic tuberculosis rarely have ocular lesions. I would like to ask Dr. Finnoff and Dr. Jackson what their experience has been along that line.

DR. T. B. HOLLOWAY, Philadelphia: I should like to confirm what Dr. Feingold has just referred to. He may recall the very interesting case of tuberculosis of the cornea and iris that I referred to him a year ago. In this particular case most of the tubercles had vessels across their surface, and in one broad synechia that had formed in the left eye there was a fairly well-marked tubercle, isolated, and lying on the thinned-out portion of the synechia where the iris had retracted.

DR. LUCIEN HOWE, Buffalo, N. Y.: Partly in answer to the point which Dr. Woods has brought out as to the value of tuberculin I am reminded of what some one said to Koch: "You have found the cause of tuberculosis, but you cannot cure it." He answered, "That is true: but we have been at least two thousand years finding the cause, so we ought to have twenty-five, fifty, or seventy-five years to find the cure."

DR. EDWARD JACKSON, Denver, Colo.: Taking the large number in any community that are infected to some extent with tuberculosis, the cases presenting ocular lesions are unusual, or even rare. That is true both in latent and mild tuberculosis and in the more severe cases. Repeatedly the fact has been brought out, in cases we have seen, that where the diagnosis was based on tuberculosis of the eye, the patients were found to be tuberculous elsewhere. One of those cases I saw the other day in Colorado Springs. Five years after I saw the first outbreak in the region of the macula she spent about four months in bed with tuberculous pleurisy. But the other day when I saw her, after several years, she looked well and is evidently leading an active life.

Another case that was examined carefully by some excellent in-

ternists in Denver who are expert in looking for tuberculosis, and who find it sometimes where other people do not, was that of a patient who was tested with tuberculin and pronounced to be free of any evidence of tuberculosis. The man had very aggravated conjunctival tuberculosis situated deeply within the conjunctiva, the sclera was involved, and he had large nodules, particularly the crater-like ulcers that Dr. Patterson has referred to. He went away and spent several months in Arizona and his eyes got better, but he had very severe headaches. Finally the cranium was opened on the probable diagnosis of brain tumor, and the surgeon found chronic tuberculous meningitis.

The great importance of these investigations comes out in this way. Experimental work has enabled us to see the lesion as we see it clinically, then immediately to take the lesion and examine it microscopically. In that way the clinical symptom is connected with the histologic changes in a way that is decidedly important, in tuberculosis and in other diseases. In addition, Dr. Finnoff is coming to a point where he will give us a general and fairly complete picture of ocular tuberculosis from virulent bacilli, and of ocular tuberculosis from dead bacilli; and with that picture before us to compare with our individual cases, we can recognize evidence of ocular tuberculosis that we could not get in any other way. This series of lesions is a series that will never come to the notice of any one man in a life-time, even in a large eye hospital. It is possible in this way to get a complete picture that will be very valuable and throw great light on human tuberculosis, by the comparison we can make with our individual cases.

DR. W. H. WILDER, Chicago, Ill.: The question of the prevalence or frequency of ocular tuberculosis often arises. It seems to me that the experiments of Dr. Finnoff bear out the idea that the development of ocular tuberculosis will depend upon the activity of some distant tuberculous focus and upon the number of bacterial organisms sent into the blood-stream from such a focus. Ordinarily, the individual with any form of tuberculosis has very few tubercle bacilli circulating in his blood, as has been demonstrated by continued and painstaking examinations. That will help us to understand why tuberculosis of the eye is not very frequent. In this respect it is comparable with metastatic ophthalmia.

Thirty or more years ago more cases of metastatic ophthalmia were seen than we see nowadays, because careful aseptic surgery

and obstetrics were not practised to the same extent as they are now, and bacteremia, septicemia, and pyemia, as they were called in those days, more frequently occurred. The same principle probably obtains in tuberculosis of the eye. If a shower of tubercle bacilli get into the blood-stream, some of them may lodge in the eye, and this may result from the activity of some focus that the clinician may not be able to observe.

DR. E. V. L. BROWN, Chicago, Ill.: Dr. Irons and I will present a paper next week at the American Medical Association which includes a review of a previous series of 100 cases, with eight of ocular tuberculosis, and a second series without a single case.

I think the prevalence of tuberculous iritis has been exaggerated, and that, properly studied from the standpoint of the internist, there will be found to be fewer cases of tuberculous iritis than has heretofore been thought to be the case.

DR. WILLIAM C. FINNOFF (closing): These experiments throw no light on the prevalence of ocular tuberculosis in the human. Tuberculosis of the eyes in the human is undoubtedly a very rare disease. It does occur, however. The purpose of this experimental work was to study the nature of tuberculosis as it occurs in the eye. If you will look over the literature on experimental tuberculosis, you will find only a few recorded observations of tuberculosis produced experimentally.

I am not able to make final conclusions. These are only conclusions drawn from my studies with living tubercle bacilli. The purpose of the experiments to the present time has not been to show the effect of tuberculin or other therapeutic measures. First, we must know accurately the course of the disease, and must know whether other conditions produce lesions similar to those that we got in these animals, before we can draw any conclusions as to the effect of any therapeutic measure. That will take at least five years, and more than likely ten or fifteen before we can determine this fact definitely. I hope that some time in the future I will be fortunate enough to have studied a sufficient number of animals to determine definitely whether tuberculin is of value as a diagnostic or as a therapeutic measure; but I cannot tell you that until we know the nature of the disease, and that is not accurately reported in the literature.

The occurrence of phlyctenular lesions in eyes has been found in only a few animals, and my experiments do not prove that the

phlyctenules are due to tuberculosis. Lesions resembling phlyctenules are produced by the tubercle bacillus, but the experiments that we have carried out so far throw no light on phlyctenules.

As to ulcers of the cornea that were crater-like: in the animals in which we used dead bacilli we had eroded lesions and contractions, but these also followed non-tuberculous lesions.

Recently I have been fortunate enough to enucleate an eye in a patient whom I had seen several months before and observed a generalized uveitis. I saw in the retina a yellowish, apparently slightly elevated lesion with a few vessels running over the surface. When I saw the patient again three months later she had a cataract and other symptoms which necessitated the enucleation of the eye. On sectioning the eye we found a tubercle of the choroid that had a caseous center. The retina was also involved. We have not found tubercle bacilli, as I have not had time to make the examination for them. This patient had absolutely no clinical signs of tuberculosis, and she was gone over by a competent internist.

Answering Dr. Greenwood's question—I am sure tuberculosis of the eye is a rare disease. We have plenty of opportunity in Denver to see these cases and we probably see more than exists in other parts of the United States. It is true that we see ocular tuberculosis rarely in generalized tuberculosis, because these cases when they do occur go on rapidly and necessitate enucleation.

The occurrence of miosis on the side injected is probably some disturbance of the sympathetic, because it always occurs on the side that we inoculate.

MELANOTIC EPIBULBAR TUMOR DISPELLED BY THE USE OF RADIUM

WILLIAM H. WILDER, M.D.
Chicago

The following case of a densely pigmented growth of the sclera, involving the limbus of the cornea, presents, in its course and in its response to the action of radium, such interesting features that it seems worthy of record:

Miss L. C., aged forty-one years, first consulted me February 3, 1920. She was a healthy, well-formed white woman, 5 feet 1½

Fig. 1.—Appearance of epibulbar tumor, February 10, 1920 (before treatment).

Fig. 3.—Appearance, December 1, 1922, six weeks after the conclusion of the last series of nine treatments, from May 8, 1922, to October 10, 1922, with radium plaques and tubes aggregating 110 mg. hours. Tumor has disappeared. Scattered areas of pigment still present.

Fig. 2.—Appearance, May, 1922, showing recurrence after the growth had largely disappeared following 86 treatments, aggregating 1132 mg. hours with emanation tubes.

Fig. 4.—Appearance, May 15, 1923. Growth has disappeared, as well as most of the pigment. No treatment since October 10, 1922.

inches in height, weighing 110 pounds, a distinct brunette, with a clear, healthy complexion.

She had measles, whooping-cough, and mumps in early life, and at the age of seven years scarlatina, and one year later typhoid. She suffered in early life from constipation and supposed liver trouble. Menstruation did not begin until the age of seventeen years, and then was rather irregular and more profuse than normal. When she was twenty-five years old she began to suffer with attacks from what was called chronic appendicitis, and later suffered with sciatica for several months. At the age of thirty-four years an appendectomy was done, and a small cyst was removed from one ovary, after which she had no more sciatic attacks and menstruation became normal and regular. She states that her skin was darker and more sallow before the appendectomy than it has been since the operation. For some time before the appendectomy and up to a time about three years before I first saw her she suffered at frequent intervals from attacks that were called by her doctor "gall-bladder disturbance," causing nausea and pain in the region of the liver, although she never became jaundiced. The gall-bladder had never been operated on, and she has had no attacks in the last six years. She has no moles or pigmented spots on the body or limbs.

Family History: Father, living at the age of seventy years, has always been healthy. Mother died at thirty-nine years of pneumonia. Father's parents lived to be old and were healthy, as were also her brothers and sisters. Mother's father lived to be old. Mother's mother died at age of twenty-three years from infection following child-birth. Patient said there was no history of cancer in the family as far as she knew.

Since early childhood there had been noticed a small pigmented spot on the temporal side of the eyeball not far from the cornea. About four years before the time when she first consulted me she thought this spot was slowly increasing in size, and in two or three years more she was sure it showed signs of active growth. She sought treatment from a local specialist, who used drops and ointments for six months without effect. Later she consulted other specialists in towns near her home in Illinois, who thought the growing mass could be dissolved with drops, and one who advised its removal with an electric cautery, which, however, was not done.

A short time before I saw her she had consulted Dr. J. Lifschutz and Dr. George Suker, of Chicago, who agreed that the growth was

malignant and advised that the eyeball should be enucleated. As the eye had good vision, caused her no discomfort, and seemed to her to be in every other respect normal, she declined to accept the advice given her, hoping that some other treatment might benefit.

Examination showed a flat mass on the temporal side of the left eyeball, irregular in outline, about 10 mm. in its vertical dimension, about 8 mm. in its horizontal dimension, heaped up around the temporal limbus and pushing over the cornea about 1 mm. It seemed to vary in thickness from 1 to 2 mm., being somewhat thicker near the limbus and thinner as it spread over the sclera. It was deeply pigmented in places and there was considerable pigment in the episcleral tissue around it. The edge that was advancing over the corneal margin was distinctly demarcated and was light gray in appearance. Numerous small blood-vessels could be seen in the tumor with a loupe, and it was supplied by several larger vessels that coursed over the temporal side of the eyeball and in the conjunctiva.

Some idea of the appearance can be gained by the photograph (Fig. 1), which, however, lacks the coloration and does not show the height of the mass.

There was no sign of any involvement of the iris or ciliary body. The pupil reacted normally to light and accommodation, and dilated evenly and widely after instillation of a two per cent. homatropin solution.

Refraction under cycloplegic showed:

V.R.E. with +2.00 sph.⌔+0.50 cyl. ax. 75° = 20/30.

V.L.E. with +1.50 sph.⌔+0.25 cyl. ax. 15° = 20/30.

The media were perfectly clear and the eye-grounds appeared normal. Transillumination gave no indication of a growth in the interior of the eye.

The tumor presented all the appearances of a melanotic sarcoma, and the patient was informed of the risk she ran in attempting to save the eye. As she suffered no discomfort from it and had as good vision as she had ever had with that eye, she refused to consider enucleation, and hence treatment with radium was suggested. There was no clinical history of lues, and the Wassermann tests were negative.

Treatment was begun and carried on in great part in the Frank E. Simpson Radium Institute in Chicago, and later in the laboratory of the Physicians' Radium Association of Chicago. The treatments were carried on with emanation tubes of 50 mc.,

screened with 2 mm. of gold, held at a distance of 4 mm. from the growth for fifteen minutes. The healthy cornea and the rest of the eyeball were protected by a thick gold screen fashioned in the shape of an artificial eye. The following shows the number, duration, dates, amount of radium used, screening, distance, and millicurie hours of each series of treatments:

Number Treatments	Duration each Treatment	Dates, 1920	Amount	Total Hours	Screen	Distance	Mc. Hours
10	15 min.	Feb. 3, 4, 5, 6, 7, 9, 10, 11, 12, 13	50 mc.	2½	2 mm. gold	4 mm.	125
10	15 "	Mar. 2, 3, 4, 5, 6, 8, 9, 10, 11, 13	50 mc.	2½	" "	"	125
10	15 "	Apr. 5, 6, 7, 8, 13, 14, 15, 16, 17, 23	50 mc.	2½	" "	"	125
11	15 "	May 21, 22, 24, 25, 26, 27, 29, June 2, 3, 4, 5	50 mc.	2½	" "	"	125
				2¾	" "	"	137
6	15 "	June 25, 26, 28, 30, July 1, 2	50 mc.	1½	" "	"	75
7	15 "	Sept. 2, 3, 4, 10, 11, 13, 14	50 mc.	1¾	" "	"	87
8	15 "	Oct. 26, 27, 28, 29, 30, Nov. 1, 2, 3,	50 mc.	2	" "	"	100
		1921					
11	15 min.	Mar. 26, 28, 29, 30, Apr. 1, 4, 5, 8, 11, 13, 15	50 mc.	2¾	" "	"	137
6	15 "	June 8, 9, 10, 11, 13, 14	50 mc.	1½	" "	"	75
2	15 "	Aug. 24, 25	125 mc.	½	" "	"	63
3	15 "	Nov. 4, 7, 9	125 mc.	¼	" "	"	32
		1922					
2	15 min.	Jan. 19, 21	125 mc.	½	" "	"	63
Total 86						Total	1,269

Up to July 2, 1920, the patient had received 47 treatments in five series with intervals of rest between. It was evident that the growth was much smaller and in places had almost disappeared. Pigment was scattered rather widely over the sclera beyond the site of the fleshy growth. She received another series of treatments in September, October, and November, 15 in all, after which treatment was discontinued for a time. It was noted that the fleshy growth on the sclera had almost entirely disappeared, but there still remained a slightly elevated, membrane-like growth along the temporal limbus of the cornea. There were rather dense, irregular pigment patches in the conjunctiva and in the episcleral tissue distributed widely above and below the original site of the tumor.

The patient was not seen by me for several months, having gone to her home in the central part of Illinois, but on March 26, 1921,

when she came again, it was noted that the growth seemed to have become active and seemed to have spread along the lower margin of the cornea. The pigment patches were still pronounced in the tissues above and below the growth.

She was again subjected to the same treatment as before, receiving 11 applications of rays of fifteen minutes' duration from a 50 mc. emanation tube at intervals during the next twenty days. An interval of rest of two and a half months followed when no treatments were given.

In the second week in June, 1921, she again received six daily treatments of the same dosage and duration, and it seemed as if the growth was being checked. On July 14, 1921, Dr. George de Schweinitz saw the case in my office and agreed with me that it had all the appearance of a melanotic sarcoma and that enucleation would be the best procedure. He suggested that a few large doses of radium should be given instead of repeated smaller doses.

Two treatments, fifteen minutes' duration, with 125 mc., were given on two successive days in August, followed by a period of two months' rest. It seemed as if the growth had been again arrested.

In November she received three more treatments of 125 mc. for fifteen minutes with intervals of two days between treatments.

Another rest period of two months was followed by two more treatments on January 19 and 21 with 125 mc. From February 3, 1920, to January 21, 1922, she had eighty-six treatments of fifteen minutes' duration, aggregating 1269 milligram hours.

In February, 1922, the growth on the cornea looked thinner, and that on the sclera seemed to have largely disappeared, but there was still an abundant pigmentation of the whole region. The patient had an abounding faith that she was getting better and would recover. In May, 1922, it was clear that the growth was again increasing and was extending over the cornea from below. The appearance at this stage was much like that depicted in the colored drawing, Fig. 2.

She was then sent to the Physicians' Radium Association of Chicago for treatment, under the direction of Dr. Wm. L. Brown, and in the next six months received nine treatments in the following manner:

May 8, 1922: One tube, 100 mgs., screened with 1.0 mm. of platinum and 3.0 mm. of lead with window in lead corresponding

with the size of the lesion, was moved slowly about the affected area for fifteen minutes.

May 12, 1922: One full-strength plaque 5 mgs., screened with 0.7 mm. of rubber except for an aperture 5 mm. in diameter, moved over the growth for fifteen minutes at a distance of about 2 mm.

June 5, 1922. One full-strength plaque 5 mgs., screened with 0.7 mm. of windowed rubber, with one tube of 100 mgs. on the back of the plaque, the tube screened with 1.0 mm. of platinum, moved over the lesion for fifteen minutes at a distance of about 2 mm.

June 12, 1922: Treatment of June 5th repeated, fifteen minutes.

June 26, 1922: Treatment of June 5th repeated, fifteen minutes.

July 17, 1922: One full-strength plaque 5 mgs., screened with 0.2 mm. of aluminum and 0.7 mm. of rubber and a window 5 by 8 mm. to correspond with the size and shape of the lesion, held in one position over the lesion for fifteen minutes, and almost in contact with it.

July 31, 1922: Treatment of July 17th repeated, fifteen minutes.

Sept. 8, 1922: Treatment of July 17th repeated, fifteen minutes.

Oct. 10, 1922: Treatment of July 17th repeated, fifteen minutes.

Making nine treatments in all, 110 milligram hours.

The full-strength 5 mgs. plaque which is mentioned is a metal square, 10 mm. square, containing 5 mgs. of radium distributed over the surface of this area. The radium paste is held in place by a transparent varnish with so little resistance to the radium rays that for all practical purposes the screening is zero. Where there is mentioned windowed lead in the use of the tube, the lesion was subjected to irradiation through 1.0 mm. of platinum only, except where the tube was used in conjunction with the plaque, in which case it was screened with the 1.0 mm. of platinum with the thickness of the plaque in addition. When the full-strength plaque was used, the lesion was always subjected to direct unscreened irradiation.

The case was presented at a clinical meeting of the Chicago Ophthalmological Society, May 15, 1922, about the time the last series of treatments was being started. Professor E. Fuchs was present at the meeting, examined the case carefully, and took part in the discussion (Amer. Jour. Ophth., September, 1922, p. 729).

The author expressed the thought that because of the chronicity of the growth, it might not be a melanotic sarcoma, as was supposed, but one of the rare forms of pigmented epithelioma, a view with which Dr. de Schweinitz, who had again seen the case, was inclined to agree.

Professor Fuchs thought the case a most extraordinary one, but doubted the existence of pigmented epithelioma, and thought such a tumor started from a nevus, which is mesoblastic tissue and hence is a regular sarcoma. He thought the safest procedure would be to remove the eye together with all the conjunctiva containing pigment. He suggested as an alternative that the tumor mass be excised, the surface cauterized with the galvanocautery, and treated afterward with radium. If the examination showed the excised tissue was sarcoma, the eyeball should be at once enucleated. If it proved to be carcinoma, it was not so dangerous, although there would be likelihood of local recurrence.

When reminded of the small pigmented spot that had been on the sclera, from which the tumor had grown, he thought that spoke for the existence of a nevus, and that the growth was probably melanotic sarcoma.

The patient again declined enucleation or any operative procedure and the radium treatments were continued. On July 24, 1922, after six treatments, it was noted that the condition was much improved, and that the pigment, scattered over the sclera and through the conjunctiva, was disappearing. The last treatment was given October 10, 1922, and by October 31 the growth on the cornea had almost entirely disappeared. Improvement continued, even the pigment gradually fading away (Fig. 3).

At the time the last colored drawing (Fig. 4) was made, May 15, 1923, there was no sign of the growth on the cornea, except a faint line seen with a loupe on the inferior temporal quadrant of the limbus and a few peppery spots of pigment here and there in a rather more deeply shaded area of the

sclera, which had formerly been almost black. The vision of the eye remains 20/30, the same as before, and there is no sign of any change in the interior of the globe. The patient's health seems to be perfect, she has gained 22 pounds in the last three years, and there are no signs of metastasis.

The prompt response to the last series of nine treatments in which smaller doses of radium metal were used is in marked contrast to the results obtained with larger and more frequently applied irradiations from emanation tubes.

How much effect is to be ascribed to the cumulative effect of such long-continued treatments is a question for radiologists, but some maintain that the cumulative effect is not great. It would seem as if the shorter beta rays from the radium distributed over a plaque and brought into closer contact with the surface of the growth were much more effective in disorganizing it than the more deeply penetrating gamma rays. Whether the tumor is destroyed or only dispelled, can be answered only by future developments. At present the case has the appearance of being cured.

RECURRENT PIGMENTED GROWTH AT LIMBUS

W. H. LUEDDE, M.D.
St. Louis, Mo.

On Dec. 2, 1913, Louise O., white, blond, blue-eyed child, aged four years and ten months, was brought to me on account of a dark spot on the right eye. The eye had been struck by a ball eighteen months before. Her mother was positive that the spot was not noticed until at least one year after the injury. She was unable to state whether it had increased in size during the last six months.

Examination showed a small dark spot located near temporal limbus, with some gelatinous thickening of conjunctiva at limbus. Macroscopic appearance resembles a cinder or dirt particle encysted in the conjunctiva. With the binocular corneal micro-

scope or loupe this mass appears to be a pigmented growth with small specks of pale brown pigment at the extreme corneal border of the mass, probably representing beginning foci of an extension of the growth in that direction. With the aid of a measuring ocular in the corneal microscope it was determined that the vertical diameter of the pigmented area did not extend one mm., while the horizontal diameter was not more than 0.8 mm.

Ophthalmoscopic examination showed the ocular fundus to be normal and media clear. With each eye vision = 16/15. The pupils were equal and the iris movements normal. Close observation of the condition was advised, with probability of surgical removal being required.

Three weeks later a slight increase in the size of the pigmented nodule was demonstrable with the corneal microscope. Each space in the No. 2 measuring ocular with A 2 obj. is equal to 0.04 mm. Therefore a very minute increase in the size of this pigmented area could be positively detected by this method.

Six days later the increase in size was confirmed by re-examination and the immediate removal of the growth was advised. This was done four days later under general anesthesia. A triangular flap with its base at the limbus, including conjunctival and episcleral tissue and extending several millimeters beyond the pigmented growth, was raised and dissected toward the limbus, where it was cut off with scissors. The adjacent conjunctival tissue above and below was drawn in to cover the denuded surface, three interrupting sutures being used. Argyrol, 20 per cent., was instilled in the conjunctival sac and the eye covered with the customary dressing of cotton and gauze attached by a collodion border.

As the possible malignant character of this growth was still undetermined it was not deemed desirable to destroy tissue unnecessarily by cauterization of the scleral surface. Recovery was uneventful. The patient was kept under close observation at regular intervals.

Three months later a tiny brownish stain appeared at the temporal limbus, right eye, which might have been due to extravasation of red blood-cells caused by paroxysms of severe coughing, as the patient had contracted whooping-cough.

Seven months after the removal of the nodule the patient got some dust in the right eye, resulting in a mild conjunctivitis. After two weeks the conjunctival hyperemia—both palpebral and

ocular—was more pronounced and the suspected blood pigment stain at the site of the former pigmented growth, having persisted after the recovery from whooping-cough, began to show a slight increase in size. This increase was evident even after the general conjunctival inflammation had been controlled by routine treatment. By the use of adrenalin the presence of actual pigmentation was clearly recognizable against the white scleral background, indicating that the condition was not merely incidental to the conjunctival hyperemia.

After a few days spent in developing the confidence of the fearsome young patient in the efficacy of local anesthesia, it was possible to use instillations of cocain and adrenalin instead of general anesthesia for the removal of this pigmented conjunctival tissue. This was located at the identical point on the temporal limbus from which the original growth had been removed eight months before. On this occasion a similar triangular flap extending well into the healthy conjunctival and episcleral tissues was raised, but dissection was begun at its base, that is, at the limbus, using a cartilage knife with a special thin cutting edge extending entirely around its tip. This enabled a very close dissection from the limbus outward, beginning at the level of Bowman's membrane. The adjacent conjunctiva was again brought together to cover the denuded area without cauterization as before, and an uneventful recovery followed. Tiny pigment granules apparently due to the subconjunctival hemorrhage accompanying the operation remained demonstrable with the corneal microscope for six months. Four months after the operation a small spontaneous (?) subconjunctival hemorrhage was noted about 8 mm. beyond the temporal limbus.

Examination of the eye on May 12, 1915, eight months after removal of the secondary pigmented growth, failed to reveal any trace of pigment granules, confirming the supposition that these had been remnants of extravasated red blood-cells which would become absorbed.

Repeated observations were made without any evidence of the slightest deviation from normal until March 4, 1922, when she returned with the statement that during the previous week a tiny black speck had made its appearance at the same point on this eye. As the original pigmented nodule was first discovered during the summer of 1913 and was removed in December of the same year, an interval of more than eight years had preceded this recurrence.

The last examination by the writer previous to this recurrence had been made on January 3, 1920, at which time conditions were found perfectly normal. As the patient and her mother were keenly alert and fully aware of the possible significance of a recurrence, their statement of the very recent appearance is entirely trustworthy. No exciting cause for the recurrence at this time could be elicited. The patient is apparently in perfect health and has the physical development normal for a girl of her age (thirteen years).

Measurements with the ocular micrometer and corneal microscope showed a horizontal diameter of 0.56 mm. and a vertical diameter of 0.74 mm., with slight radiation of pigment granules downward and temporally. It was removed immediately under local anesthesia, after the instillations of 5 per cent. cocain solution and 1/10 per cent. adrenalin solution, following the method used in the last operation. No pigmentation of the sclera was found, but the scleral base of the tumor was curetted and tincture of iodin applied before closing the conjunctival wound with interrupted sutures. There was noticeable oozing from a tiny branch of the anterior ciliary vessels which perforated the sclera immediately below the location of the pigmented nodule. Not the slightest evidence of pigment extension from within outward along the course of this blood-vessel could be found. Recovery was uneventful, and monthly inspection to date has failed to reveal anything of a pathologic nature.

Clinically, this case presents several phases suggesting malignancy.

First, we have a pigmented growth where pigment is normally absent. Stoehr[1] says that, with the exception of Europeans, pigment is normally present in the ocular conjunctiva of human races and in all (?) mammals. The mere presence of pigment does not clinically distinguish this growth from a nevus. However, a congenital nevus not infrequently degenerates into a malignant melanoma.

Second, the appearance of the pigmented mass was preceded by an injury of the type recognized as a possible cause of sarcoma. Examples of such occurrences may be found in

the literature of general pathology as well as in ophthalmic practice.

Moller[2] reports a papillomatous tumor in a man aged forty-seven whose eye had been injured three months before. The tumor mass was found to contain a splinter of wood. Enlargement of the pre-auricular gland, which subsided under *x*-ray treatment, and multiple metastases elsewhere established the malignant character of the growth.

H. Marua[3] reports a typical sarcoma involving the whole of the superior rectus after a contusion of the upper half of the upper eyelid.

MacCallum[4] states that "Single severe injuries, such as blows or fractures, have frequently been followed by the development of a sarcomatous tumor although rarely by a carcinoma." He explains that "chronic or repeated mechanical irritation, the changes produced by light, *x*-rays, and radium, and by chemical irritants and bacteria, are more generally associated with the development of carcinoma." He very properly adds, however, that as "thousands of such injuries have no such results, it may well be questioned whether the connection is not an accidental one."

In the third place, we had two recurrences of pigment nodules at the original site after removal of the primary nodule. The mere recurrence of the growth does not establish its malignant character although it constitutes an important and significant factor. Referring particularly to the last recurrence which developed more than eight years after the original growth was removed, one may well be justified in accepting it as a clinical indication of malignancy. This last recurrence in one week attained a size nearly equal to that of the original pigmented nodule after six months.

Certainly it is not characteristic of nevi or of any benign growth to return after such an interval and to exhibit such a tendency to rapid growth.

A search of ophthalmic literature *failed to reveal any case*

where the removal of a nodule as small as this was followed by a recurrence. Nor was there any recurrence of a pigmented conjunctival growth after so long an interval following the removal of a tumor of any size. Apparently the nearest approach is a case of Hirschberg's,[5] examined and reported by Ginsberg,[6] in which a small brown speck occurred in the conjunctiva of the socket, just below the scar, five years after the enucleation of an eye on account of choroidal sarcoma. It was excised and histologic examination showed several pigment knots submiliary in size and scattered single cells of typical chromatophores. Next in line for length of interval before recurrence, and more comparable to the present case as it concerned a pigmented sarcoma of the limbus, was a case of Jessop.[7] The primary growth had been removed and its base freely cauterized. Conditions were normal at two and one-half years, but at the end of four years there was a distinct recurrence, "although still minute."

de Schweinitz and How[8] reported a case of recurrent epibulbar tumor in which the primary growth, though several times larger (2 mm. by 4 mm. by 1.5 mm.) than our present case (not over 1 mm. in diameter), presented the identical histologic picture; that is, "portions suggesting sarcoma and epithelial inclusions suggesting early epithelioma." In their case the growth was first removed by cauterization with trichloracetic acid. It returned and was removed by surgical dissection eight months later. It recurred a second time after an interval of eight months and was treated with radium with a very severe reaction but apparent cure. In another case reported at the same time by de Schweinitz and How, a small pigment mass, 1 mm. by 1.5 mm., was removed from the limbus without recurrence. It proved to be a melanotic round-cell sarcoma or melanoma.

It is altogether admirable to find the exact dimensions given as in these two cases. There appears to be no excuse for the bad habit so often noted among German authors of

substituting a slipshod comparison with the size of large or small nuts, seeds, or fruits, for the accuracy of a direct measurement.

Our case again appears to be rather unique in the early age at which the primary growth developed. Collins and Mayou[9] give the lowest age as eight years. Roy[10] reports a case of sarcoma of the conjunctiva in a boy aged six.

In one respect, our case, fortunately, has not furnished evidence of malignancy. There have not been, to date, any signs of metastasis. That the latter may occur even before the primary growth has shown definite signs of malignancy was demonstrated in the case reported by von Hoor.[11] In that instance the exact measurement of the primary pigmented growth can only be surmised. It is given as approximately the size of a pinhead. An average pinhead measures 1.5 mm. in diameter. It was probably some, but not much, larger than the pigment nodule in our case. Secondary nodules the size of millet seeds were present about 6 mm. to the temporal side of the primary nodule at the limbus. These were excised and found to be sarcomatous, after which von Hoor[11] recommended enucleation, which was refused, and the patient consulted Prof. Fuchs at Vienna who removed the primary nodule, cauterized its base, and reported that the histologic appearance indicated a simple pigmented nevus with possibly one larger nodule that might be regarded as the beginning of a melanosarcoma. Fuchs added that he regarded the prognosis favorably, and did not believe there would be a recurrence. On the day preceding the receipt of the letter of Prof. Fuchs containing the report just noted, not quite two months after the removal of the primary growth, the mother of the patient wrote to von Hoor that the preauricular gland on the same side was swollen. It was removed as soon as the patient was brought to Budapest and was found on section to be as black as India ink ("Tuschschwarz"). In two months similar swelling of the submaxil-

lary and cervical glands was noted, but the patient refused operation and died three months later.

Clinically, such experiences fully justify the conclusion of von Hoor to insist on the immediate removal of every nævus pigmentosus.

Our own case constitutes a complete clinical endorsement of the position taken in discussion by Loring and Verhoeff[12] in advising removal of the growth instead of enucleation of the eye only when it is very small, circumscribed, or pedunculated, and that such conservatism requires continued observation for some time.

Histologically, the primary growth in this case presented characteristics common to both benign and malignant pigmented conjunctival tumors at the limbus. It showed some proliferation of connective-tissue cells with an irregular distribution of pigment cells resembling normal chromatophores. The epithelial surface was reduced at some points to the thinness of one or two layers of cells. At others, extensions of root-like processes of epithelial cells into the subepithelial tissues indicated an epithelial hyperplasia of possible pathologic significance. This was emphasized by the presence of detached epithelial cell roots within a subepithelial tissue surrounded by masses of actively growing cells whose origin, whether epi- or mesoblastic, is a question as yet unsettled after several decades of discussion.

At some points near the periphery there were apparent vacuoles in the epithelial layer containing cells of this same type. Leber[13] made similar observations, except that partial pigmentation of epithelial cells was present in his cases. He agrees with Unna[18] that all of these cells are of epithelial origin and that their resemblance to connective-tissue cells is due to a histologic metamorphosis. According to Dolley,[14] it is equally proper to attribute these vacuoles in the epithelial layer, as well as its thinning out over certain portions of the growth, to the invasive and destructive properties of abnor-

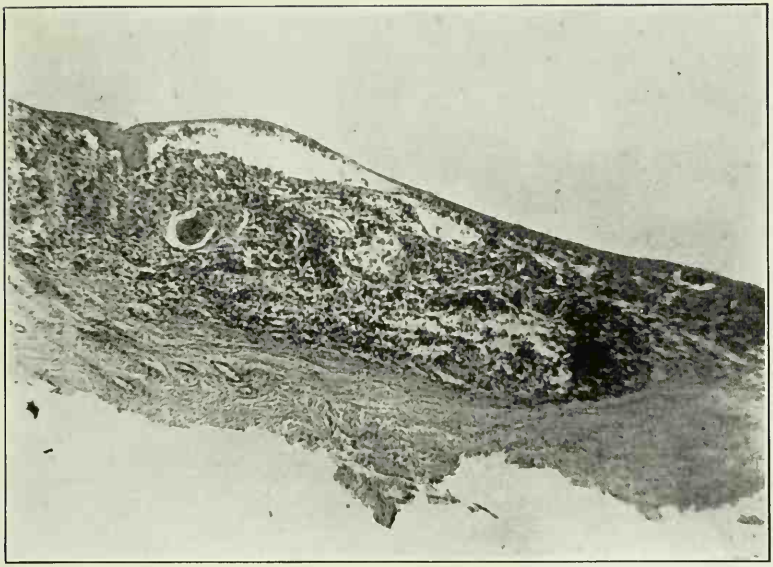

Fig. 1.—Section of growth.

mally developed connective-tissue cells, which in view of the presence of pigmentation probably are derived from chromatophores, as assumed by Ribbert.[15]

Collins and Mayou[9] refer to the fact that pigment granules are present extensively in the subepithelial connective-tissue cells in the conjunctiva of dark human races; and, furthermore, that epibulbar growths are usually pigmented and that the pigment is melanin and not hematogenous. They assume that these growths are of mesoblastic origin.

The term "nevus cells" may be used to evade a decision on the question of origin. It defines a type of cell but does not account for them. More frankly, Lagrange[16] gives approval to Panas'[17] theory that sarcomatous elements may be added to an epithelioma, and suggests the name "epitheliosarcome."

In the secondary growth the first recurrence shows a slight amount of pigment formation and some proliferation in the subepithelial tissue which might be regarded with suspicion. The irregularity of the epithelium immediately adjacent to the limbus can be explained by the cicatricial formation following the first operation. Dr. D. H. Dolley, after a study of the serial sections, does not believe that they show anything except the abnormal presence of a few chromatophores which could not fully be explained on the basis of a chronic conjunctival irritation.

The following report from Dr. Harvey D. Lamb accounts for the third specimen (or second recurrence) in this case: "In June, 1922, your specimen, in 10 per cent. formalin, macroscopically a very small and pigmented bit of conjunctival tissue, was given to the technician with a number of other specimens. For some unaccountable reason it was lost, and although an intensive search for it was made it could not be found. I add my profound regrets to those of the technician."

In our case, as pigment was absent from the epithelial cells and as the proliferating chromatophores or connective-tissue

cells of the primary growth show a definite invasive tendency, the diagnosis of melanosarcoma appears to be correct. The absence of such definite characteristics in the secondary growth agrees with the report of Ginsberg[6] concerning the recurrence after choroidal sarcoma as above noted. The amount of pigment was too small to make the interesting tests suggested by Wells[19] to determine differences in the chemical composition of melanin.

REFERENCES

1. Stoehr: Text-book on Histology.
2. Moller, P.: Sarcoma from Injury of Eye, Ugeskrift for Laeger, 1921, v. lxxxiii, pp. 1239–1243.
3. Marua, H.: Klin. Monatsbl. f. Augenhk., Jan., 1911, p. 69.
4. MacCallum: Text-book of Pathology, 1918, p. 1037.
5. Hirschberg: Discussion Pseudogliom, Ophth. Ges. Heidelberg, 1896.
6. Ginsberg: Pathologische Histologie des Auges, 1903, p. 73.
7. Jessop: Trans. Ophth. Soc. U. K., v. xxviii.
8. de Schweinitz and How: Clinical and Pathological Notes on Two Epibulbar Growths, College of Physicians, Phila., v. xxxvii, p. 453, 1916.
9. Collins and Mayou: Pathology and Bacteriology of the Eye, p. 137.
10. Roy: Extensive Sarcoma of Conjunctiva, Montreal Med. Jour., Oct., 1909.
11. von Hoor, C.: Malignancy of Pigmented Tumors of the Eye, Klin. Monatsbl. f. Augenhk., May, 1913, p. 584.
12. Verhoeff and Loring: Tenth International Congress of Ophthalmology.
13. Leber: 27th Vers. d. Ophth. Ges., Heidelberg, 1898.
14. Dolley, D. H.: Personal communication.
15. Ribbert: Ziegler's Beitrag z. allg. Path. u. path. Anat., 1897.
16. Lagrange: Encyl. Française d'Ophtalm., v. v, p. 1131.
17. Panas: Quoted by Lagrange (see reference No. 16).
18. Unna: Quoted by Ginsberg (see reference No. 6).
19. Wells: Chemical Pathology.

DISCUSSION

DR. ARNOLD KNAPP, New York: The disappearance of pigment in Dr. Wilder's first case is surely very unusual. Those who are conversant with the action of radium tell me that usually they do not expect it to have any influence on pigment.

In this connection I would like to draw attention to a late result of radium action on the eye which I have observed in two cases. One was a tumor of the cornea which was successfully dispelled by its use, and the second was a skin lesion at the outer canthus. In these two patients about eighteen months or two years after radium treatment a posterior cortical cataract developed.

DR. T. B. HOLLOWAY, Philadelphia: During the past several

years I have had a patient who has had many things in common with the patient referred to by Dr. Wilder. She first came under my observation in October, 1916, and stated that six months before she had noted a small spot at the corneal limbus. She was treated with non-irritating remedies for about one year, when, owing to the fact that she had been advised that mild cauterization might be of service, I began the use of local applications of iodin. The applications were made once every week or two, and for a time acted almost like a specific. The original size was 4.5 by 2.5 mm., and it subsided to about 1 mm., with very marked decrease in the injection. Then a spot of pigmentation developed and the lesion began to grow. In January, 1920, it was excised after splitting the cornea, and a conjunctival flap was then resorted to. The eye remained quiet for four months, when there was a recurrence adjacent to the site of the first lesion. Subsequently iodin applications were again used.

The patient was seen in consultation by Dr. de Schweinitz as well as by Dr. Casey Wood, who chanced to be in the office at the time of her visit. Later she was seen by Professor Fuchs, who also examined the sections of the first growth and thought the cells to be nevus cells. Later the lesion was excised and the thermophore used before throwing over a conjunctival flap. The eye has remained quiet for about nine months.

DR. WILLIAM ZENTMAYER, Philadelphia: I should like to cite the history of a case treated by radium in which the result was apparently like Dr. Wilder's. The growth almost entirely disappeared, the eye functioned properly, and we had every hope that we had succeeded in curing the local lesion; but about eighteen months after this apparent cure the patient died of general metastasis. I was very severely criticized by the attending physician during the last illness who told the family that had the case been treated properly by radical measures the man would still be living.

DR. ALLEN GREENWOOD, Boston, Mass.: A case that I wish to mention very briefly is one that came under my care from Dr. de Schweinitz, who made a diagnosis of melanosarcoma of the limbus and advised enucleation. I enucleated the eye and about six months later the conjunctiva showed large pigmented areas. Under radium these areas entirely disappeared. I mention this because Dr. Knapp said pigmented areas were hard to dissipate with radium. This case was treated one entire year with radium

and there has been no recurrence of spots on the conjunctiva. The case proved to be one of melanosarcoma.

DR. W. H. WILDER (closing): I think we should not leave this subject with the impression that such cases can be certainly cured either by local removal or by radium. Such neoplasms are deadly things and the dermatologists can tell us of innumerable cases where pigmented areas, like moles, have spread like prairie fire after attempted extirpation. So we are treading on dangerous ground when we tell these people that we can offer much hope by local extirpation, and we do not know enough about the action of radium to know whether or not by its use the cancer cells are completely disorganized. This case is the most remarkable of its kind I have ever seen, and this opinion was concurred in by all who saw it, and yet we have no assurance that this neoplasm has been anything more than dispelled.

The experience of Dr. Zentmayer indicates how dangerous it is to attempt to remove such growths unless we are prepared at the time, when we take off a piece of tissue for examination, to go on with radical treatment if necessary. I believe that is the attitude of surgeons today, in regard to suspected malignant growths.

We have no assurance that, even if several years elapse, there may not be some element in the growth that will light up trouble in the future. I recall a demonstration in Vienna, thirty-two or thirty-three years ago, when Kolisko showed specimens of melanotic sarcoma from the liver, lungs, spleen, marrow of the bones, and other tissues of the body, and also the eye of the same patient that had been removed thirty years before for melanosarcoma of the choroid. If such an interval as that can elapse and the patient develop metastasis, I think we should hesitate before we make a positive prognosis.

The point I bring out as to treatment is that 86 treatments with as high dosage of radium as we felt the eye could stand seemed to have no permanent effect in disorganizing the growth; but when we resorted to the method of using radium in very small doses, so that we got the burning effect of the beta rays, we got pronounced result. So it is a question just how we will apply the radium, and for advice on that subject we must defer to the expert in radiology.

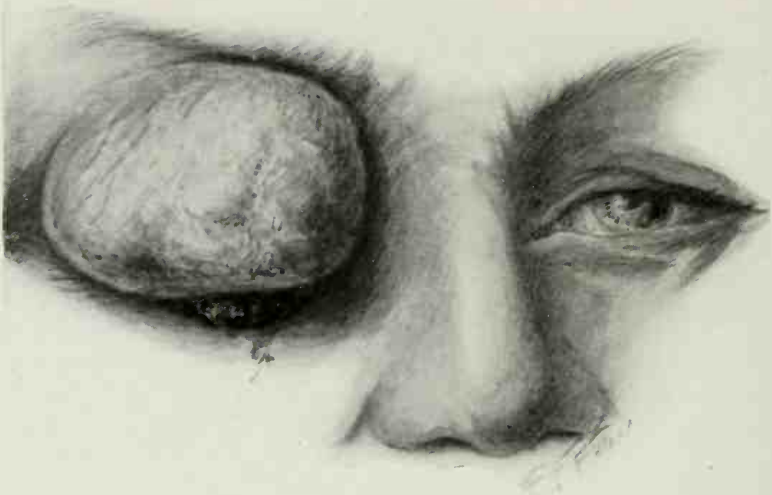

Fig. 1.—External appearance of the growth.

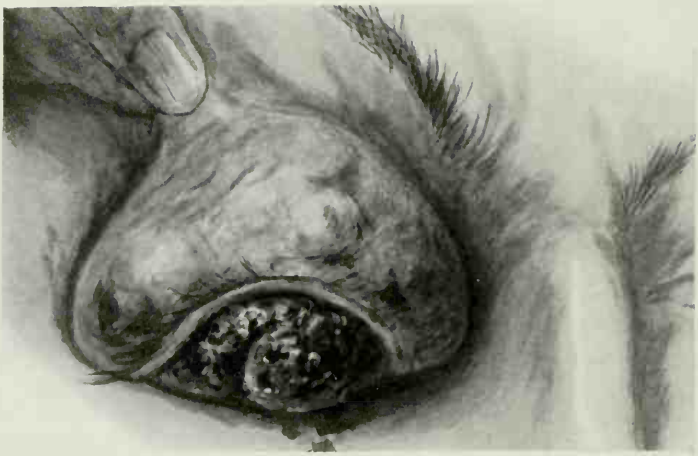

Fig. 2.—Lids everted, showing lobulated mass.

A CASE OF LARGE ROUND-CELL SARCOMA OF THE UPPER EYELID

C. E. G. SHANNON, M.D.
Philadelphia, Pa.

The patient, a woman, aged eighty years, visited the Eye Department of the Jefferson Hospital November 11, 1922, suffering from an extensive growth in the upper lid of the right eye. Two years prior to her visit to the hospital she noticed a small tumor at the center of the margin of the upper lid, which increased slowly in size, and at the end of twelve months was about as large as a filbert. At this time a surgeon removed the growth. Three months later the tumor recurred and grew rapidly, and in nine months had reached the size of a walnut. Examination showed the skin surface of the lid uneven, slightly swollen, and of a dark-red color, with numerous dilated veins beneath the skin (Fig. 1). Eversion of the lid exposed a large lobulated mass with roughened bleeding surfaces, which extended from the margin of the lid up to and including the upper culdesac and laterally from the inner to the outer canthus. The globe was apparently uninvolved, although the cornea showed rather extensive scarring (Fig. 2). Vision equaled light perception; no view of fundus.

A small piece of the growth was removed for pathologic study, and *x*-ray treatment was advised, but, unfortunately, could not be carried out by reason of the serious illness of the patient for nearly six months. On her return to the city in April, 1923, the growth had increased so markedly that immediate operation was imperative. Under local anesthesia the entire growth was excised without disturbing the skin surface of the lid. No attempt was made to plant grafts on the exposed raw surfaces. The patient made a rapid convalescence. Up to the present time there has been no recurrence nor any evidence of metastasis.

Family history negative. Physical examination reveals no evidences of malignant growths in other parts of the body.

Report by Dr. B. L. Crawford, Jefferson Medical College Laboratories, is as follows: "Specimen consists of a soft, dark-red,

nodular piece of the tissue, weight 10 gm. It appears to be encapsulated. On section the substance is soft and presents a mottled appearance, dark-red areas alternating with gray areas. Zenker's fixation.

"Histology. Sections show the mass of tissue to be composed largely of a solid mass of tumor cells with very little intracellular substance. The tumor cells vary slightly in size and shape, but the majority are large cells with round or oval granular nuclei, many of which show mitosis. The tissue is very vascular, the walls of the vessels are thin, and extensive hemorrhages have occurred in places." Diagnosis: Large round-cell sarcoma.

Sarcoma of the eyelids is comparatively rare. In 1919 Schiller,[1] following an exhaustive search in the literature, found only 109 cases recorded, of which 67 were leukosarcoma and 42 melanosarcoma. Rschanitzin[2] states that Sgrosso found among 16 tumors of the lids 12 carcinomata and 3 sarcomata; Truc, among 55 cases, 11 carcinomata of the palpebral conjunctiva and 3 carcinomata of the bulbar conjunctiva, but no sarcomata. Rschanitzin, in his collection of 250 cases of malignant growths of the lids from 1870–1908, found 149 that were carcinomata and 103 sarcomata. Their infrequency is further emphasized by the fact that among 520,523 eye cases Gross[3] saw only 3 of lid sarcomata; Verhoeff[4] among 44,719 cases saw only 2 lid sarcomata, and von Bortheu[5] among 15,000 cases saw 8.

Sarcoma of the lids, as shown by the above figures, is far less frequent than carcinomata. Nagel's report for the years 1870–1913 notes 218 cases of carcinomata of the eyelids, of which 194 arose from the skin of the lid and only 24 from the lid conjunctiva. We may assume, furthermore, that many cases of carcinomata of the lids had not been reported by reason of the great increase of reported cases since the introduction of *x*-ray and radium.

The origin of malignant tumors in many instances is found in the richly vascular limbus conjunctivæ. Koeppel[6] in 1908 found among 55 cases 34 that were from the bulbar conjunc-

tiva, 8 the plica semilunaris and caruncle, and 13 the palpebral conjunctiva. Rarely do these growths develop on the skin surface of the lid. Schiller found it 3 times among 53 cases of leukosarcomata and 7 times in melanosarcoma. One case is noted as having its origin in the lacrimal gland and one from the lacrimal sac. Occasionally, as in the case presented, it arises in the tarsal tissues, simulating a chalazion which tends to recur following removal. The diagnosis may be made without difficulty in this type, as a true chalazion is situated in the tarsus, while the sarcomatous growth is freely movable over it.

In regard to the time of life in which the pigmented and unpigmented forms of sarcoma are usually found, the following comparative figures prepared by Schiller are of interest: In 53 cases of unpigmented sarcomata, up to ten years of age, there were 15 cases, or 28.3 per cent.; from ten to twenty years, 9 cases, or 16.9 per cent.; from twenty to thirty years, 5 cases, or 9.5 per cent.; from thirty to forty years, 5 cases, or 9.5 per cent.; from forty to fifty years, 5 cases, or 9.5 per cent.; from fifty to sixty years, 4 cases, or 7.5 per cent.; from sixty to seventy years, 6 cases, or 11.3 per cent.; from seventy to eighty years and above, 4 cases, or 7.5 per cent. In 31 cases of the pigmented form, 4 were noted from thirty to forty years of age, 3 from forty to fifty, 6 from fifty to sixty years, 9 from sixty to seventy, 5 from seventy to eighty, and 4 above eighty. From these figures it is evident that leukosarcoma is more distinctly an incidence in youth, the youngest case being ten months old. Melanosarcoma, on the other hand, is more frequently found in advanced life. The site of leukosarcoma was more often noted in the upper lid and melanosarcoma on the lower lid. In some cases the involvement of both lids has been reported, rendering it difficult to determine whether the growths were multiple primary sarcomata or cases of metastases. Fifteen such cases were noted by Schiller in his collection.

Microscopically we find among the constituents of the tumors small and large round cells, spindle cells, and giant cells.

Exclusive giant-cell leukosarcomata have been reported in a few cases. Round-cell leukosarcoma, however, is frequently seen. Reference should be made, moreover, to the occasional finding of epithelioid- and endothelioid-cell sarcomata and angiosarcomata. Among the melanosarcomata noted by Schiller were found ten round-cell and eight spindle-cell sarcomata, and nine cases showing both cell forms and one giant-cell sarcoma. De Schweinitz and Shumway[7] reported in their collection of cases 45 per cent. of round-cell and 40 per cent. of spindle-cell, and the rest mixed. The size of the tumor may vary from the size of a pin-head to that of an orange. The color varies from bright pink to reddish, or, in the presence of pigment, reddish-brown to black. Coincident with the development of the pigmented sarcomata there is frequently found some pigmentation of the surrounding conjunctiva. This peculiar pigmentation of neighboring or distant parts, as is shown in Roper's case, where there were coincident pigment nodules of the face, lips, and skin of back, might suggest that the same tendency to pigmentation in the sarcomatous growth was responsible for the pigmentation in those other areas.

The incidence of sex apparently plays no part in the etiology. Trauma may be considered a causal factor. Schiller in his collection found 10 with a distinct history of trauma. Weinsteiner[8] avers that trauma is frequently the cause of sarcomata, as the site of the growths is far more frequently found in the neighborhood of the commissure of the bulbar conjunctiva, the plica semilunaris, and the caruncle than on the lid conjunctiva.

Chronic inflammation may also be followed by sarcomata. Three cases are shown in which trachoma apparently was the cause.

The prognosis of sarcomata of the lids is unfavorable, although less so than in other parts of the body, as they are generally operated upon during the early stages. There is, however, a tendency to rapid recurrence and metastasis. It is shown that in the non-pigmented type 40 per cent., and in the pigmented type 37 per cent., recur.

Emmanuel[9] claims that there is a recurrence in approximately 66 per cent. In children the prognosis is especially unfavorable. In ten deaths recorded eight were during childhood. The growth recurs more frequently in these cases and spreads rapidly to the orbit, with marked tendency to metastasis, but seldom penetrates the globe.

With the development of the tumor the entire lid may be affected, and later the neighboring structures, such as the jaw, temple, and other lid, and even the brain. By reason of this extensive invasion the patient usually succumbs.

TREATMENT.—In view of the marked tendency to recurrence, early operative interference is admissible. If section of the growth shows the presence of tumor cells in the blood-vessels, exenteration of the orbit may be necessary. Four or five years must elapse before a recurrence is considered unlikely. *X*-ray and radium treatment of sarcoma of lid is still in an experimental stage.

REFERENCES

1. Schiller: Über Sarkome der Augenlider, Zeit. f. Augenhk., xlii, 1919, p. 302.
2. Rschanitzin: Zur Kasuistik der Rundzellen-Leukosarkome der Bindehaut, Klin. Monatsbl. f. Augenhk., xlvii, S. 167.
3. Gross: Primary Epibulbar Melanosarcoma.
4. Verhoeff: l. c.
5. Von Bortheu: l. c.
6. Koeppel: Ein Fall von Melanosarkom der Bindehaut, Dissert., Jena, 1900.
7. de Schweinitz and Shumway: Annals of Ophth., 1911, p. 652.
8. Wintersteiner: Beobachtungen und Untersuchungen über den Naevus und das Sarkom der Konjunktiva, Ber. über die 27. Vers. der ophthalm. Ges., Heidelberg, 1898.
9. Emanuel: Klin. Monatsbl f. Augenhk., xlvi, 1, S. 539.

EXHIBITION OF CASES, NEW INSTRUMENTS, AND APPARATUS

THERMOPHORE

Dr. W. E. Shahan demonstrated the method of applying the thermophore referred to in his contribution on page 151.

TUBERCULOSIS OF THE EYE

Dr. William C. Finnoff exhibited rabbits with ocular manifestations resulting from the injection of dead tubercle bacilli. One showed a lesion of the iris; one a lesion of the cornea; another had atrophic spots on the iris following a previous tuberculous iris, while two others had choroidal lesions.

VARIATIONS IN THE PRIMARY INSERTIONS OF THE OCULAR MUSCLES

Dr. Lucien Howe presented a series of dissections of the extraocular muscles of 13 eyes, showing their primary or principal insertions, that is, without the fibrous extensions or *adminiculum tendinis* of Merkel. Also, a corresponding number of charts on which these insertions were magnified and plotted to a scale. The charts showed at a glance the very decided variations which occur in different individuals in the insertions of these muscles. The greatest variations are in the insertion of the inferior oblique. In no two eyes were these exactly the same, either as to position or in the form of the line of insertion. Such differences may account for the diversities in pathologic conditions which we find clinically and for the various results obtained when the same operation is made on different individuals.

GLIOMA OF RETINA

Dr. Edward Jackson, in demonstrating slides characteristic of glioma of the retina, referred to the difference in staining qualities of cells that are near to or removed from the vessels, their grouping, and their relation to the tissues of the eye. He pointed out the poor staining of cells far removed from their base of supply.

The general appearance of glioma of the brain is entirely different. Secondary glioma is practically the same in appearance as small-cell sarcoma.

DEMONSTRATION OF PATHOLOGIC SLIDES

Each demonstration limited to ten minutes

SIDEROSIS BULBI

BROWN PUSEY, M.D.
Chicago

The sections shown are from an eyeball which had contained a small splinter of iron for eighteen months before the eye was enucleated, the iron being located at the equator of the eyeball and embedded in the retina, choroid, and sclera.

Sections were stained to show the Prussian-blue reaction for iron.

The lining cells of the ciliary body and ciliary processes, the anterior epithelial cells of the lens, the iris, and the spaces of Schlemm's canal, all contained iron. The retina showed much iron, a striking finding being the affinity of Henle's fiber layer for iron.

There was no iron in the ciliary body or within the ciliary processes and none in the choroid. The optic nerve and the perivascular lymph-spaces of its blood-vessels were also free.

DISCUSSION

Dr. Nelson M. Black, Milwaukee, Wis.: I would like to ask Dr. Pusey if that spot beneath the capsule of the lens is an iron deposit?

Dr. Pusey: No, it is tissue stained with iron.

Dr. Black: The specimen shows equidistant spots around the periphery of the lens, which is pathognomonic of iron or steel in the eye, according to Parsons.

In discussing the report of a case before our local (Milwaukee) Society one of our young men (Dr. F. Herbert Hassler) gave an

ingenuous explanation as to the deposition of these spots seen around the periphery of the lens. I asked him to write it out for me, and this is his explanation:

"It has been shown that these dots are clumps of proliferated capsular epithelium impregnated with iron. With slit-lamp illumination it is possible to see in each of the surfaces of optical discontinuity of the lens a system of radial, dichotomously branching lines which represent junctions of the several sectors of the lens. It seems likely that each line is actually a minute groove, and that there is a slightly larger concavity at points of branching, brought about by the looser apposition of lens fibers at the junctions of sectors than within each sector.

"In siderosis the iron is probably a stimulus to proliferation of the epithelial cells of the capsule. However, there is only room for proliferation in the concavities (which in my hypothesis are assumed to exist) at the points of branching of the lines of the lens star. At all other points the pressure between capsule and lens substance prevents proliferation. A similar situation exists when the corneal epithelium proliferates into a concavity produced by a small ulcer, as illustrated by Fuchs in his Bowman lecture. Vogt has observed a large number of normal lenses *in vivo* and has found that there are 6 to 10 primary lines in the lens star and 10 to 16 secondary branches. There are usually 10 to 14 dots in a siderotic lens.

"It would be interesting to observe some cases of siderosis with the slit-lamp to see whether the dots are always situated at a point of branching in the lens star."

A CASE OF EXTENSIVE TUBERCULOSIS OF THE EYEBALL

W. GORDON M. BYERS, M.D.
Montreal, Canada

John H., a sailor, aged twenty years, was referred to me on September 28, 1921. The man stated that the sight of the right eye had begun to blur six weeks previously. He was quite positive that he could see perfectly on that side up to that time. There was a good deal of pain at first, but this gradually lessened. The vision, on the other hand, rapidly diminished.

On examination one noted a slight proptosis (2 mm. with the exophthalmometer), but no restriction of movements. There was marked circumcorneal congestion, not only of the superficial and deep episcleral vessels, but of numerous arborescent branches of the posterior conjunctival group. Beneath the congestion one saw a band of bluish discoloration, 4 to 5 mm. in breadth, rimming the entire cornea. Between five and seven o'clock this band was raised a couple of millimeters above the surface of the sclera. The whole cornea was markedly vascularized. Numerous radicles of the posterior conjunctival group ran forward superficially, a few of them penetrating as far as its center; while ciliary vessels, more deeply placed, spread fan-like from the periphery to the middle. There was a pronounced general haziness of the cornea, but one could see quite plainly that the anterior chamber was occupied by an extensive buff-colored exudation. This consisted of one large uniform mass that covered the lower two-thirds of the iris, and of several smaller clumps irregularly distributed over the upper third of the iris. The exudation was most pronounced over the pupillary area. Vision = No p. l. T. — 1, at least.

A thorough systemic examination revealed only a chronic rhinitis; slight enlargement of the tonsils; and a shadow at the apex of one tooth. But the teeth and tonsils were considered very doubtful sources of infection. *X*-ray plates of the chest and of the accessory sinuses were negative. Venereal infections were carefully excluded. As this point is of great importance, the report of the urologic department is given *in extenso:*

"There is no history of any venereal infection; and no symptoms to indicate any urologic disease. Examination: Penis normal conformation; no scars. Urethra, no evidence of urethral discharge or chronic or acute inflammation. Patient voids with fair-sized and free stream. Scrotum and contents normal, except for a varicocele of the left pampiniform plexus. Prostate is of moderate size, soft, not nodular or tender. Prostatic fluid is normal. Smear of prostatic fluid shows no pus or other pathologic elements. Complement fixation for gonorrhea negative; Wassermann negative."

The patient was given, at intervals, ½ and 1 mg. of O.T., with negative results; but he responded generally, locally, and quite definitely in a focal way to 2 mgm. O.T. In performing the enucleation (October 11, 1921), an effort was made to keep the

conjunctival incision behind the inflamed episcleral zone. At the time it seemed as if one had excised all diseased tissue without encroaching too much on the conjunctival sac. Recovery was uneventful. Although the patient has since been written to at the only address given, no reply has been received to our note of inquiry.

The eyeball was hardened in formalin. Complete sections were cut in celloidin, while paraffin sections were made of smaller portions. Some of these latter were stained to bring out cell characteristics, and some for tubercle bacilli. It may be said here, however, that though a large number of sections were carefully searched, no tubercle bacilli could be found.

Pathologic Examination

For the sake of clarity and convenience I shall reverse the usual order of things in describing this specimen. The ground can be cleared at once by saying that the optic nerve and choroid are normal throughout.

The retina shows a complete, lily-shaped detachment. It is greatly swollen and thrown into innumerable folds. Microscopically one sees pronounced edema, especially of the three innermost layers. The retinal vessels are engorged; but there are few hemorrhages, apart from one large extravasation in the apex of the detachment in front of the optic disc. The retinal structures stain palely and are obviously in process of degeneration. The two innermost layers are markedly infiltrated by lymphocytes. A relatively small number of these cells are found over, and immediately behind, the posterior surface of the retina; but there is little or no subretinal exudation. The anterior surface of the retina, on the other hand, is covered with a marked layer of granulation tissue, which varies considerably in thickness. This granulation tissue shows different stages of development; in some places it is largely cellular in character; in other places, of the nature of well-developed fibrous connective tissue. The folding of the retina is obviously due in part to the contraction of this organized layer. It can be seen at times to bridge the gaps between retinal folds. The granulation tissue is especially marked in the angle at the ora serrata, where the retina extends almost vertically outward from the choroid. In this locality particularly, but occasionally elsewhere over the surface of the retina, one sees definite tubercle formations as presently described. These are uniformly, however,

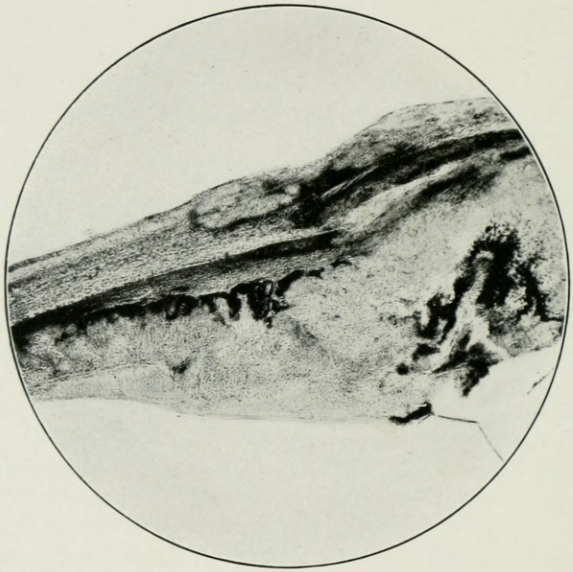

Granulomatous mass over the surface of the ciliary body and in the chambers of the eye; and the line of extension, outward to episcleral nodules, and forward into the substantia propria of the cornea.

of recent development, and are found only in the granulation tissue.

Some little distance in front of the retina the hyaloid membrane of the vitreous, apparently everywhere intact, runs saggingly from one side of the eyeball to the other. It is thickly covered, and in places entirely obscured, by a large number of lymphocytes and disintegrated cells.

The anterior chamber in its entirety, except at one point that would correspond to the upper limit of the space, is occupied by a dense granulomatous mass (see illustration) which, involving the iris, extends backward along the surface of the ciliary body on either side as far as the ora serrata. The mass entirely surrounds the anterior surface of the lens, but does not extend backward into the vitreous beyond a line that would correspond to the posterior surface of the lens and the innermost of the fibers of the zonular ligament. The iris is entirely involved and lost in the process. Only an irregular line of greatly multiplied pigment cells marks its posterior layer. The longitudinal bundles of the ciliary muscle are spared in great measure, but the circular fibers, the ciliary processes, and the surface of the ciliary body throughout are likewise obliterated. The suprachoroidal space exterior to the ciliary body is markedly invaded.

This extensive infiltration has all the ear-marks of a tuberculous granuloma. Dense aggregations of lymphocytes, staining deeply, alternate with areas in which all formation is lost, and with nodules in which giant cells, epithelioid cells, and lymphocytes are arranged in the usual typical manner.

The sclera is normal except in an anterior portion lying between the corneoscleral junction and the termination of the ciliary body. The scleral tissue is densely infiltrated by lymphocytes that lie between, but for the most part alongside of, vessels, some of which can be seen to communicate with others situated in the episcleral tissue. The cells throughout this area stain uniformly and deeply. There is no tendency to caseation, and no giant cells can be noted. The vessels in the area extend backward well toward a point that would correspond to the termination of the ciliary body; in front they stream forward into the substantia propria of the cornea.

The vessels over the whole surface of the sclera are engorged, but this engorgement becomes increasingly pronounced in front of a point corresponding to the ora serrata within. Between this point and the limbus the episcleral tissues show an intense peri-

vasculitis and cellular infiltration with numerous cell aggregations or nodules. These nodules are of varying size. A number of them are entirely contained within the episcleral tissue, but more of them have infiltrated, and rest also in, the substance of the sclera. Some of the nodules are made up almost exclusively of lymphocytes which take on a uniformly deep stain; but most of them stain palely and show epithelioid cell proliferation, connective tissue, and giant-cells in typical arrangement.

The corneal epithelium is everywhere intact. In the anterior two-thirds of the substantia propria numerous vessels are seen toward the periphery, but they penetrate for a short distance only. Rarely one meets with a vessel that has advanced as far as the center of the cornea. In the posterior third of the cornea the picture is quite different. The substantia propria here is richly invaded by vessels throughout its entire extent. These vessels are composed merely of a single layer of endothelial cells. Along their course are dense aggregations of lymphocytes staining deeply; but in no part of the cornea is there any approach to typical tubercle formation. Generally speaking, there is an increase in the cellular elements of the cornea proper. At several points where the cornea comes in contact with the granulation mass Descemet's membrane has entirely disappeared, and the posterior layers of the cornea are completely involved in the process. One sees this particularly well with paraffin sections, in which it is impossible to make out any definite line of transition.

Comment.—The tuberculous nature of this case is not to be doubted. The exclusion of any definite focal infection and of specific disease, on the one hand, and the general, local, and focal tuberculin reactions, on the other, are virtual proof from the clinical side alone. On the pathologic side the histologic changes within the globe are entirely characteristic. There only lacks in the evidence the demonstration of tubercle bacilli, but it is well known that it is often impossible to find the organisms under similar conditions.

In regard to the sequence in which the various structures within the eye were involved, there would seem to be little question. Judging from the destruction of parts and the variations in character of the infiltration, one would say that

the process had had its point of origin in the iris—probably in the vicinity of the circulus iridis major—and had extended to the rest of this structure and to the anterior part of the ciliary body. From this latter point extension occurred along the ciliary processes to the retina, and along the course of the anterior ciliary vessels (largely) and Schlemm's canal to the sclera and episcleral tissue. The highly cellular character of the changes in the cornea—the absence of anything approaching caseation—compels one to regard infiltration of this structure as the latest phase of the disease. The cornea was certainly involved in two ways: by extension of the process from the sclera in association with the newly formed vessels, and by direct penetration of the granulation tissue occupying the anterior chamber.

One might picture this specimen as being a second stage in a cycle of events somewhat as follows: In the first phase[1] one sees tuberculous nodules involving the periphery of the anterior chamber and the root of the iris. In my case extension has taken place to the ciliary processes and retina, on the one hand, and to the sclera and episclera, on the other hand, without, however, any appreciable caseation in these latter structures. A third stage is depicted by this specimen from the collection of my colleague, Dr. MacMillan, in which the sclera is completely involved with caseation and marked ectasia. In the final picture[2] the sclera will have been perforated with the formation of a granulating tuberculoma on the surface of the eyeball. Strictly speaking, perforation has taken place here through the cornea, but the lantern slide was in my collection so I brought it along to illustrate the point.

It is noteworthy how fully the tuberculous process is confined to the anterior segment of the eyeball. One has here a clinical demonstration of the meagerness of the vascular (lymphatic) connections between the ciliary body and choroid.

In a purely mechanical way the retina, the hyaloid mem-

brane of the vitreous, and the zonular fibers play an equally important part in this delimitation. In other cases the retina and hyaloid membrane act as obstacles to the progress of disease from behind forward. This slide[3] shows these structures backed by a fibrous membrane stretching across the ciliary region, forming the anterior confine of a mass that fills the whole vitreous cavity. In this specimen[4] they have helped to bar the way, while perforation has actually occurred through the dense sclerotic.

It is interesting to note that the changes described occurred apparently within a period of two months. While by no means without parallel in the literature, the rapid progress in this case was an interesting and striking clinical feature. There is no reason to believe that secondary infection played any rôle in the process.

REFERENCES

1. Collins and Mayou: Text-book of Pathology, illustration, page 393.
2. Parsons: Pathology of the Eye, vol. 1, illustration, page 298.
3. Collins and Mayou: Text-book of Pathology, illustration, page 402.
4. Parsons: Pathology of the Eye, vol. 2, illustration, page 466.

DISCUSSION

Dr. William C. Finnoff, Denver, Colo.: About two years ago I saw such a case as Dr. Byers describes. The anterior chamber was full of tuberculous areas; the ciliary body on one side had marked degeneration and caseation. Epithelioid and giant-cells were seen in an atrophic area at the sclerocorneal juncture that had undoubtedly gone through the venous spaces at the limbus. The clinical history was practically the same as Dr. Black's case; there was no detachment of the retina in this case.

Experimentally, I have observed the passing of infection from the interior of the eye through the limbus in the region of the venous spaces to the outer part of the eye.

PERSISTENT HYALOID ARTERY

WILLIAM C. FINNOFF, M.D.
Denver, Colorado

The right eye was enucleated because of a perforating injury. The eye had not been examined before the accident. The vision, as far as the patient could recall, was normal.

The microscopic section of the eye shows a perforating wound in the region of the limbus. The wound is filled with granulation tissue and the surface is covered with epithelium. The base of the iris is torn from the ciliary body on the side corresponding to the wound.

The anterior chamber is filled with a serous exudate. The iris is thickened because of edema, and the stroma is slightly infiltrated with polymorphonuclear leukocytes, lymphocytes, and plasma cells. The lens capsule is perforated and most of the lens substance has been absorbed. The ciliary body on the injured side is swollen and polymorphonuclear leukocytes, lymphocytes, and plasma cells are present in the vascular layer. A cyclitic exudate, which is undergoing organization, fills the posterior chamber on the injured side and extends inward along the posterior lens capsule.

The retina is in contact with the choroid. The retina and choroid are edematous.

A persistent hyaloid artery runs forward 1 cm. from the surface of the disc. The vessel is partially filled with blood and communicates with the central retinal artery at the disc. Several layers of glial cells cover the vessels. The glial cells are continuous with those of the retina and disc.

OSTEOMA OF THE ORBIT

ARTHUR J. BEDELL, M.D.
Albany, N. Y.

Osteoma of the orbit, according to Parsons, has been recorded since 1506, when Veiga reported his experience. Since that time many observations have been made. Lediard described a case in which a nine and a half ounce tumor protruded between the upper lid and eyebrow causing a rupture of the globe and finally extrusion of a mass which measured 4½ by 5 inches. Hilton saw a fourteen and three-quarter ounce osteoma which, after destroying the eye by pressure, was spontaneously expelled. A tumor which weighed 351 grains was seen by Stevenson. Cooper reported a bilateral orbital exostosis which seemed to come from the antrum and which by extension into the cranial cavity produced sufficient vascular change to cause an apoplexy from which the patient died. Middlemore also referred to a large osteoma.

To attempt the complete report of literature would be time consuming and serve little good. Several citations have been made by members of this Society. The first case so presented was by Norris in 1884. The growth springing from the floor of the right orbit produced optic atrophy with blindness. The eyeball and tumor were removed. Recovery was good.

In 1890 Pooley removed a large osteoma and preserved the eyeball. This was in a girl of twenty-three years, in which the mass filled the upper inner angle of the orbit. The eye projected outward and somewhat upward, there was marked limitation of motion, especially in and down. There was an associated optic neuritis. Vision = 20/200. An incision was made in the brow margin and carried along the side of the nose. The tumor was chiseled free, dislodged, and on removal

weighed 26 grams. Reeve, in discussion, stated that he had removed an osteoma which came from the frontal sinus and the patient recovered with full vision.

Sattler referred to a case in 1896. His patient, a male, twenty-five years old, had a tumor near the upper and inner margin of the right orbit which caused an enormous degree of exophthalmos. The globe was turned outward, downward, and forward. The growth, hard and nodular, weighed 15.3 grams. Recovery following operation was uneventful.

The year following Sattler's presentation, 1897, Norris cited the case of a male, aged twenty-four years, who had a tumor in the nasal wall of the right orbit, which had existed for six years, causing severe headache with dizziness and diplopia, but without other interference in vision. The osteoma removed by him weighed 258 grains.

In that same year Sattler supplemented his report of the year preceding.

In 1898 E. Fridenberg operated on a case in which a mass protruded from the center of the superior orbital margin, pushing the eye backward and downward. When removed, it measured 31 by 25 by 20 mm.

In 1903 Percy Fridenberg detailed his experience with a twenty-one-year-old man whose eye protruded and was dislocated outward and downward without, however, interference with globe motility. Incision was made along the orbital ridge below the brow, a tumor was removed measuring 29 by 14 by 4 mm. and weighing 100 grains. When the osteoma was freed, there was a small amount of muco-pus which welled from the ethmoid attachment. The patient made a good recovery.

In 1911 Sweet gave an account of the case which had been recorded by Norris in 1897. The patient had an antrum infection and was operated upon successfully. Veasey, in 1915, showed x-ray pictures and gave the clinical history of a case which, however, was not operated upon.

Herman Knapp, in the Archives of Ophthalmology for 1880, reported a cure and detailed the operation for the removal of a 36 by 29 by 24 mm. osteoma.

Andrews, in 1887, in a most comprehensive article, reviewed the literature up to that time and reported the histories of two new cases.

Jackson, in 1892, presented a report before the American Medical Association of the successful removal of a 13 gram osteoma from the orbit with the preservation of vision.

Arnold Knapp, in the Archives of Ophthalmology for 1906, illustrated and reviewed two cases operated upon by him. In one, the tumor measured 2 by 3 cm. and was located deeply in the orbit; the other was 4 by 2 cm., weighed 5.15 grams; in both recovery was complete.

Blake, in the Ophthalmic Record for 1913, reported a huge osteoma of the orbit. He stated that the tumor was the size of a closed fist, and came from the left frontal sinus. He advised against operation. The patient was operated upon by a general surgeon and died on the table.

From this synopsis of the cases reported by members of this Society or before this Society, it is evident that experience with this type lesion is not unusual. Lagrange, in 1904, collected 148 cases. The older writers seem to have been cognizant of the condition and yet must have been fearful of the outcome, as is shown by the report of the very large growths, notably those by Lediard and Hilton. LeMond says that in 60 per cent. of these cases death follows operation. Lagrange, however, feels that 6 per cent. is nearer the present truth, although Cumston considers the mortality to be 10 per cent.

Because the disease presents certain curiosities in the form of development, in the length of time individual cases are under observation, and in the end result, the following experience is reported in detail.

E. L., aged seventeen years, was referred by Dr. Frank B. Wheeler, of Hudson, N. Y., with a history that a week ago he had had some pain with headache localized around the left side. Three days later there was redness of the left eyeball and lid conjunctiva, followed in a few hours by an increased prominence of the globe.

First examination made October 2, 1922; right eye, pupil 4 mm., slightly oval, but reacted promptly to light and accommodation. Cornea and media clear, disc distinctly outlined. No limitation of external motion.

The left eye showed an extreme edema and congestion of the entire orbital region with marked exophthalmos. The globe was 11 mm., more prominent and slightly lower than the right, with motion limited in all directions, practically abolished upward. There was a firm, subperiosteal, nodular protuberance to the upper and inner side of the orbit. To the temporal side of the upper lid there was fluctuation. Pupil 5 mm., regular and active; media clear, disc distinct, venous engorgement. The diagnosis of osteoma with secondary orbital abscess was then made.

Under ethyl-chlorid general anesthesia an incision was made through the fluctuating area. There was a considerable amount of glairy muco-pus with no change in the contour of the nasal side of the orbit. Hot compresses caused the inflammatory symptoms to subside and he was told to return when the lids were white, at which time an operation would be performed to attempt the removal of the bony growth.

The *x*-ray showed an intense shadow in the upper and inner portion of the orbit, extending well into the orbital cavity and leaving but a thin layer of bone between it and the dura. The frontal sinuses were large, clear, and easily outlined.

Nine days after draining the orbit the left eye was 3 mm. more prominent than the right and remained markedly divergent as well as 5 mm. lower.

On October 26, 1922, he was given ether and the skin cleaned but the eyebrow was not shaved. An incision was started in the outer third of the left eyebrow, carried across to the nose and then downward along the side of the nose, going through the periosteum. All of the soft tissues were dissected with the periosteum, uncovering a large, nodular mass and draining about 14 drops of glairy, greenish-brown muco-pus from the deepest point of the growth's attachment. The bone growth was so large, so irregular, and so

placed, being attached to the posterior ethmoid, that it was impossible to chisel it loose. The ethmoid plate was then separated and removed with the tumor, which was done by chiseling all around the dense bone attachment. The mass was finally rocked free, holding it with heavy Volsella. The point of attachment was irregular in outline, its greatest diameter being 12 by 11 mm. There was on its surface an almost perfectly round channel 2 mm. in diameter, with overhanging bony lips, through which the glairy mucus came from the ethmoid cells. The specimen weighed when dry 16.173 grams and measured 35 by 30 by 17.5 mm. A narrow strip of vioform gauze was placed in the depths of the wound and the skin closed with silk sutures. Rolls of plain gauze were placed over the upper and lower lids and a firm pad applied over the eye. This dressing was held in position by a flannel bandage. Two days later the packing was removed, skin union was primary, and the eyeball freely movable in all directions. The temperature never reached 99.5° F., and there was neither local nor general reaction.

November 8, thirteen days after operation, the eyeball was in the same position as its fellow. The vision was 20/15 and disc clear.

Smears made from the mucous discharge showed many polymorphonuclear cells without organisms. The cultures made at the same time showed no growth after four days.

We have been able to observe the boy's face by means of old photographs for several years, and even as late as 1920 there was no gross marked defect. Careful inspection of a picture made in 1921 showed that the left eye was more prominent than the other and divergent. In the consideration of his history we note that he has been mute since birth, although no other member of the family has been so afflicted. He has had whooping-cough, chicken-pox, typhoid fever, and measles. Wassermann reaction negative.

His ears show marked retraction of clean, thin membranes. He has no air conduction, but the low and middle tones are heard through bone, and his voice is typical of one who has never had hearing. The nose shows a septum deviated to the right and large middle turbinates. At no time while under observation has he had a purulent nasal secretion.

It seems striking that although the osteoma was found to occupy a very large portion of the orbit the patient was never conscious of annoyance until acute inflammatory symptoms drew his attention

Fig. 1

Fig. 2

Fig. 3

Fig. 4

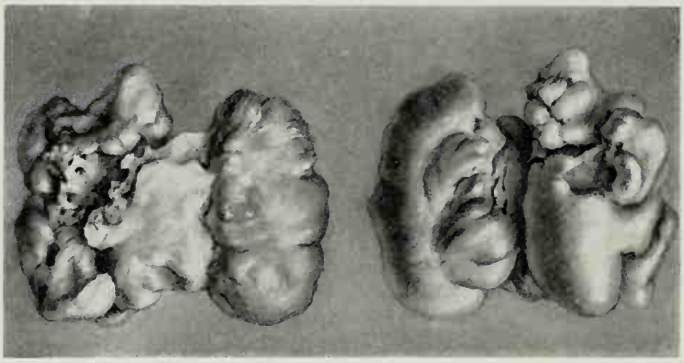

Fig. 5

Fig. 6

Fig. 7

to the condition. Although the left eye was decidedly prominent, on a lower level, and divergent, he never complained of diplopia. He was never injured, and as far as he knows never had an acute sinus involvement. The most careful and prolonged questioning failed to disclose any responsible factor for his disease.

The examination of photographs made before operation gives some impression of the acute inflammatory reaction as evidenced by the markedly swollen eyelids and also the divergence, which, although the eyelid is left in position, can be easily seen.

The result justified operation, first, because of the marked change in the appearance; second, because of the known nature of the growth to increase in size; and third, because there was sufficient inflammatory reaction to make it certain that it was only a question of time before he would have another acute orbital infection.

DISCUSSION

DR. C. A. VEASEY, Spokane, Wash.: In 1916 I reported before this Society the history of a case of an unusually large osteoma of the frontal, ethmoidal, and sphenoidal sinuses involving the orbit and anterior cerebral fossa, presenting no subjective symptoms other than proptosis of the eyeball. At that time I showed the skiagraphs and photographs of the patient, who was a female, aged thirty years, and who had first observed proptosis eleven years before my examination. This proptosis had been increasing very slowly during that period. Indeed, it may have existed longer than eleven years, because seventeen years before consulting me she had been taken to an oculist in Kansas City because of a so-called "enlargement of the right eyeball." There was no family history of tumors of any kind. She had been married for several years and enjoyed comparatively good health, and excepting an occasional dull, aching pain in the eyeball, presented no subjective symptoms whatever because of the conditions that existed. The vision and accommodation were normal. The optic nerve of the proptosed eye was slightly paler than normal, but there was no indication of any preëxisting neuritis.

There was an enormous bony growth in the upper inner portion of the orbit which could be distinctly felt with the fingers. It extended transversely from the region of the ethmoid about half way across the roof of the orbit to the temporal side, and in depth

it passed backward toward the apex of the orbit as far as the finger could feel.

The nasal and skiagraphic examinations seemed to show involvement of the frontal, ethmoidal, and sphenoidal sinuses, as well as the orbit and the anterior cerebral fossa, the cerebral involvement being so extensive that it was not thought wise to attempt any operative procedure.

Since the report of this case, this patient was again seen in 1917, when the eyeball was found more proptosed, but still retaining its power to rotate in all directions and without any diplopia or paralysis. There was at this time a low grade optic neuritis in the eye, with vision reduced to 6/12, but very little headache.

The patient was next seen in 1921. There was now greater proptosis, together with a prolapse of the lacrimal glands and intense headache. Vision was still 6/12, and the outer half of the nerve of that eye was completely atrophic, but the inner half was still pink, the line of demarcation cutting the nerve directly in half. A decompression operation was now advised, but declined. I have with me a set of stereoscopic plates which show the condition most beautifully, if any of the members feel sufficiently interested to examine them.

A CASE OF ADENOCARCINOMA PROBABLY ARISING FROM THE LACRIMAL GLAND

LEE MASTEN FRANCIS, M.D.
Buffalo, N. Y.

At the last meeting of the American Academy of Ophthalmology and Oto-Laryngology the reader reported a case of malignant lymphoma of the lacrimal gland to which a complete bibliography was appended. In that paper free reference was made to a contribution by Laura A. Lane in volume v, No. 6, of the American Journal of Ophthalmology, in which the entire subject of lacrimal gland tumors was thoroughly summarized and painstakingly reviewed. Dr. Lane pointed out that only 229 cases had been reported in three hundred and twenty-three years. In her statistics, adeno-

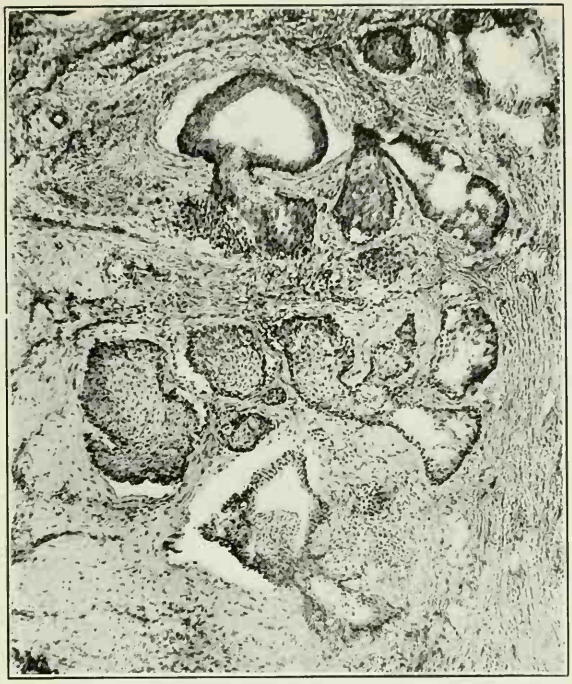

Fig. 1.—Microphotograph of frozen section of material from distal part of lid showing tarsal gland structures—normal.

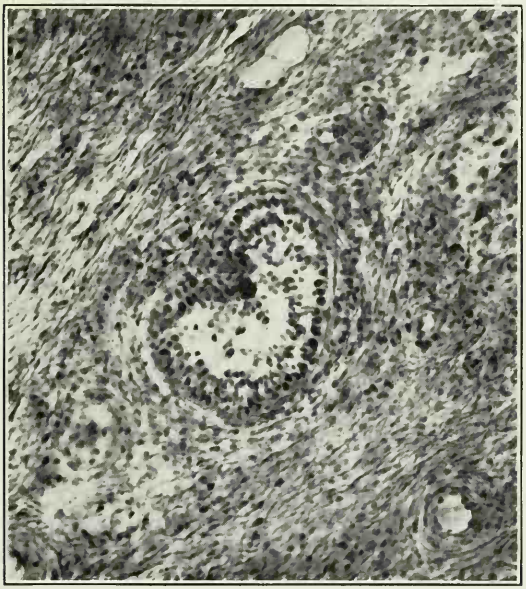

Fig. 2.—Duct showing beginning hyperplasia, with numerous acini in its neighborhood—resembling fibro-adenoma of breast.

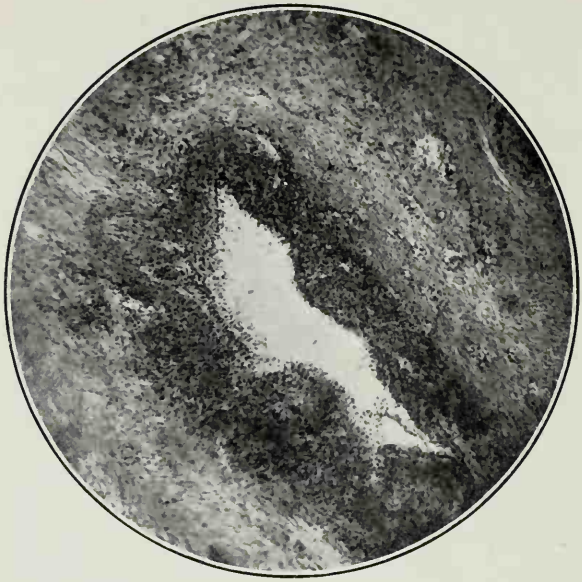

Fig. 3.—Dilated duct surrounded by masses of epithelial elements arranged in acini.

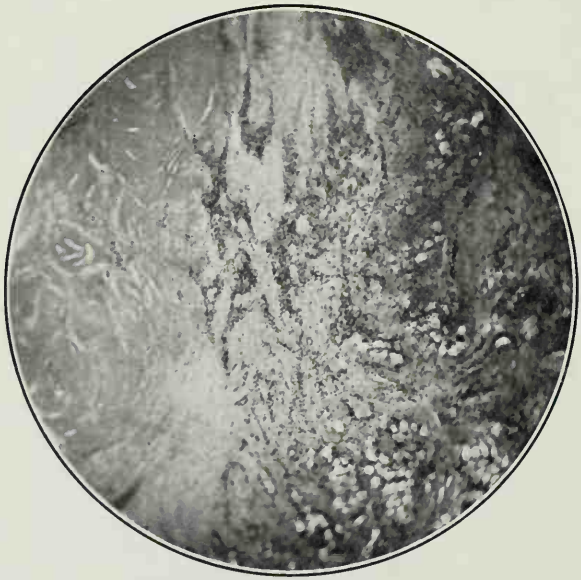

Fig. 4.—Solid plugs and epithelial acini invading the dense connective tissue.

carcinoma appears four times, while in the author's bibliography cases which might be classed as adenocarcinoma are found only eleven times. Adenocarcinomata apparently arising from an accessory lacrimal gland are very rarely encountered.

The case herein reported is unusual, not only because of its manifest rarity, but also because malignancy was not diagnosed, encountered almost by accident, and recognized only by the pathologist.

History.—The patient, an unusually robust girl, aged eighteen years, sought help in order that she might wear a prosthesis. Her left eye was removed in infancy because of a "tumor." Further history or details were unobtainable. She wore an artificial eye until a year before being seen, at which time a mass appeared under the upper lid, near or at the outer canthus. She consulted a colleague who trimmed away the tumor. The specimen was sent to the State Institute for the Study of Malignant Disease. The specimen showed no malignancy, but owing to the indefinite history, thorough radiation was given. Following radiation and previous surgical interference, the socket became so contracted that the wearing of a prosthesis was impossible.

Examination.—The left socket was contracted so that barely the nasal third remained. Both upper and lower lids were firmly adherent to the structures beneath, all forming what appeared to be a dense fibrous tissue mass involving the temporal halves of both lids. The nasal portion of the tarsal plate with its fornix appeared normal. Springing from what remained of the temporal portion of the contracted fornix, very near the external canthus, was a pedunculated nodule about 4 mm. in diameter. The lacrimal, pre-auricular or sublingular glands were not palpable. This nodule was trimmed with scissors and sent for examination. It proved to be granulation tissue. The Wassermann test was negative.

After conference with the pathologist and clinician at the State Institute a plastic operation for the restoration of the socket was deemed safe. Consequently, six months ago the socket was enlarged by two-thirds at the Buffalo General Hospital by an epidermal graft on a mold of dental compound.

The temporal portion of the tarsal plates was exposed while

fashioning the socket. While the nasal portion of the upper plate appeared normal, the temporal portion was firmly and evenly thickened, and while resembling cicatricial tissue, still was evidently not. Chiefly for the purpose of procuring a thinner and better appearing lid and partly because the tissue did not appear normal, the thickened portion of the plate was cleanly excised and sent to the laboratory.

The mold was removed after seven days, the epidermal graft being a complete "take." After trimming away the excess epidermal graft, followed by a few days' cleansing, an artificial eye was fitted and the patient left the hospital. The prosthesis has been worn with good cosmetic results since that time and repeated examinations have shown no evidence as yet of recurrence.

I am indebted to Dr. Roman, Pathologist of the Buffalo General Hospital, who has kindly supplied the description and discussion and microphotograph of the specimen.

Laboratory Report.—Received for examination several small, flat pieces of tissue in 10 per cent. formalin solution.

In the routine frozen sections the tarsus and its glands could be recognized, and external to the tarsus there was an epithelial component, the greater part of which had fallen out, leaving holes in the section. For this reason the remaining tissue was hardened, imbedded in collodion, and new sections prepared.

The latter apparently correspond to the more proximal parts of the excised tissue as they do not show any of the structures of the distal parts of the lid. The sections consist chiefly of dense, poorly nucleated fibrous tissue adjoining which there is in some places a considerable amount of fat and areolar tissue carrying blood-vessels and nerves. In these latter parts are found imbedded several lobules of an acinous gland separated from each other by connective-tissue septa, and corresponding in appearance to those of the lacrimal gland. In other places there is also present some hyaline connective tissue arranged in bundles and appearing in cross or oblique section, which, judging from the shape and position of the nuclei, might well represent the tendinous fibers of the levator palpebræ muscle.

In the neighborhood of the gland lobules some normally appearing ducts are to be seen with a double row of cylindric epithelium. Distant from these, imbedded in the dense connective tissue, there are many more ducts in a state of abnormal hyperplasia. They appear considerably dilated and are lined with several rows of

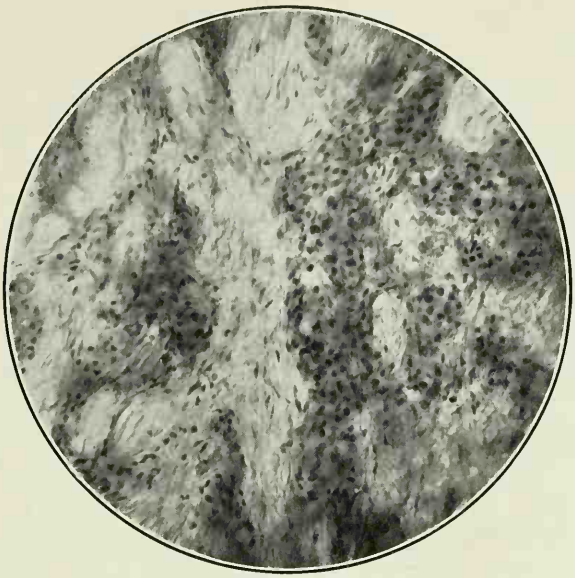

Fig. 5.—High-power view of Fig. 4.

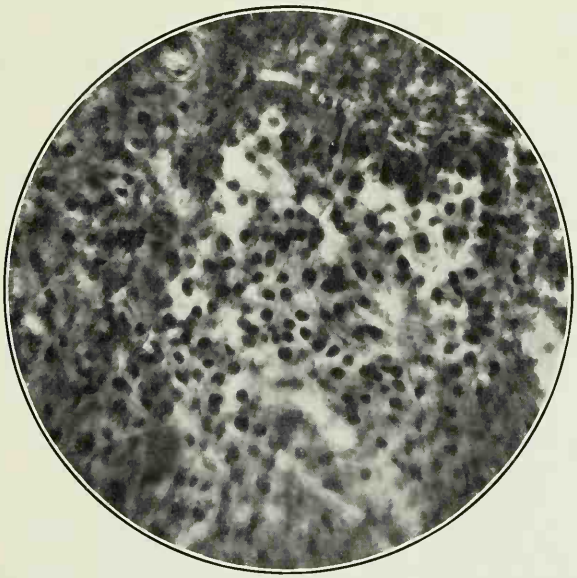

Fig. 6.—High-power view of wall of one of the ducts, showing character of cells.

epithelium which is often reduplicated, giving a papillary appearance. The cells are cylindric or cuboidal, depending upon their situation in the inner or outer layers, and mostly show deeply staining nuclei and clear cytoplasm. In the vicinity of such ducts numerous epithelial structures can be seen apparently springing from the ducts and composed of cuboidal or polyhedral cells, usually showing a faintly staining, structureless round or oval nucleus and a very clear, hardly staining cytoplasm. These structures are of various shapes, occurring either in the form of acini with a small lumen or in the form of solid plugs, and most of them usually show a very thin basement membrane. Immediately outside of the duct they mantle it and thoroughly substituting its connective tissue backing but they are more widely scattered in regions farther away from the duct.

Besides those in relation to ducts, such epithelial formations, especially in the form of more solid plugs, are to be found invading the connective tissue diffusely in many places and also in the tendinous fibers mentioned above.

Unfortunately, the material was not kept and the rather thick specimens stained with hematoxylin and eosin did not allow of any fine histologic studies, but there can be little question that the pictures seen represent an adenomatous hyperplasia and in the heterotopic growth there is sufficient histologic evidence of malignancy of the nature of an adenocarcinoma though the growth be temporarily arrested, possibly from the effects of radio-therapy.

In view of the controversy regarding the nature of many of the tumors of the lacrimal gland (endo- or epithelial), it is perhaps well to emphasize that, although in some places the cells of the growth are quite changed in appearance, resembling superficially the so-called endothelial cells of mixed tumors of the parotid, a sufficient number of transitional pictures from the epithelial elements of the ducts have been seen to exclude any reasonable doubt as to their epithelial nature. Whether the tumor is a remnant of the old embryonal growth for which the eye was enucleated in the early life of the patient or a new growth of more recent date, originating as it appears from remnants of the lacrimal gland (duct), will hardly be determined upon the evidence at hand.

DISCUSSION

Dr. E. E. JACK, Boston, Mass.: Dr. Verhoeff has suggested the name congenital epithelioma for these tumors. The analogy

between them and those of the parotid gland is quite striking. Both have a great tendency to undergo mucous and other changes.

As to the malignancy of the growths, a case of my own some years ago, which I had thought cured, suffered recurrence. A major operation and a thorough one, in which a great part of the bone around the orbit was removed, was then done; but even after that the disease was not eradicated and the patient died after some months, the whole side of the head and more having become involved.

DR. W. GORDON M. BYERS, Montreal, Canada: I should like to bring out one point in connection with the pathology of orbital tumors. Dr. Francis describes his growth as being encapsulated. I think we might say that encapsulation is characteristic of orbital tumors in general. This change is inevitable, owing to the rich system of connective-tissue stroma that exists in the orbit. The matter is fully dealt with in the report I shall presently present.

A CASE OF ENCAPSULATED ANGIOMA OF THE ORBIT

W. GORDON M. BYERS, M.D.
Montreal, Canada

The following case, of little surgical moment, is reported to help balance the picture of the encapsulated angiomata of the orbit, which largely, so far, has been filled in by records of the more menacing growths of this nature. Growing out of the case, too, are a few points of clinical and pathologic interest.

The patient, a male, aged fifty years, complained that a swelling had been gradually developing behind the right lower lid for about two years. The rate of development had not been entirely uniform; progress had been more rapid at certain times than at others. It was felt that the swelling was somewhat more pronounced when the patient was fatigued; but variations in size were not noticed in connection with stooping or conditions that favored congestion of the orbit. There was no pain.

On examination one saw the right lower lid puffed out 10 to 15 mm., as if from edema. The swelling began just below the margin of the lid and reached to the lower margin of the orbit, rounding up gently between these two points. It was somewhat more noticeable over the outer as compared with the inner half of the lid. On palpation one felt a tense, rounded mass between the globe and the margin of the orbit. This appeared to be adherent neither to the globe nor to the orbital walls, and could be shoved back easily into the orbital fat. It was quite free from tenderness. There was no apparent displacement of the globe, and the ocular movements were perfect. Possibly the tumor moved slightly in association with the upward movement of the eyeball. The fundus of the right eye was normal, and vision = 6/5−, with +0.75 sph. ⊂ +0.75 cyl. ax. 15°. The left eye was normal, and vision = 6/5.

Under general anesthesia, the tumor was removed without difficulty through a skin incision. It was quite globular in shape, and had a diameter of approximately 1 cm. in its fresh state.

Pathologic Examination.—Microscopically the growth presents all the characteristics of a "cavernous" angioma. A well-marked capsule entirely surrounds the tumor and walls it off from the orbital fat, remains of which, with widely dilated vessels, are seen here and there at the periphery of the section. Within the body of the growth are venous-like spaces of varying size. These are filled for the most part with red blood-cells and a relatively large number of polymorphonuclear leukocytes that show a tendency to collect at the periphery. In other places the contained blood has undergone degeneration. Supporting the vessels are septa of fibrous connective tissue in varying stages of development. In places this connective tissue is decidedly embryonic in character; in others it is dense and void of nuclei. The trabeculæ are thickened between the smaller and more recently formed vessels, and thinner between those of larger size. The latter can be noted here and there to be in process of coalescence. Replacing the fibrous connective tissue, one sees at times, especially toward the periphery, masses of lipomatous and areolar tissue; but, generally speaking, the fibrous connective tissue predominates.

Comments.—Two points struck me in connection with this case. Arbitrarily dividing the orbit by a plane tangent to the posterior surface of the eyeball, I found on analyzing a con-

siderable number of records that the angiomata are more frequent in the posterior than in the anterior half of the space. The position of the present growth in the median line of the orbit below and in front is, therefore, exceptional. The other point was, that in the orbit, with its rich system of connective-tissue stromata, the connective-tissue elements of the angiomata occurring here (capsule and trabeculæ) must necessarily be a pronounced feature. In the lower anterior part of the orbit, where the present case grew, the septa are especially well developed.

There seemed to be an obvious connection in the case of these angiomata between their location and the vascular supply of the orbit, as well as between their histologic characteristics and the distribution of the orbital connective tissue. My colleague, Dr. S. E. Whitnall, Professor of Anatomy at McGill University, to whom I submitted the questions, felt that the inferences might well be correct, and drew up for me the following very interesting notes on the general topography of the veins and connective-tissue septa of the orbit:

"There are two main venous trunks: (a) The superior ophthalmic vein, the chief one, formed behind the medial corner of the upper eyelid by the union of two anastomoses with the supra-orbital and angular veins of the face. Its numerous tributaries are from the upper part of the eyeball (venæ vorticosæ and ciliary veins); from the upper medial ocular muscles; and the two ethmoidal veins. It also receives the lacrimal vein, which is often large enough to be considered as a third main trunk. (b) The inferior ophthalmic vein, the vein of the orbital floor. It receives tributaries from the lacrimal sac, conjunctiva of the lower eyelid, lower part of the eyeball, and lower and lateral ocular muscles. It anastomoses freely with the superior vein, and in most cases finally empties into it at the apex of the orbit. The termination posteriorly of these trunks into the cavernous sinus is usually by a single channel, though separate entry of the superior and inferior ophthalmic veins and central vein of the retina sometimes occurs.

"Now inspection of the orbit in the skeleton, together with a study of frozen sections with the contents entire, shows that the whole cavity may be divided into a roomy quadrilateral anterior half in which is lodged the eyeball, lacrimal gland, and lacrimal sac, and a narrower triangular posterior half, wherein lie chiefly the optic nerve and bellies of the ocular muscles. It is in this posterior or retro-ocular region that most of the tributaries of the ophthalmic veins lie; for being situated behind the eyeball there are found here the numerous venæ vorticosæ, muscular, ethmoidal, and lacrimal veins, passing backward to their terminations in the main ophthalmic stems. Toward the extreme apex of the orbit all these vessels have, as noted, usually entered one stem, the superior ophthalmic vein.

"The result of this disposition of the vessels is, that if we imagine the orbital cavity to be divided by frontal planes into four regions of equal depth, of which the eyeball occupies the anterior two, then the vessels will be found in their most numerous distribution in the third quadrant, immediately behind the eyeball.

"On the other hand, is to be noted that it is in this same retro-ocular quadrant that the orbital fat, through which the veins run, is most loosely packed and yielding, and exhibits in dissection least connective stroma; since here the optic nerve makes its widest excursions in harmony with the oscillations of the eyeball, and the muscle bellies presumably exhibit their greatest range of expansion, being tendinous at their two extremities. At the apex of the orbit (posterior quadrant) the orbital fat is greatly reduced in quantity, the space being compactly fitted by the origins of the muscles, nerves, etc.; but round the equatorial region of the eyeball that fat is enmeshed in far denser connective tissue."

The points I have raised may very well have been brought out by previous writers; I have not exhausted the literature; but they are in any case of sufficient interest to bear repetition.

POSTERIOR TRANSILLUMINATION OF THE EYEBALL

GEORGE S. DERBY, M.D.
Boston, Mass.

In 1913, at the meeting of this Society, Lancaster described an instrument for the transillumination of the eyeball posterior to the equator. This consisted of a small flexible metal tube with a minute lamp at the end which is completely surrounded by metal except for one small opening at the tip.

So far as I have been able to ascertain, posterior transillumination of the eyeball, up to the present time, has been employed only by means of a powerful light introduced into the mouth, a much less certain means of diagnosis than with an instrument of the foregoing construction. For this reason I may be permitted to show again Lancaster's transilluminator and to report a case in which it was very helpful in making the diagnosis.

Last winter, through the courtesy of Dr. E. T. Easton, of Boston, I saw the patient, a young woman of twenty-five, who presented a localized separation of the retina just above the disc and overhanging it so that its upper half was obscured. The separation was of a slightly grayish color; its summit was best seen with a +12 glass in the ophthalmoscope. It extended forward steeply from the center of the disc and faded away into the normal retina above and at the sides. In the separation were a number of tortuous venous loops, and below the disc and in no way connected with the separation were similar loops apparently connecting directly an artery with a vein. This appearance of these vessels was quite striking. They could hardly be due to the influence of the new growth, as they were just as marked below the disc and some distance away from the tumor as they were over its surface. There were a few pigment spots down and in from the disc. The vision of this eye, the left, with correction, was 6/9; the other eye was normal. Tension of the right eye 14 mm., of the left 10 mm.

Fig. 1.—Lancaster's Posterior Transilluminator.

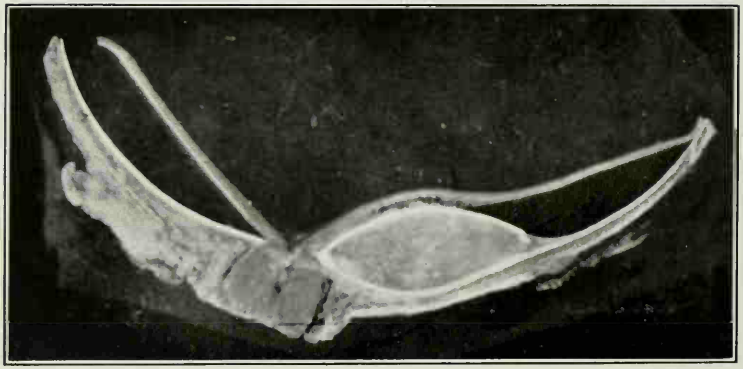

Fig. 2.

The field of vision showed a scotoma corresponding to the separation.

With Dr. Easton's approval posterior transillumination was carried out. An incision was made through the conjunctiva between the superior and external recti, about 15 mm. back of the limbus. Tenon's capsule was incised and the transilluminator, which had been sterilized in alcohol, introduced. It was very easily passed to just above the optic nerve and a small area was easily and beautifully demonstrated in the posterior wall of the eyeball, which was nearly impervious to light. The procedure was carried out under anesthesia, by means of an orbital injection of novocain, with little or no discomfort to the patient.

The eye was enucleated the next day by Dr. Easton and a small sarcoma of the choroid demonstrated by Dr. Verhoeff, to whose courtesy I owe the slide which I am passing around.

The tumor measured 6 by 7 by 3 mm. It reached the upper disc margin and was situated entirely within the choroid. It was composed of unpigmented spindle cells. The veins of the nerve head were greatly distended and contained an abnormal number of polynuclear leukocytes. Arising from several points on the surface of the disc was a small amount of neuroglia tissue containing thin-walled blood-vessels. These vessels continued over the surface of the retina almost to the macula and for an equal distance in the other directions. The significance of these vessels is uncertain.

Dr. Lancaster's transilluminator has been in my possession for some years past waiting for such a case. It will never be used very frequently in any man's practice, but when the occasion arises it will be found very valuable.

A college professor, aged forty years, was seen in consultation. He presented a pigmented area in his fundus just outside the macular region which showed a slight elevation but no separation of the retina. The eye had normal vision. As the area increased in size and elevation and vision began to fail during the succeeding months it was decided to enucleate. The patient's oculist asked me to remove the eye, which I did and a glass ball was implanted. A small flat sarcoma of the choroid was found, and under the microscope, one of the ciliary nerves emerging from the eyeball was found to be surrounded by tumor cells.

A secondary operation was then performed and a certain amount

of orbital fat in the muscle cone removed. The glass ball was reinserted and has remained *in situ*. The cosmetic result is fair.

Had the posterior transilluminator been used in this case, diagnosis would have been made some months earlier, the future safety of the patient would have been better assured, the necessity of a second operation would have been avoided, and a better cosmetic result would have been obtained. I believe the instrument to be of real value in a certain group of cases.

DISCUSSION

DR. E. C. ELLETT, Memphis, Tenn.: I think the type case in which this particular instrument is valuable is probably not very often seen. On one occasion I had such a case in which ordinary illumination with the transilluminator placed as far back as possible did not give any positive evidence of obstruction to the passage of light, but the use of this instrument, as Dr. Derby has described it, gave positive evidence upon which we were a little safer in advising enucleation. The eye was removed, and the tumor, considerably larger than in this case, was found on section to be situated too far back to be shown by ordinary transillumination.

DR. W. E. LAMBERT, New York City: I have not had an opportunity to use this instrument, but I wish very much that I had had it recently.

I think in a great many cases the growth is in such a position that ordinary methods of transillumination are negative, and I believe this instrument would be a very valuable aid to us in many instances of ocular tumor.

DR. J. S. LICHTENBERG, Kansas City, Mo. (by invitation): I want to refer to the superiority of Dr. Lancaster's transilluminator in cases where the tumor occurs in the posterior segment of the eye, over an instrument I saw in Berlin. This was introduced into the nasopharynx and the heat produced by the light was so strong that it was necessary to use a water cooling apparatus in connection with it.

DR. GEORGE W. JEAN, Santa Barbara, Cal. (by invitation): Dr. Lichtenberg has mentioned the ophthalmodiaphanoscope. The late Dr. Marple brought one back from Europe in 1907, and we tried to use it at the New York Eye and Ear Infirmary. It illuminated from the pharynx through a powerful lamp enclosed in

a large glass tube and was cooled by a circuit of water. It was always out of order and not satisfactory. Transillumination is a fascinating study, and in 1914 in several university eye clinics in Germany I inquired about the Herzell instrument and found that none of the clinics used it.

DR. GEORGE S. DERBY (closing): I simply want to emphasize again how easily this instrument is used. A small incision can be made through the conjunctiva and Tenon's capsule and then it can be passed behind the eye without any trouble or any damage.

SELECTIVE THERMOTHERAPY

W. E. SHAHAN, M.D.
St. Louis, Mo.

The principle of the use of different degrees of heat for accomplishing different therapeutic purposes originated from experimental observations which, at the time they were published, appeared to have no practical usefulness.[1] An instrument, the thermophore, had been developed and by means of this, precisely regulated and automatically controlled degrees

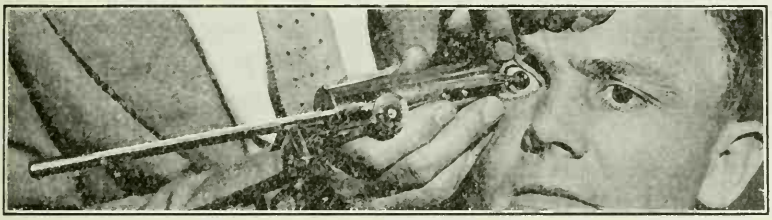

Fig. 1.—Application of Thermophore.

of heat could be conducted directly into the tissues for any length of time. Also the area of the tissue surface treated was limited sharply by the size of the contact surface used in conducting the heat. Fig. 1 shows this instrument in use.

By means of an earlier and cruder form of this instrument it was shown that corneal epithelium was destroyed by a con-

tinuous application of 130° F. for one minute, and that atrophy of iris tissue could be induced by 130° F. applied for ten minutes or 140° F. for five minutes, without permanent clouding of the cornea. Also it was found that corneal and scleral tissues would stand 190° F. for one minute without destructive changes leading to necrosis. A number of interesting intra-ocular changes can be produced without visible external changes with this instrument, and an important communication based on a large amount of experimental work is now in preparation by Dr. Lawrence Post.

Noting the wide gap that separated the thermal death-point of corneal epithelium from that of scleral and corneal tissues, it was thought probable that the thermal death-point of succulent neoplasms might lie somewhere between these points, and this was sought as occasion presented itself; 130° F., 135° F., 140° F., and 145° F., each was applied from one to two minutes to various tumors, details of which have already been published,[2] and it was found that their death-points ranged somewhat below 140° F. applied for one minute, except in the case of a tough fibrous dermoid where no beneficial effect was noted. The question as to how much heat can safely be applied to epibulbar structures was quite thoroughly worked out by Dr. Lawrence Post and myself in a series of "Thermophore Studies in Glaucoma."[3] We had found that one five-minute application astride the limbus produced prolonged low tension (three weeks to a number of months) without additional treatment, and in following this up in the hope of producing permanent low tension had occasion to apply 140° to 145° F. for five minutes to numerous rabbit eyes and to 32 human eyes *without causing permanent damage in any case.*

Having already found that the thermal death-point of epitheliomatous and papillomatous tissues was below 140° F. applied for one to one and a half minutes, we now felt free to use a larger margin of safety in treating these structures.

Our present technic in such treatment is as follows:

1. Instillation of 5 per cent. cocain and 1/4000 adrenalin. 2. Subconjunctival injection of one or two drops of the same solution. 3. Wait eight minutes. 4. Apply thermophore at 140° to 145° F. for one and a half to two minutes to tumor.

The contact surface of the conductor used must not be moved about on the tumor, but must be held steadily in position for the full length of time. If the contact surface fails to cover all the tumor, a part of it must be treated for the full one and a half or two minutes, and then the contact surface moved to another part and held there for another one and a half or two minutes. If this surface overlaps the normal conjunctiva to a certain extent, it will do no harm. If it overlaps the cornea, it will destroy the epithelium, but this will be rapidly replaced and no permanent harm will result. If the anesthesia has been properly carried out, there will be no pain during the treatment and little, if any, afterward.

The treatment does not show any very marked immediate effects. There is a slight cloudiness in the mass of the tumor, and the whorls of blood-vessels are darker in color. However, by the next day a peculiar slow reaction has set in, and this continues sometimes for three or four weeks before the final outcome is determined. The whorls of blood-vessels in the tumor mass become very dark in color and irregular in caliber, being widely dilated in some spots and constricted almost to invisibility in other spots when viewed by a rather short focus Coddington lens. There may be rather marked conjunctival edema for several days without much, if any, discomfort. There will also appear small hemorrhagic areas within the tumor mass. These phenomena will gradually diminish during the succeeding two or three weeks, and end with the tumor gone and the conjunctiva nearly normal. Sometimes this is slightly puckered or thickened, but the minute, nest-like whorls of vessels and the angry vascularization that surround a tumor mass will be gone. If it is found

after the first reaction subsides that a portion of the tumor escaped, another treatment is, of course, indicated. We do not ordinarily give a second treatment.

The number of cases treated to date has not been very large,—about a dozen of various kinds,—but the results have been so decisively satisfactory that we feel justified in drawing general conclusions.

Considerable satisfaction, but not such decisive satisfaction, has been obtained in treatment of tumors of the lids. Dermal tissues have a thermal death-point rather near that of tumors invading them, and suffer more from the treatment than scleral, corneal, or bulbar conjunctival tissues.

In the treatment of a congenital capillary hemangioma 2 by 2½ mm., 140° F. was applied twice for one minute at intervals of about four days, with very little result; 145° F. applied for one minute caused the tumor mass to darken and come off as a dry scab within about one week. A slightly pale and depressed area was left, leaving the skin thinner here than elsewhere. The conspicuous bright red spot, however, was gone. Various temperatures were also tried on xanthelasmata, and it was found that it took 145° F. applied for one minute to destroy them. The technic for these is as follows: 1. Touch small point adjoining tumor with 95 per cent. phenol. 2. Insert needle through this point and inject one or two drops of 4 per cent. or 5 per cent. cocain and adrenalin solution. 3. Wait eight minutes. 4. Apply contact surface to all parts of tumor for one minute at 145° F.

Immediately after treatment not much change will be noticed. An hour or two later a blister may or may not be observed where the contact surface met the normal skin. The next day there will be some edema about the tumor and the vessels in the tumor will be very dark in color. Following this at intervals of several days the tumor will be thrown off in scab-like masses, and finally a small pale area will occupy the site of the middle of the tumor. These are much less con-

spicuous than the tumor masses themselves. So far as I know, Dr. James Bordley, Jr., was the first to successfully use the thermophore in treating these tumors.

In thickened epitheliomatous masses in the lids heat will probably not penetrate deeply enough. Radium has been so successful in many such cases that it should be given preference.

In treating hypopyon keratitis more skill, alertness, and firmness are required than in treating tumors. In this case we are dealing with a comparatively rapidly destructive process and a higher temperature must be effectively applied. In the original study of this subject[4] it was found that the thermal death-point of intra-ocular pneumococci was 152° F. applied for one minute. It must be remembered that *this is the minimum* that will produce this result, and if it happens that the patient moves or the operator's hand is unsteady or some part of the ulcer remains uncovered, *this minimum will not be reached*, and the result will be a failure or partial failure. The corneal tissues will stand much more than this minimum. So it is best to use a margin of safety. Our technic for this at present is as follows: 1. Instil several drops of 5 per cent. cocain and adrenalin at intervals of four or five minutes. 2. Apply thermophore at 160° F. for one minute to all parts of ulcer and for ½ mm. beyond margins.

If the ulcer is irregular, different sized contact surfaces will have to be applied to different parts of the ulcer for one-minute intervals until *every part* of the active yellow area is covered and overlapped for ½ mm. or more.

The best results are obtained when *every bacterium is killed at one treatment*, so that the thermophore will have to be used *once only*. This ideal is often, but not always, attained. When it is attained, results are extremely satisfactory; the patient becomes comfortable within a few hours and remains so under mild treatment until cure is complete. On the day following treatment the whole ulcer is gray in color and clean,

and all discharge has stopped. The hypopyon is beginning to absorb. On succeeding days the epithelium gradually grows over the ulcerated area until it completely covers it. Sometimes before the lost substantia propria is replaced, the epithelium is not firmly attached and may form a bleb. This needs no treatment. The only medication during this period is argyrol 25 per cent., or mercurochrome 2 per cent. and atropin. A light bandage may also be employed.

The ulcer should be very closely watched. Sometimes a small projecting tongue of activity escapes, there is still some pain, and a small yellow point is seen at this place. When it becomes evident that there is a small nest of pneumococci still alive, a contact surface just large enough to cover this nest should be applied at 160° F. for one minute. Frequently only the small conical point is necessary to destroy this nest; or if there are several suspicious places, these places should be treated. It is practically never necessary to cover the whole ulcerated area a second time. Also if the ulcer has already progressed for several days before reaching the physician, and one margin of it is healing and clean, only the yellow advancing margin need be treated, but this must be effectively covered.

In indolent and non-infected ulcers, where destruction of invading organisms is not the object, a lower temperature is indicated; 135° F. applied for one minute to an indolent ulcer, such as may occur on an old corneal scar, may change the base of the ulcer so as to cause a rapid and permanent covering of epithelium to grow over it.

In conclusion I would like to state that the field of selective thermotherapy is but incompletely covered, and that the advances so far made would scarcely have been possible without the friendly co-operation of my St. Louis colleagues.

REFERENCES

1. Effects of Heat on the Eye, W. E. Shahan. Jour. Amer. Med. Asso., 1916, vol. lxvii, pp. 414–417.
2. Thermophore Treatment of Ocular Neoplasms, W. E. Shahan. Jour. Missouri State Med. Asso., 1921, vol. xviii, pp. 392.
3. Thermophore Studies in Glaucoma, W. E. Shahan and Lawrence Post. Amer. Jour. Ophth., 1921, vol. iv, No. 2.
4. Further Study of the Effects of Heat on the Eye, W. E. Shahan. Jour. Amer. Med. Asso., 1917, vol. lxviii, pp. 1969–1973.

DISCUSSION

DR. JOHN GREEN, JR., St. Louis, Mo.: In my experience the thermophore has been uniformly successful in serpent ulcer. In the worst cases of very large ulcer with increasing hypopyon a Saemisch section has been supplemented by one or more applications of the thermophore. I have yet to see a case in which the thermophore alone, or combined with a Saemisch section, did not stop the further progress of the ulcer.

A tiny ulcer developed at the apex of the cone in keratoconus. Routine treatment for ten days failed to help. The thermophore was applied for one minute at 135° F. Two days later there was no staining after fluorescin, and in a week the ulcer had healed.

J. B. S., aged sixty-nine years, male, came under my observation April 25, 1923. The right eye had been struck five years previously by a tack, apparently a non-penetrating injury. A few months later a small growth was observed at the temporal sclerocorneal juncture. It had slowly increased in size and was surgically removed in 1921. Soon after it "began to grow again."

A hemispheric epibulbar growth, measuring 6 x 7 mm. and elevated 2.5 mm., vascular, pigmented, reddish brown in color, and firm to the touch, sprang from the sclera adjacent to the cornea. Ophthalmoscopy, transillumination, and slit-lamp microscopy showed no evidence of intra-ocular involvement. A fragment of the growth excised for pathologic examination was reported "mixed cell sarcoma." April 26, in consultation with Dr. Shahan, the thermophore was applied for two minutes at 145° F. The following day the vessels were seen to be discontinuous and curly. The growth rapidly diminished in size. The intravascular spaces were filled with a translucent substance.

On June 9, 1923, there was no trace of the growth, but there remained three small pigmented patches in the sclera. Vision, corrected, 6/7.5. One cannot be certain that there will not be a recurrence, but at present there is no trace of the neoplasm.

DR. ARNOLD KNAPP, New York: I would like to ask Dr. Shahan to tell us what results he has had with the thermophore in the treatment of pterygium.

DR. W. H. WILDER, Chicago: I should like to ask Dr. Shahan if he modifies his treatment in any way in cases of infectious ulcer that has extended deeply through the layers of the cornea in which there appears a keratocele threatening perforation.

I recently had a case of that kind in which the ulcer extended rapidly through the corneal layers, and after we had used the treatment perforation occurred and the case became worse, necessitating, ultimately, evisceration. I have found his treatment of value in ulcers of less severe type.

DR. LEE M. FRANCIS, Buffalo, N. Y.: I would like to ask Dr. Shahan what his experience has been with cases of keratitis profunda and keratitis disciformis; also what temperature he would recommend, and the duration of the application.

DR. W. E. SHAHAN (closing): I have made no attempt to use the thermophore on pterygium. This is a conjunctival growth and conjunctiva will stand 145° F. for five minutes. Hence I have felt that in this case thermotherapy would probably be futile.

In about 60 cases of corneal ulcer, nearly all referred to me by my colleagues, there were five or six perforations. These were all pin-point and produced a beneficial rather than a harmful effect. They allowed escape of the hypopyon without engagement of the iris, and were followed by marked improvement. I have never seen a globe removed in consequence of hypopyon keratitis.

I have had no experience in the use of the thermophore in keratitis disciformis or keratitis profunda. If I were to try it, however, in such cases I would begin with 135° or 145° F. for one minute, and allow about a week for the reaction to subside. If results were not satisfactory, I would then try a higher temperature—145° or 150° F., for one minute.

As stated before, the field of selective thermotherapy is only partly covered, and it will take some time to know its full possibilities and limitations.

MALIGNANT DISEASE OF THE RETINA

EDWARD JACKSON, M.D.
Denver, Colo.

Starting in the retina are two forms of disease characterized by tissue growth which may be properly termed malignant. They differ wholly in their incidence, course, clinical characteristics, and outcome. One of them, which differs in every respect from glioma, as manifested elsewhere, has been called "glioma of the retina." The other, to which the term glioma might possibly be appropriate, has been called "the massive exudation in the retina of Coats," von Hippel's disease, angiomatosis of the retina, and by Meller a gliosis.

The confusion which has been bred and fostered by misapplication of the term "glioma of the retina" greatly interferes with the understanding, diagnosis, and prognosis of clinical cases, and so confuses the general pathologist that his report on an enucleated eyeball often leads to confusion in the mind of the oculist who treated the case, and to confusion in the literature. The general pathologist who has studied glioma of the brain knows that the slide under his microscope does not present glioma as he knows it; and, thus thrown on his general knowledge of pathology, names it from the appearances presented by parts of the growth in advanced cases, as sarcoma, etc., or advertises his confusion and defeat by such a term as gliosarcoma.

By adopting a modern term for this condition, which was recognized for one hundred and fifty years, mostly under the name of medullary cancer of the eyeball, we could get rid of a real obstacle to progress in ophthalmic science. Now that Verhoeff has shown that real glioma is the character of the

tumors of the optic nerve, as distinct from tumors originating in its sheath; and Martin and Cushing have recognized that true glioma is of practical importance as a tumor of the optic chiasm, it is more important than ever before to get rid of this spurious "glioma of the retina." This Society can make good use of its time and authority by appointing a committee to determine what is the best name for these tumors and adopting that name for its transactions.

Malignancy, as indicating a characteristic of tumors, is commonly used to cover two wholly different tendencies. These are both distorted tendencies of cell life and development. The one is the tendency to multiplication of the cells beyond the needs, and in opposition to the welfare of the general organism; under the general conditions and in the tissues where such cells should normally develop. This is allied to normal hypertrophies, the formation of epithelial callus under pressure, or the multiplication and development of fibroblasts under various irritants.

The other is the modification or dropping of the cell life to such a primitive plane that it is enabled to secure and assimilate nutritive material, under conditions quite different from those in which the normal development of such cells takes place. This is a progressive step in malignancy, to which many malignant new growths show a marked disposition. It is shown when an epithelial thickening begins to throw out buds that invade the subepithelial tissues, or to develop the isolated cell nests that show the characteristics of an epithelioma. It continues, with increasing influence, until the power of metastasis comes, to mark the degree of malignancy.

The change from a benign to a malignant tumor lies in the change of tendency to cell proliferation, from that which is bounded and controlled by the general needs of the body, to that which passes such bounds and escapes such control. A thoughtful pathologist has called cancer "cell anarchy." In cell anarchy the pirate or bandit cell, that can go anywhere

in the body and there appropriate the food resources of the normal cells of that part, thrive on them, starve and destroy the normal cells, is the most completely malignant, the most dangerous element that can enter into the general cell community of the organism.

The power of growing and proliferating to excess in its original habitat, so that by displacement or pressure it may impair the function of adjoining parts, constitutes the malignancy of real glioma or glioblastoma, a tumor developed from the glial tissue of the central nervous system, as we find it in the brain, the optic chiasm, or the optic nerve. It is the lowest grade of malignancy. The effect may even be compared with that of displaced bone, or of cerebral hemorrhage or slowly enlarging cyst. The effects of such growth develop slowly, over long periods of time, and only become serious or fatal when by adaptation the resistance of neighboring and vital structures has been overcome or exhausted. Symptoms arise, but they rest on local changes; there is no metastasis, no change of nutritive processes, no general toxic influence, no cachexia is produced. Such a disease we have in the "massive exudation" of Coats.

On the other hand, the old medullary cancer of the eye, the so-called "glioma of the retina," starting with local overgrowth, excessive cell proliferation, rapidly develops the power of the cells to nourish themselves in situations and under conditions widely differing from those of the normal retina. They become able to live and propagate under new conditions, or they become able to modify conditions in other parts of the body, so that these tumor cells can live and thrive there, while the normal cells of the part sicken, atrophy, and disappear. The retinal growth becomes metastatic, and its cell population may invade and flourish in any part of the body. Kusama, adding to the list of Wintersteiner, found cases of metastasis, mentioned in the order of frequency, outside the eyeball, involvement of the brain and pia mater,

cranial and facial bones, lymphatic glands, parotid glands, distant parts of the skeleton, the liver, spinal cord and membranes, kidney, ovary, lungs, spleen, lacrimal glands, testicle, and pancreas.

The contrast between the two diseases called glioma is evident from comparison of their histologic appearances, which may be made by the examination of sections or even the illustrations of these appearances found in the literature. I have found no textbook on general pathology published in English, that gives a good description or a good illustration of glioma of the retina, so-called. It is clear there is great need for a more definite nomenclature of malignant disease of the retina, and one upon which ophthalmologists, pathologists, and anatomists can generally agree.

To decide what these conditions should be called, certain points with regard to them must be cleared up. That the tumor called "glioma of the retina" is not properly a glioma seems clear. Should it be called neuro-epithelioma, as Flexner suggested? This raises the question as to whether neuro-epithelium is a good term for the part of the retina to which it is applied; and, the second question, does the growth in question always or generally arise in this part of the retina. In the majority of cases studied the tumor seemed to arise from the inner layers of the retina rather than from the outer. The formation of "rosettes" may be suggestive of cell heredity of neuro-epithelial tendencies, but is far from conclusive. Other tendencies, especially the low vitality of the cells far removed from the vascular base of supply, are more characteristic.

Other names suggested are equally open to objection. Gliosarcoma manifestly has been coined to meet the situation where a tumor, giving the clear history of tumors that have been called gliomas of the retina, presents under the microscope not the picture of real glioma but that of a sarcoma. It should be questioned whether neuroblastoma

(Mallory) is the right name for tumors that arise primarily in no part of the nervous system other than the retina, and which have a clinical history and tendency to metastasis so different from any other known tumors of neural origin. In view of the uncertainty as to the layers of the retina in which these tumors start, the possibility that they start in various parts of the retina, the certainty that they are primary nowhere else than in the retina, it may be that the term recently used by Mawas, retinocytoma, would be best.

With reference to the disease described by Coats as "massive exudation into the retina": his explanation of an origin, secondary to hemorrhage, due to some unrecognized blood condition, seems far-fetched and improbable. A vascular origin, as put forward by von Hippel, is also very doubtful. Meller's suggestion of gliosis seems the more rational, and certainly agrees with the resemblance in the clinical course to gliomas of the brain, chiasm, and optic nerve. Certainly, wherever available, sections of the tissues found in eyes removed for this disease should be studied by the light of the observations of Verhoeff regarding gliomas of the optic nerve; and the name chosen according to the evidence thus accumulated.

It seems worthy of this Society to do something of this kind: To appoint a committee to study and report on the nature, origin, and naming of malignant diseases of the retina, with which all can co-operate; and when their investigations have cleared up these questions as much as possible, to adopt and recommend the use of a rational nomenclature that will help and not prevent a clear understanding of the subject.

AUTOPSY REPORT OF A CASE OF BILATERAL GLIOMA RETINÆ WITH GLIOMATOUS INVOLVEMENT OF THE IRIS

ARNOLD KNAPP, M.D.
New York

While the early clinical symptoms of glioma retinæ are well known, some of the later manifestations are not frequently observed, as early enucleation is the usual treatment. At the same time, opportunity for an autopsy is unusual, so that the report of some late clinical features—central perforation of the cornea and gliomatous involvement of the iris—and the autopsy findings seem justified.

The patient was a child, aged three years, of Greek parentage, who was brought to us on September 1, 1921, because the left eye was inflamed. When the child was three months old a yellow reflex was noted in both eyes, and at six months she was placed in a home for the blind. The child in other respects seemed normal; the other children were all healthy. On examining the eyes, an irregular pink, granulating mass was found in the center of the left cornea (Fig. 1). This was regarded as a perforation, with the formation of granulations in a low-grade panophthalmitis, not suspecting an anterior perforation of a glioma. The other eye, of normal size, presented a central opacity in the lens and an exudate in the vitreous. The only peculiar feature was a small, soft swelling under the scalp. The left eye was removed, and on section a glioma of the retina was recognized. While under the anesthetic the right eye was more carefully examined, and the mass in the vitreous now suggested a glioma of the retina. Microscopic examination of the left eye showed a central gap in the cornea filled with gliomatous material, continuous with the principal tumor filling the eyeball. The lens had disappeared. The ciliary body was transformed into a thick, gliomatous structure of well-stained cells which had infiltrated into the stroma of the iris

Fig. 1.—The left eye, showing the corneal perforation.

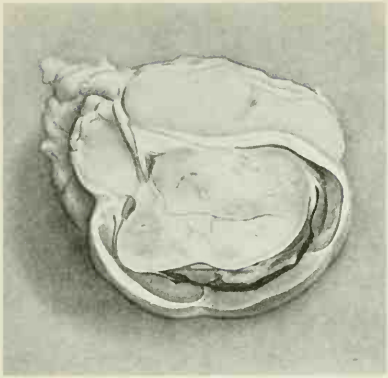

Fig. 3.—The right eye.

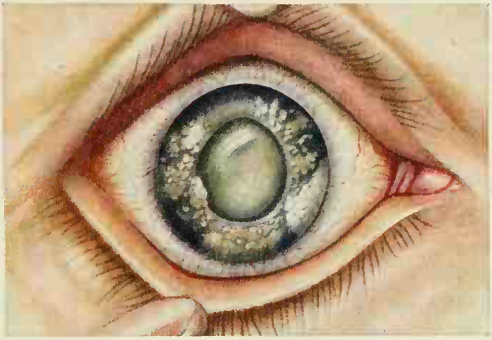

Fig. 2.—Gliomatous involvement of the iris.

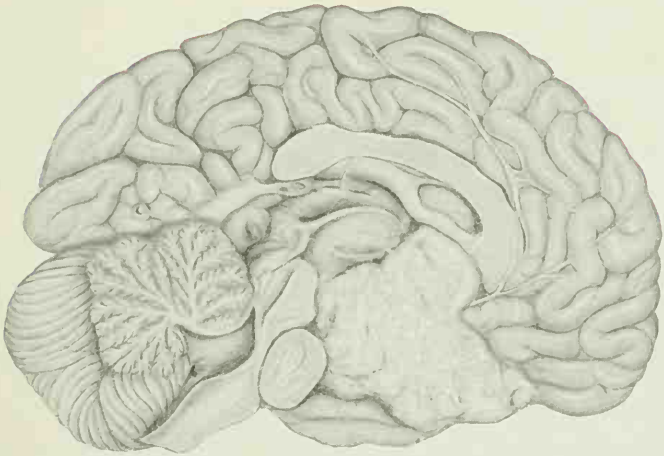

Fig. 4.—Glioma of the midbrain; direct extension.

and also extended along its posterior surface. Collections of glioma cells were spread over the posterior surface of the cornea. The choroid was not involved except for a circumscribed area at the equator and in the parts directly adjoining the invaded optic nerve.

The way in which this perforation of the cornea occurred was subsequently demonstrated by the clinical course of the other eye. There was an increasing ectasia of the cornea, with enlargement of the eyeball; corneal ulceration from exposure then developed, followed by perforation. A subsequent stage would be the formation of a vascular, mushroom-like tumor—the fungus hæmatoides of the older writers.

A local recurrence took place in the left orbit two months later; this was removed; there was no change in the right eye. Six weeks later, December 15, 1921, the child was again brought to the hospital with another recurrence in the left orbit. The right eye had enlarged, and the iris showed peculiar nodular changes (Fig. 2). A vascular mass had pushed through the tissues at the root of the iris, just as if coming from the ciliary body. The iris surface was covered with vascular, round, white nodules, and loose whitish material resembling hypopyon appeared in the bottom of the anterior chamber. Subsequently a hemorrhage in the anterior chamber took place, the iris nodules were no longer defined, the iris markings became lost, and the anterior chamber contained a coagulated mass. As the cornea was not covered, an ulcer from exposure developed in the lower third, which perforated, and a purulent-like fluid escaped.

Involvement of the iris in glioma is an unusual occurrence. Among the few references in the literature I have failed to find a description or illustration resembling this case. The extension of a glioma of the retina to the choroid regularly occurs at the place where the choroid and retina join, namely, at the entrance of the optic nerve, as was originally shown by Herman Knapp in 1868. The lamina vitrea usually prevents the extension at other points (Wintersteiner). On invading the papilla, the tumor progresses into the adjoining choroid, often producing a characteristic pillow-like infiltration. The tumor finally continues uninterruptedly to the ciliary body

and iris. The entire uveal tract may be converted into a tumor mass consisting of connected convoluted nodules, separated by a pigment line from the necrotic retinal tumor in the center of the eyeball. In other cases, as in this, the extension to the anterior part of the eyeball takes place by a gliomatous growth along the inner surface of retina and choroid, extending to the orbiculus ciliaris, the ciliary processes, and the zonula. The ciliary body is overgrown by thick, gliomatous material which penetrates between the ciliary processes, replacing them by a tumor mass, and then infiltrates the iris stroma. In some cases the surface of the iris and the posterior surface of the cornea are covered by small glioma nodules or extensive gliomatous masses, which are probably of similar origin as the isolated nodules in the vitreous. The gliomatous proliferation in the iris may become free in the anterior chamber, or the loose gliomatous cells may sink to the bottom, producing a hypopyon-like deposit that has frequently been mistaken for pus.

In our case the mass in the left orbit increased in size, the glands in the left side of the neck enlarged, and general petechial hemorrhages occurred. The condition of the child failed rapidly without any signs of cerebral involvement, and death took place on January 30, 1922.

The right eye (Fig. 3) was removed for microscopic examination. The eyeball presented a large epibulbar tumor. The optic nerve sheath was completely filled with gliomatous cells. The eyeball was somewhat shrunken and completely disorganized, the interior structures were replaced by a gliomatous mass, chiefly necrotic, with irregular pigmentation and cholesterin crystals. The sclera was infiltrated with masses of glioma cells. The anterior chamber, iris, and ciliary body were transformed into a gliomatous mass, with obliteration of all details. At the center of the collapsed cornea there was a perforation filled with necrotic gliomatous material. The optic nerve was uniformly enlarged, with a constriction of the optic foramen.

Autopsy was performed five hours later by Professor James

Ewing, of Cornell University. Body of extremely emaciated female, aged three years.

Left Orbit: Protruding from the left orbit is a tumor mass about 8 by 10 cm., over which the lids are greatly distended, but not necrotic. The tumor is soft and lobulated; its surface is infiltrated with blood, but there is no obvious necrosis. The mass occupies the entire orbit and is adherent to the periosteum below, involving the bone of the floor of the orbit and the inner surface of the lower lid. It is free above.

Right Orbit: On reflecting the scalp in the region of the lacrimal gland, a bluish tumor mass is exposed which fills the orbit above. This mass is covered by periosteum and proves to be an extension into the orbit from a subdural tumor which half fills the right middle fossa.

Left parotid gland enlarged. Thymus: Normal. Heart: Normal. Lungs: Normal.

Spleen: Size normal; consistence much increased; very elastic; markings normal; surface shiny.

Liver: Slightly enlarged; presents on its surface as well as on section many miliary to bean-size tumor nodules.

Kidneys: Very firm but show no abnormality. Pancreas: Normal. Stomach and Intestine: Normal.

Lymphatics: Mesenteric nodes slightly yellowish and rather prominent. No lymphatic metastases anywhere demonstrable.

Chest; Protruding into the chest cavity, beneath the periosteum, and replacing (?) the bone substance, over segments 2 cm. up to the entire rib, are soft, opaque, yellowish tumor masses. Every rib is involved except the two lower ones.

Pelvis: In the left false pelvis there is a tumor mass, the size of hen's egg, beneath the periosteum of the ilium.

Scalp: The periosteum is protruded by very many flat elevations lying beneath the periosteum and rising to about 5 mm. above the surface of the skull.

Brain: Beneath the dura and not opposite the subperiosteal tumors, but scattered all over its convexity, are flat, vascular, soft tumor masses, 1 to 5 mm. thick (Fig. 5). These are outlined in a zone of hemorrhage and some have caused erosion of the bone (Fig. 6). The brain is adherent to the periosteum at the exit of the optic nerves, and all the tissue around the optic chiasm is converted into a soft tumor mass (Fig. 4). This tumor mass has destroyed two-thirds of the optic thalamus.

Anatomic diagnosis: Recurrent glioma retinæ, left orbit, with metastatic growths in the right orbit, skull, pericranium, liver, ribs, and left ilium.

This case, aside from the perforation of the cornea and the peculiar involvement of the iris, illustrates certain striking peculiarities in the course of a glioma of the retina. First, its extension by continuity along the optic nerve to the brain (Fig. 4) and to the bony walls of the orbit and the adjoining bones of the face, which explains the tendency of glioma of the retina to local recurrences. Second, as evidences of metastasis, the multiple isolated subperiosteal tumors in the skull. These appeared on the inner surface of the vault of the skull as red, nodular masses, firmly adhering to the dura (Fig. 5), and with a corresponding defect in the bone, with an irregular, jagged margin (Fig. 6). On the external surface of the skull there were a number of small, yellow, subperiosteal tumors without involvement of the bone. Third, the most noticeable tumors in distant bones occurred in the ribs (Fig. 7), with the development of diffuse, nodular subperiosteal tumors in which the bone was not macroscopically involved (Fig. 8). Numerous nodules were present in the liver, both superficial and deep. The parotid gland was enlarged.

Metastases in retinal glioma are rare, and these are preferably in the bone and rarely in the internal organs. Sarcoma of the choroid, on the other hand, rarely extends to the orbit, it does not recur locally, and is very prone to metastasize in the liver. It is also curious that the metastases in glioma occur about the eye and decrease with the distance away from it. The predilection for bone involvement is striking. This is especially so when their rarity in choroidal tumors is noted. Wintersteiner found in glioma of the retina tumors of the skull as frequent as brain involvement (40 and 43 respectively), while the liver was involved in only 7; Fuchs found in 33 choroidal sarcomata the metastases present 3 times in

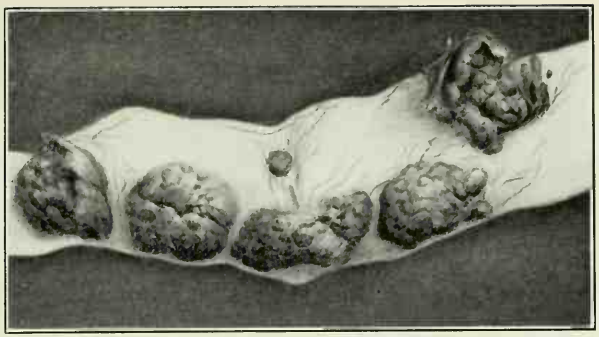

Fig. 5.—Metastatic extradural tumors on the inner surface of vault.

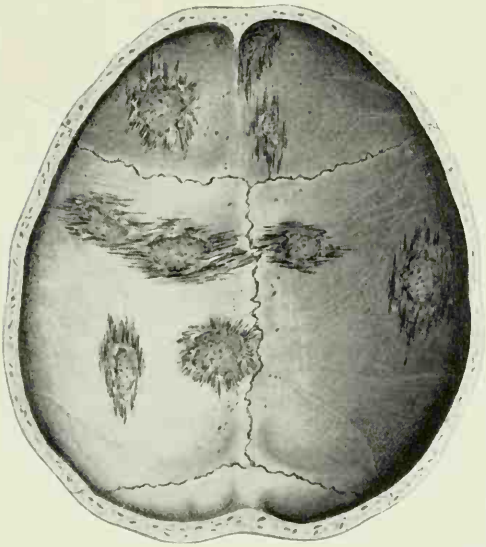

Fig. 6.—Bone lesions corresponding to preceding.

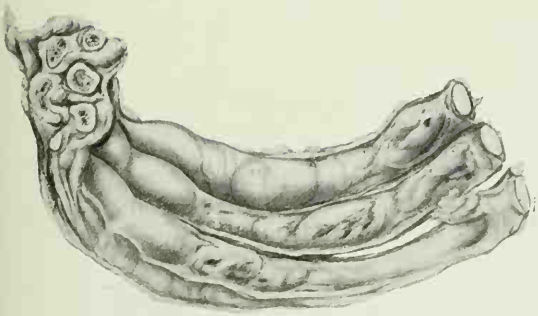

Fig. 7.—Subperiosteal tumors of the ribs, as seen from within the thorax.

Fig. 8.—Cross-section of a rib showing subperiosteal tumor.

the bones and 30 times in the liver. There seems to be a striking predisposition in the child skeleton to these periosteal metastases in glioma retinæ.

Metastases in distant organs are unusual. A reason for this, as Leber suggests, is possibly that there are but few and small vessels present in the retina. Glioma cells do not readily penetrate the vessels, as the vessels in the retinal circulation are small and the walls are thickened at an early stage. It is a matter of experience that if no local recurrence follows enucleation, metastases do not occur. When the choroid is invaded, conditions more favorable for metastases are given. In the early stage, if no local recurrence takes place, no metastases appear. Not until the choroid is invaded do conditions favorable to metastases develop, and, through the additional medium of the epibulbar and orbital tumors, opportunity is given for retinal glioma to grow along both blood- and lymph-vessels.

REFERENCES

Rompe: Beiträge zur Kenntnis des Glioma retinæ, Inaug.-Diss., Goettingen, 1884.
Pinto, da Gama: Untersuchungen über intraokulare Tumoren, Netzhautgliome, 1886.
v. Grolman: Beitrag zur Kenntnis der Netzhautgliome, v. Graefe's Arch., xxxiii, 2, p. 47, 1887.
Jung: Beitrag zur Differential Diagnose der tuberkulösen und gliomatösen Erkrankungen des Auges, v. Graefe's Arch., xxxvii, 4, p. 125.
Thieme: Ueber Gliome der Retina, v. Graefe's Arch., xxxix, 2, pp. 175–198, 1893.
Nattini: Glio-sarcoma della retina, Arch. di Ott., xxiii, p. 188, 1894.
Wintersteiner: Das Neuroepithelioma retinæ, Eine anatom. und klin. Studie, 1897.
Jessop: Case of Glioma of the Retina Simulating Hypopyon, Ophth. Rev., xxii, p. 15, 1903.
Lenders: Ein atypisches Netzhautgliom, v. Graefe's Arch., lviii, 2, p. 309, 1904.
Duehr: Ueber ein Glioma retinæ mit massenhaften intrabulbären Metastasen, Inaug.-Diss., Greifswald, 1906.

DISCUSSION OF PAPERS OF DRS. JACKSON AND KNAPP

DR. FRANCIS LANE, Chicago: Dr. Jackson is quite right in his arguments by claiming that the present-day terminology of certain pathologic changes is quite misleading. It seems, however, that possibly before we can have a re-nomenclature of these changes it

might be necessary to begin with a re-nomenclature of some of the anatomic structures. For instance, if there were to be a re-nomenclature of the cerebrospinal nerves, the optic nerve would not be called a nerve. Embryologically, anatomically, physiologically, and pathologically it resembles a tract similar to the peduncles of the cerebellum or the olfactory. Lesions of the so-called optic nerve do not follow the Wallerian law in its course of degeneration. We find not only descending atrophy, but ascending atrophy as well. This is readily explained on the grounds that the optic nerve-fibers have a double center, in that there are ganglionic cell attachments in both the retina and the cerebral cortex. In other words, the optic nerve resembles the white fibrous structure of the central nervous system.

DR. EDWARD JACKSON (closing): The case reports presented by Dr. Knapp exhibit clearly the tendency to very wide metastasis, in all sorts of tissue, which glioma manifests. I think this tendency is particularly exhibited in the formation of new nodules of glioma within the eyeball, and in these small lesions in the iris. They are independent of the original growth. The tumor is multiple in the retina often, but these are outside of the retina, and I think we must regard them as commencing metastases.

Comparatively few of the reported cases of glioma that have ended fatally have been subjected to careful postmortem examination. Those few that have been subjected to such examination seem to illustrate the very wide possibilities of metastasis, especially when we consider the circumstances under which death from recurrent glioma occurs. My impression is, from the cases I have encountered, that all of them have had metastases before death, entirely removed from the original lesion. My belief is that the tendency to metastasis is much more frequently manifested than might be implied from Dr. Knapp's remarks.

With reference to Dr. Lane's point of the optic nerve being a portion of the central nervous system, of course that applies also to the retina. But the retina is a very highly specialized nerve structure, whether or not we consider it as a part of the central nervous system. If we consider it part of the central nervous system, it is still very widely specialized, the specialization going back to the origin of the retina. It began with specialization of function; which sets apart the retina for response to light, while the rest of the nervous system, except the end-organs of special sense, respond to

nerve impulse transmitted from other parts of the nervous system. That is a difference between the retina and the rest of the central nervous system we will have to take into account before we can understand these malignant diseases of the retina.

SIDEROSIS BULBI WITH DILATED INACTIVE PUPIL. RECOVERY OF PUPILLARY ACTIVITY AFTER REMOVAL OF FOREIGN BODY

NELSON M. BLACK, M.D.
Milwaukee, Wisconsin

Graefe[1] seems to have been the first to call attention to the discoloration of the tissues of the eye from retained metallic particles, and Bunge[2] was the first to apply the name "Siderosis Bulbi" to the condition.

Numerous reports of discolored irides with a wreath of yellowish-brown dots under the capsule of the lens are to be found in the literature, but comparatively few in which an immobile pupil is mentioned. According to Parsons,[22] the staining of the lens has been regarded clinically as pathognomonic of an intra-ocular iron foreign body. Clegg[15] considers siderosis a rare condition "from the fact that during the fifteen years ending 1913, 458,496 new patients were admitted to the Royal Eye Hospital, Manchester. Of these, 111,371 were accidents, and yet one can find only 13 cases which were diagnosed as 'siderosis' in the out-patient department register. This number, 13, is certainly short of the actual total, for others have been diagnosed after they have been admitted into the hospital."

During the time mentioned above, Clegg finds six cases which came under his care in the hospital, and reports an additional one in 1915. Of these seven, only one exhibited mydriasis.

Mydriasis was observed in 4 cases out of 14 seen by

Vossius, and his review of the literature up to 1901 revealed a few similar cases observed by Maywig, Wingenroth, and Hirschberg. Kipp[11] states mydriasis must be a comparatively rare complication, as he does not remember having seen it in any of his cases. Tuckett[13] and Gibson[12] report cases of siderosis with mydriasis in which the yellowish-brown wreath of dots on the lens capsule was also present.

Dr. W. M. Sweet, in reply to an inquiry as to his experience, states: "In going over a number of unusual histories I found none in which reference was made to a permanently dilated pupil. I do not recall ever having seen a reference to a similar case."

Mann[20] reports one case in 1920 with pupil well dilated. McCreight[21] reports 13 cases (1920) seen in the last four years, "and in only two of which would the pupil react." He does not state whether there was mydriasis or miosis.

Easton[19] reports a case of iris discoloration with immobile pupil, but fails to mention the condition.

The clinical appearance consists chiefly in a rusty-brown discoloration of the iris, which usually presents a marked contrast to the iris of the other eye, especially if both were blue or gray in color originally. Occasionally there is mydriasis. The lens in the later stages becomes opaque, and often presents a yellowish-brown tinge, but the characteristic marks are the deeper brown opacities toward the periphery in the subcortical zone. These take the form of a wreath of yellowish-brown dots placed equidistant from each other. Among other symptoms are spontaneous subluxation of the lens, torpor of the retina, concentric contraction of the visual field, and defective color perception.

Siderosis is most commonly the result of the retention of iron or steel splinters in the eye for a considerable period of time. It may also result after severe intra-ocular hemorrhage.

The eye seems to tolerate the presence of iron or steel with-

out siderosis, apparently dependent upon the location of the foreign body. The conjunctiva, sclera, cornea, iris, and lens seem to have immunity in the order named. Occasionally some discoloration of the cornea follows retention of a particle, but this does not extend greatly. Bride[17] described a case in which a chip of iron was lodged in the tissues of the iris for seven or eight years. The eye appeared to be perfectly healthy, except for one posterior synechia, and had normal vision, but was subject to repeated attacks of iritis. The foreign body proved to be magnetic, and was successfully removed. No siderosis was produced.

The crystalline lens may retain a particle of iron or steel for a long time without discoloration.

The only other positions to be considered are the vitreous and the retina, ciliary body and choroid, and it would appear that in any of these siderosis may arise.

As to the cause of the discoloration of the ocular tissues, Leber[3] holds the view that "the iron is dissolved by the carbonic acid of the tissue, the solution in this form of bicarbonate of iron is diffused through the tissues, and precipitated by the oxygen of the arteries in an insoluble form." E. v. Hippel,[6] who has investigated the subject of siderosis exhaustively by examining human eyes which contained fragments of iron, and has studied the effect of iron placed in the anterior chamber and in the vitreous body of rabbits, and the effects of injections of blood in the anterior chamber and in the vitreous of rabbits, gives the following as part of the result of his investigations:

"There exists a true siderosis bulbi which may originate in a two-fold manner, firstly, direct from the foreign body (xenogenous siderosis), and secondly, from the blood (hematogenous siderosis). Siderosis consists of the deposit of oxid of iron combined with the organic substance in certain cell groups.

"The 'xenogenous siderosis' is produced in such a way

that the iron is dissolved by the carbonic acid of the tissues, the solution is diffused and becomes fixed by entering into an insoluble combination with a substance in the protoplasm, and becomes gradually oxidized in cell groups which have a specific affinity for iron. The accumulation of these cells makes micro-chemical authentication possible (distant effect of indirect siderosis). The great concentration of the solution in the immediate neighborhood of the foreign body is the cause of the great deposition of the iron in the form of an oxid at this place. In the hematogenous siderosis the iron becomes free in the dissolved state, and is then subject to the same conditions as that derived from the foreign body. The characteristic wreath of brown spots beneath the capsule of the lens, in the presence of a foreign body in the eye, is the result of the deposition of iron in circumscript collections of proliferating epithelial cells of the capsule."

Parsons[22] states: "Leber's theory of the diffusion of iron in the eye is not universally accepted. Ferrous oxid is slightly soluble in water containing a trace of oxygen (1 in 150,000). It has also been suggested that the iron is dissolved by acid phosphates in the intra-ocular fluid, or that the iron may enter into solution in organic form as an albuminate or in combination with an organic acid.

"The brown precipitate in the tissues is almost certainly produced by oxidation, but it is not a simple oxid or hydroxid, as it is only very slightly soluble in oxalic acid (McMullen). Probably the deposit is not identical in all cases, for different observers have recorded contradictory observations with regard to its solubility in various reagents. Austin found the deposits in the lens insoluble in hydrochloric acid, E. v. Hippel soluble in dilute hydrochloric acid within twenty-four hours. Bunge stated that the siderotic pigment is dissolved within twenty-four hours by 5 per cent. HCl, while hematogenous pigment was scarcely altered. In McMullen's case sections placed in 5 per cent. HCl showed scarcely any change

in twenty-four hours, and only a small proportion of the brown pigment was dissolved after four days.

"The oxidation of the iron compound in solution was supposed by Leber and Bunge to be affected by free oxygen derived from the arteries. Bunge found that the deposit was densest near the arteries, but other writers have not confirmed this observation. A serious objection to this simple theory is that in most cases the deposit is almost exclusively intracellular, and that the majority of the cells in which it is found are not phagocytic, so that they cannot be supposed to have taken up granules deposited in their neighborhood. There is no doubt that certain cells show a special affinity for iron, and it must be concluded that precipitation occurs within the cells, a process which McMullen compares with metallic impregnation methods of staining, though this is certainly due to reduction, not oxidation."

Samelsohn[4] believes the rust spots on the lens capsule represent pores in the capsule through which the fluid containing the insoluble particles of iron passes out of the capsule on which the iron is deposited.

Tuckett[13] suggests the "rusty spots" discovered on the lens capsule after the pupil was widely dilated to "have been formed by an aggregation of microscopic siderotic particles on the front of the lens capsule."

Gibson,[12] on the contrary, maintains, "the spots are not merely aggregations of microscopic siderotic particles (rust particles), as suggested by Tuckett, but fine adhesions which were very rust stained, due to a very subacute iritis, set up by the siderosis."

Vossius[5] ascribes the widely dilated pupil, which sometimes occurs, to a chemical irritation of the sympathetic fibers by the iron in the iris. This may be followed by atrophy, when the pupil will no longer react normally to mydriatics. This theory is based on the experiments of Eckhard, which show that concentrated salt solution applied

to the cervical sympathetic produces dilatation of the pupil, followed by paralysis of the dilating fibers.

According to Tuckett,[13] his case "appears to show that iron salts injure the endings of the third nerve in the iris rather than stimulate those of the sympathetic; and that the dilatation is due to the prevention of constrictor impulses reaching the iris through the third nerve. Indeed, in this case I have found that the sympathetic nerve endings are injured by iron salts quite as much as those of the third nerve, and that the dilator pupillæ loses its function; so much so that some time after removal of the piece of iron causing the siderosis, when the constrictor pupillæ begins again to respond to light and atropin, the dilator pupillæ is still paralyzed and does not respond to cocain."

Gibson[12] holds that "the fine adhesions of the iris" (as he describes the brown spots on the lens capsule) "largely explain the peculiar behavior of the pupil." "As the adhesions were not at the edge of the pupil, they would account for some dilatation and for the feeble sensitiveness to light."

Our own Verhoeff,[18] in a communication relative to Tuckett's report, states—"About thirteen years ago I made the observation that the cells of the dilatator, and to a less extent those of the constrictor muscle also, become densely packed with iron pigment in cases of siderosis bulbi, more so, in fact, than any other cells in the iris. This observation I have confirmed many times since, and in a discussion before the American Ophthalmological Society in 1906 I made brief mention of the fact that the dilatator muscle has a marked affinity for iron. The accompanying photograph strikingly illustrates this fact (Fig. 1). It is of a section stained in hematoxylin and eosin, in which all natural pigment has been bleached by a modification of Alfieri's method. Why such an evident condition has been overlooked is difficult to understand. From my observations, therefore, it would seem that the impaired motility of the iris in siderosis bulbi is not due

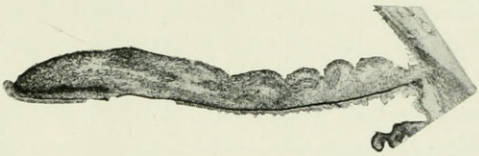

Fig. 1.—Intense pigmentation of the dilator muscle of the iris in a case of siderosis bulbi. The natural pigment of the iris has been completely bleached so that the dilator is plainly seen as a black line. The constrictor muscle is also pigmented, but this is not obvious in the photograph (Verhoeff).

to selective action on nerve terminals, but to impairment in function of the muscles of the iris resulting from their affinity for iron. In advanced cases of siderosis chronic iritis is set up, which no doubt also impairs the motility of the iris. The ciliary muscle, I find, becomes pigmented only in the immediate vicinity of the ligamentum pectinatum. This may be due to the fact that fluid containing iron does not reach it elsewhere, or to the fact that, owing to its different origin, it has less affinity for iron than the iris muscles." In a personal communication Verhoeff states: "I have found siderosis of the dilator and sphincter in all of the numerous cases of siderosis bulbi that I have examined."

Vossius[5] has observed miosis following mydriasis after a year which would not yield to atropin. Atrophy of the musculature of the iris is regarded as the cause.

The discoloration of the iris due to xenogenous siderosis has been seen to disappear, and the original color restored after the removal of the iron (Hirschberg[10]), and even in cases in which the iron remained in the eye.

Kipp[11] was unable to confirm this as long as the cases were under his observation. Disappearance of the staining of the tissues after removal of the foreign body is apparently rather rare. Rogman (Ann. d'Ocul., Jan., 1905) reports one case and mentions cases reported by Leber, von Hippel, and Cramer.

de Schweinitz[14] reports a case in which the spots on the capsule of the lens and the discoloration of the iris disappeared three and one-half months after removal of the foreign body.

REPORT OF CASE

C. J., white, aged twenty-two years, was referred from a large industrial plant January 19, 1923, for examination and gave the following history:

While shaving, four or five weeks previously, he noticed the pupil of the left eye was considerably larger than that of the right. Testing each eye, he found the vision of the former was considerably reduced. (Has grown no worse since attention was first

called to eyes.) This discovery recalled to mind an injury to the left eye in July, 1922. While driving a punch with a hammer something struck the eye, causing pain for a few moments and slight bleeding. He went to the hospital, where the eye was dressed. There was some congestion for a few days, but no further trouble until the discovery of the dilated pupil. He consulted a physician, who referred him to an oculist in Chicago. A roentgenogram revealed a foreign body in the eye, but the oculist advised doing nothing. The industrial plant, on receipt of a communication relative to the eye condition, sent for the man, who had left their employ, and had him examined by two ophthalmic surgeons in this city, who after examination and roentgenogram advised removal of the foreign body.

Examination: The pupil of the right eye is small and active to light and accommodation; that of the left, immobile and 7 mm. in diameter. The right iris is light bluish gray; the left, yellowish gray. No palpebral or bulbar congestion. Tension normal. V.R.E., 6/V; L.E., 6/X-1. Right eye: Media clear, fundus negative. Left eye: Cornea and lens clear, large and fine floating vitreous opacities causing some blurring of fundus details. Patch of chorioretinal disturbance down and in. No scar of wound of entrance can be found. Advised hospital, localization of foreign body, and attempt at removal. The foreign body was localized 10 mm. below, 2 mm. to nasal side, and 12 mm. back of center of cornea. On January 20, 1923, assisted by Dr. W. E. Grove, it was extracted under cocain anesthesia, through a T-shaped scleral incision about 10 mm. back of limbus and just to nasal side of inferior rectus. The scleral wound was covered with conjunctival flap; three stitches were inserted. The foreign body measured 2 by 1.2 by 1 mm.

January 25: Stitches removed, eye quiet.

January 26: V.R.E., 6/VII; L.E., 6/X-2; pupil slightly smaller, no increase in vitreous opacities.

January 30: Eye clearing up; pupil somewhat less dilated.

February 2: V.L.E., 6/LX, with +2.50 sph. = 6/XXX-1.

Fundus examination: Beginning retinal detachment down and in.

February 3: The patient returned to the hospital for treatment for detached retina. Rest in bed, compress, bandage, atropin, dionin, and pilocarpin sweats.

February 19: Left hospital two days ago. V.L.E., 6/LX, with +2.00 sph. = 6/XV. KI ordered in 5-grain doses. Stopped atropin; dionin continued.

February 23: V.L.E., 6/LX, with +2.50 sph. = 6/XII-2. Campimeter field taken under good illumination and with 9 mm. white object (Fig. 00). From this time on to March 10th practically no change, vision varied slightly, but with +2.50 sph. always came up to 6/XII. The pupil was becoming smaller and more active to direct and indirect light; color of iris clearing up. At this time it was advised that patient be given light occupation.

March 26: Pupils equal in size and the left reacted slightly to light, and actively consensually. Siderosis disappearing. V.L.E.,

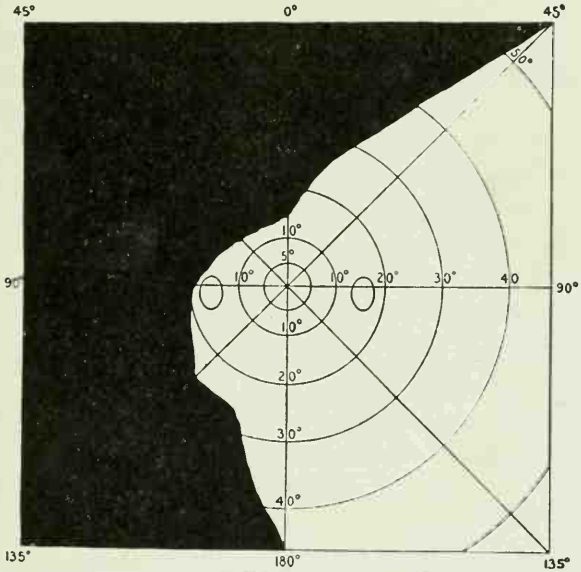

Fig. 2.—Field of left eye, April 26, 1923. Nine mm. target.

6/LX, with head slightly turned to left, with +2.50 sph. = 6/XII. Left pupil dilated with eucatropin to 7 mm. Fundus and vitreous opacities about the same.

April 26: The pupils were equal; the left reacted slightly to light but actively consenually. The iris was more nearly the color of that of the uninjured eye. V. = 6/CL, with +2.50 sph. = 6/LX. The pupil dilated with eucatropin and cocain to 8 mm.; no deposits on the capsule; lens clear. The vitreous was slightly hazy and there was practically no change in the detachment as evidenced by campimeter field (Fig. 2).

Why the vision at the last examination did not come up to that of the previous test, one month earlier, is surprising, as there was no apparent change observed in the fundus, and practically no difference in the size and contour of the field. The apparent loss of vision can be accounted for only by the fact that the patient was to appear before the Industrial Commission for settlement of his claim on the day of the last examination, and was extremely nervous and perspired freely.

There are a number of unsolved problems in the pathology of siderosis bulbi which are not only puzzling, but interesting. Why do some eyes escape discoloration of the tissues with retained iron or steel particles?

Why, in some instances, is the pupil unaffected, in others fixed, and in still others dilated and immobile?

Why do we have deposits in some eyes beneath the lens capsule, with or without the pupil changes?

It is understood by the writer that the many different kinds of iron and steel used in the industries vary greatly in their chemical composition. Is it not possible that siderosis bulbi develops only in case iron or steel of a certain composition is retained within the eye?

Some of the elements contained in the fluids of the eye of the host are certainly factors in producing siderosis. Is it not possible there is an individual difference in the composition of these fluids which may account for the variation in the end results?

It is suggested that those equipped for such investigation would find an interesting and important field for work in attempting to solve some of these problems.

REFERENCES

1. v. Graefe's Archiv, Bd. vi, 1, p. 134.
2. Über die Siderosis bulbi, Verhandlungen des X. Internationalen medicinischen Congresses, Berlin, 1890, Bd. iv, p. 151.
3. Leber: Transactions of the International Medical Congress, London, 1881.
4. Samelsohn: Zehender's Monatsblätter, 1881, p. 265.

5. Vossius: Deutsche med. Wochenschrift, 1891, No. 51, p. 1385.
Vossius: Bericht über die 29ste Versammlung der Ophthalmologischen Gesellschaft, Heidelberg, 1901.
6. E. v. Hippel: v. Graefe's Archiv, Bd. xl, Abteilung 1, 123.
7. Eisenberg: Inaug. Diss., Giesen, 1901; cited from Nagel's Jahresberichte, 1901, p. 680.
8. Natanson: Bericht ueber die 31. Versammlung der Ophthalmologischen Gesellschaft, Heidelberg, 1903.
9. Barkan: Ophthalmic Record, 1903, p. 115.
10. Hirschberg: v. Graefe's Archiv, Bd. xxxvi, 3, p. 37.
Hirschberg: Einführung in die Augenheilkunde, 2te Hälfte, p. 131.
11. Kipp: Amer. Jour. Ophth., 1906.
12. Gibson: Med. Jour. Australia, Sept. 7, 1918.
13. Tuckett: Brit. Jour. Ophth., Feb., 1918.
14. de Schweinitz: Ophth. Record, March, 1909.
15. Clegg: Ophthalmoscope, Oct., 1915.
16. Bednareki: Polish Przelad lekarski, Nos. 7, 8, 9, 10, quoted in Nagel's Jahresberichte, 1901, p. 190.
17. Bride: Ophthalmoscope, June, 1914.
18. Verhoeff: Brit. Jour. Ophth., Nov., 1918.
19. Easton: Lancet, June 20, 1914.
20. Mann: Amer. Jour. Ophth., 1920.
21. McCreight: *Ibid.*
22. Parsons: Pathology of the Eye, vol. iv.

DISCUSSION

DR. MARCUS FEINGOLD, New Orleans, La.: The last statement of the essayist that it is the kind of iron which would have some bearing on the different clinical manifestations is borne out by an experience which I had last year. One morning I enucleated two eyes with siderosis—both blind eyes. Both were at once placed in formalin, both were passed through alcohol for hardening, and both were placed into alcohol and put away for further working up in the future. To my surprise, I noticed a few weeks afterward that in the one bottle the alcohol had remained perfectly clear, while in the other one it had turned brown. This proves that in the one eye the iron was of the kind that rusts easily and chemically more active, while in the other eye the iron was of the inert, rustless kind.

DR. WILLIAM M. SWEET, Philadelphia: When Dr. Black wrote to me about the case I looked up my records and found nine cases of siderosis following foreign body injuries. In most of the cases vision was so poor that it was impossible to make any comparisons in reference to the reaction of the pupil. In only one instance was vision 20/70, and in that case the pupil reacted sluggishly.

I think the variation in the action of iron on the body tissues is due to the impurities in the metal. In the finer grades of iron the impurities are mostly removed, and the metal does not rust so

readily as in the poorer qualities of iron, such as are used in the cheaper grades of castings and sheets.

DR. ARTHUR J. BEDELL, Albany, New York: I have recently seen a patient with a dilated, immobile pupil following the removal of a piece of steel, in which pupillary reaction was restored. Eighteen months before, while using a mallet and chisel, he felt something strike his eye. He had been *x*-rayed several times, with negative results. He came in with one brown iris—the other was light gray-blue. With the microscope you could find the siderosis through the cornea, over the endothelial layer, over the iris, on the anterior capsule, in the lens, and in the anterior vitreous. He also had the typical rosette posterior cortical cataract. After removing the foreign body the pupil, which had been 7.5 mm., came down to 4.5. The final visual result was 20/100.

During the period of observation we could see the iron specks become smaller.

DR. T. C. LYSTER, Los Angeles, Cal. (by invitation): I had occasion recently to remove a piece of iron from a patient whose history was very much like that to which Dr. Black refers; but the pupil was not completely immobile, but was three-fourths dilated. After removal with a magnet—the foreign body was evidently in the vitreous and easily removed—it was found to be a fragment of a nail. The iris was a grayish-brown. Later it seemed as if the color began to change a little, the vision decreased to 4/30, and the pupillary responses began to improve. When last seen, the vision had returned to something like 50 per cent., then decreased to light and shadow.

DR. JOHN W. BURKE, Washington, D. C.: I have an opposite condition to report in a case of a piece of glass retained in an eye over a long period of time. A professor of physics in George Washington University in performing an experiment was injured by the explosion of a glass beaker in 1911. His eye was cut, but no foreign body was found. After a stormy convalescence his eye quieted down and has remained so since. About four months ago I saw this man in consultation for incipient cataract. In looking at the eye I saw a small, cyst-like bulging of the lower part of the iris, and on examination with the microscope found he had a piece of glass about 1½ mm. in diameter in his iris angle. He had a contracted immobile pupil on that side, with no synechia. I think in this case there were certainly no degenerative changes in the piece of glass, but that there were degenerative changes in the iris.

SUPPLEMENTARY NOTES ON LIPÆMIA RETINALIS: EFFECTS OF INSULIN

WILLIAM F. HARDY, M.D.
St. Louis, Mo.

Lipæmia retinalis appears to be less rare than the older literature indicates, due doubtless to a closer scrutiny at the present time of the eyegrounds of diabetics and the keen interest of the internist in seeking the co-operation of the ophthalmologist. The *raison d'etre* of the present report is provided by the advent of insulin in the field of therapeutics.

It is desirable to secure a sugar-free state in a patient requiring an intra-ocular operation. Since the recent introduction of insulin this condition can usually be brought about, rapidly and readily. To this extent, then, it has a direct bearing on ophthalmology. In a recent article by Root and Gray* two additional cases of lipæmia retinalis are described, bringing the total number of recorded cases up to 27. The case report credited to Benedict by these authors is a mistake, as Dr. Benedict in a discussion of McGuire's† paper only mentioned having observed the cases later reported by Wagener.

In 1921 I had the honor of addressing this Society on the subject of lipæmia retinalis and reported a case with full metabolic finding. Subsequent reports have been made by McGuire, Wagener (3 cases), and by Root and Gray (2 cases).

* Jour. Amer. Med. Asso., April 7, 1923.
† Trans. Amer. Ophth. Soc., v. 20, 1922, p. 235.

The patient described in my previous report died, a few months following my paper, after a short period of unrestrained carbohydrate indulgence. No further opportunity had been afforded for the study of his general or ocular condition. In February of this year (1923) a second patient with lipæmia retinalis was entered at the Barnes Hospital. As the use of insulin has been introduced since the previous case was observed, the report of the effect of the new procedure of Banting is not without interest.

The history is as follows: E. J. D., white, male, aged twenty-three years, was admitted February 13, 1923, in a state of coma. I saw the patient within two hours, the pupils having been dilated with homatropin in the interim. As soon as admitted, blood and urine were taken for examination. The centrifuged blood showed the tube apparently half filled with fat, indicating a marked lipæmia. The urine examination revealed considerable sugar and acetone. The arms, legs and scalp were covered with lesions of xanthoma diabeticum; breath strong of acetone; blood-pressure 130/70. The CO_2 Vol. per cent., less than 10; the lowest previous count with the patient surviving having been 16. The patient appeared to be in extremis and the ocular examination was interrupted to allow the last rites of the Church to be administered. The media were clear; some retinal edema was present, as evidenced by the absence of clear cut borders to the disc and vessels. The disc and vessels appeared the same color, no differentiation being made between arteries and veins, and the light streak was absent. The vessels looked as if filled with malted milk. As in the previous case reported there was no suggestion of a salmon pink color. The idea has been suggested that the appearance of the retinal vessels may depend on the size of the fat droplets and the state of their emulsification. No infiltrates or hemorrhages were noted. Thirty-three units of insulin had been given soon after entering the hospital. The next day (February 14th) the retinal edema had disappeared and the disc and vessels were well defined. The characteristic appearance of lipæmia retinalis, however, continued. Insulin was given daily and the intern noticed a return of the fundus to normal appearance on the 16th, which was confirmed by me on the 17th.

TABLE 1

	Blood Sugar	CO_2 Vol. Per cent.	Blood Fat (Bloor's Method)	Urine		
				Sp. Gr.	Sugar	$FeCl_3$
February 13, 1923	.305	10 (minus)	4.5 per cent. Cholesterol 1.8 per cent.	..	..	..
February 14, 1923	..	17.4		1016	14.87 grm.	++
February 15, 1923	.350	50	..	..	..	..
February 16, 1923	..	56.6	..	..	..	..
February 17, 1923	..	..	2.37 per cent.	1005	12.08 grm.	0
February 18, 1923	.266	..	..	..	..	..
February 25, 1923	..	..	2 per cent. Cholesterol 1.25 per cent.	1006	3.3 grm.	..
February 26, 1923	..	..	..	1007	0	0

Daily examinations and estimates of urine made and recorded but omitted here.

Red blood-corpuscles, on entrance 3,550,000; white blood-corpuscles, 16,000; Hb, 85 per cent.

Insulin Therapy. Daily quantity given in two doses.

February 13, 1923, 33 units on entrance. Characteristic fundus picture.
February 14, 1923, 110 units. Characteristic fundus picture.
February 15, 1923, 70 units.
February 16, 1923, 80 units. Fundi of normal appearance (intern's note).
February 17, 1923, 67 units. Fundi of normal appearance confirmed by writer.
February 18, 1923, 80 units.
February 25, 1923, 60 units.
March 11, 1923. Discontinued temporarily.

At the possible risk of tiring you I shall enumerate a few facts in connection with diabetes, acidosis, and lipemia which, though they indirectly affect our specialty, are seldom touched upon in ophthalmology. Diabetic acidosis is due either to overproduction or deficient utilization of diacetic and beta-oxybutyric acids. The essential cause of acidosis is

not known, as a definite relationship between it and internal pancreatic secretion has not been established; in fact, it is not known whether the acetone bodies are normal intermediate products or pathologic products. The acetone bodies producing acidosis represent imperfect combustion of fat and their formation is not from carbohydrates, as might be surmised, but, on the contrary, may be lessened or utilized by the ingestion of carbohydrates.

A rather close relationship exists between acidosis and carbon dioxid output, hence the latter when reduced below certain limits is an indication of the former. According to Allen the lowering of the carbon dioxid carrying power of the blood indicates a late severe stage of acidosis. Every case of diabetic acidosis is not accompanied by lipemia, but it may be said that virtually all cases of marked lipemia show an acidosis.

Fat normally is taken up by the tissues as fast as it is absorbed into the blood. The lipemia of diabetes represents an accumulation of food fat resulting from the tissues failing to take up and dispose of it in the usual normal manner.

During fasting the clear blood plasma contains about 0.7 per cent. of total lipoids and at the height of digestion the lipemia is between one and two per cent., mostly in the dissolved form. It does not seem logical that the doubling or even trebling of the lipemia of digestion can cause the visibility of an emulsion-like plasma in the retinal vessels. Either there must be some physical or chemical change in the fat droplets to bring this about or else the lower fat estimates in lipæmia retinalis have been erroneous.

In the present case I was slow to accept the laboratory estimate. The apparently very high fat content in the centrifugal tube specimen did not harmonize with the laboratory findings, the latter being 4.5 per cent. My previous impression that the fundus picture did not appear until the lipemia was considerably in excess of 5 per cent. must therefore be

revised if the lower laboratory figures are correct, and the true threshold placed between 3 and 4 per cent.

Lipemia in itself is not always of grave significance, but that combination of circumstances or phenomena which eventuate in the picture of lipæmia retinalis seems to mark the case as one of bad prognosis.

The substance isolated from the islands of Langerhans has been termed insulin; its presence is absolutely necessary for the maintenance of metabolic equilibrium. Diabetes is accompanied by degenerative changes in the islands of Langerhans, with a diminution or cessation of their important internal secretion. The question of metabolism and more so of pathologic metabolic states is so complex and involved that it is useless to speculate on how insulin acts in a beneficent manner, since relatively little is known concerning it Whatever may be the *modus operandi* in the production of lipemia, the clinical fact is very evident that insulin effects a rapid reduction in the blood fat and likewise a proper oxidation of fat and sugar with a disappearance of suboxidation products from the blood and urine.

The rapidity with which the fundus picture returns to normal by the administration of insulin is a most striking feature. The effect of the preparation in the case under discussion can be described by no less a word than miraculous. The patient was veritably snatched from the grave.

Owing to the fact that insulin is rendered inert when given by the mouth it must at present be given hypodermatically or intravenously. The dosage is flexible and suited to the individual case, 40 to 60 units being an average daily dose.

It may be found possible to prolong the lives of these patients for a considerable period by the use of insulin; without such therapy it can be said, with a degree of assurance, that death in coma is to be expected in a relatively short time.

DISCUSSION

DR. FRANCIS LANE, Chicago: To use the direct words of Dr. Frederick M. Allen, New York: "Insulin is the greatest discovery of modern medicine." I am particularly interested in insulin, principally because I have been a diabetic for five and a half years. A little over a year ago my weight was 117 pounds, partially due to the starvation diet called for because of stubborn high blood sugar. After the meeting of this Society in Washington last year, and after breaking diet, I went to Dr. Allen for the second time, with a blood sugar of over 1.250. This was the highest blood sugar he had ever recorded, and thought it could not be possible, inasmuch as my general condition was such as it was, but a subsequent test corroborated the original findings. At that time a blood-fat content was made, and no lipemia was found, so lipæmia retinalis does not always accompany high blood sugar. My refractive error is a minus one, but at the time the blood sugar was highest it was minus two, presumably due to a swollen lens. At the same time an edema of the retina must have been present which produced the sensation of sparks or fireflies before my eyes, whether open or closed.

Last August a baby dose of insulin—one unit a day—was given, but as the supply became larger and larger, the dosage was increased up to 100 units per day, with the result that all the symptoms have disappeared and to-day I weigh 193 pounds. Quite frequently I have experienced symptoms, ocular and constitutional, of hypoglycemia—the ocular symptoms were of heat-wave sensations and scintillating scotoma.

Insulin certainly is a drug which, while it is dangerous, when properly administered, along with a measured diet accordingly, will control high blood sugar and make ocular operations safe, whereas in pre-insulin days this was looked upon with disfavor. Let it be remembered that insulin, according to our present-day knowledge, is not a cure, but a most valuable remedy. It has been well said: "Once a diabetic, always a diabetic."

DR. GEORGE W. JEAN, Santa Barbara, Cal.: What insulin has done for Dr. Lane is marvelous. It is dangerous unless in the hands of specialists. Patients become too sugar-free. It has been used in the metabolic wards at Santa Barbara under Dr. Sansum since May, 1922. It can be given only hypodermically, therefore insulase and other products given by mouth are inert.

I have extracted several cataracts in cases of this character and do not worry about diabetic coma as I once did. When Dr. Sansum tells me to go ahead, I do not fear complications.

THE SIGNIFICANCE OF DEEP OCULAR PAIN IN RETINAL DETACHMENT

J. W. CHARLES, M.D.

St. Louis, Mo.

So much has been written in the last few years concerning different methods of operating for the purpose of releasing the subretinal fluid in detachment of the retina that it would seem to be important to at least sound a warning against indiscriminate operative interference in these cases. The dangers of any exploratory incisions in tumors, whether in the eye or elsewhere, cannot be emphasized too much; so that any new symptom or recalling the attention to an old symptom is not out of place if by it we may be helped to avoid jeopardizing the life of the patient by the almost hopeless attempt to restore vision.

If the detachment is caused by a small growth which cannot be discovered by transillumination, focal illumination, or the ophthalmoscope, then an operation which involved invasion of the tumor would endanger the patient by setting free tumor-cells which could cause metastases.

For this reason the attention of the Society is called to the following two cases in the hope that while not decisive they might prove to be at least suggestive.

The pains which I have been accustomed to designate as "sinus" pains in the eye are either sharp or dull aches referred by the patient to the orbit; they may be increased or relieved by pressure on the eye, depending on the individual; there may or may not be periosteal tenderness over one

of the sinuses; some of them resemble the aches of ciliary spasm, and we now know that some sinus pains are increased by reading or other close work.

On April 27, 1916, I was consulted by a lawyer, aged forty-eight years, who complained of a disturbance of vision in his left eye. There had been a clouding of the nasal field since he had been treated with atropin and cold in January, two months before, for an inflammation of the eye not accompanied by secretion. This treatment relieved pain and the eye became quiet. His physician had given him glasses recently. He had also been disturbed by a metamorphopsia. O.D., Hm 2.75, V.=23/19; O.S., Hm 2.75, V.=23/30. There was no astigmatism and his pupils reacted normally.

With the ophthalmoscope the right eye was normal. In the left eye there was a small exudate in the region of the macula with a retinitis toward the temporal side of the fundus and a retinal detachment still farther outward. The transilluminator demonstrated no obstruction of light. There was no nodular appearance in the detachment, and no tortuosity of the retinal vessels, such as is seen in tumors.

Final glasses for distance were R.E.,+1.50 sph.⊂+0.50 cyl. ax. 120°; L.E.,+1.50 sph.⊂+0.50 cyl. ax. 60°. On May 22d, one month later, there was no change, and the patient was warned that he must come monthly for observation because of the possibility of the presence of a new growth. However, he was a busy corporation lawyer and disappeared until September 4, 1917, or about fifteen months. Three days before, while on a train in the North, the left eye began to be very painful and he consulted Dr. Burch, of St. Paul, who wrote me the following: "Mr. ——— came to me this morning with acute glaucoma in the left eye from which I have tried to give him relief. The tonometric measurement of the left eye this morning is 56 mm. I have given him ½ of 1 per cent. eserin solution to use every two or three hours until he can reach home and see you."

My examination of the patient showed that the vision of the R.E.=23/15; L.E. = blind. Instillation of eserin every two or three hours. The tonometer of Schiötz gave R.E., 24 mm.; L.E., 44 mm. Systolic blood-pressure, 138. Diagnosis, acute glaucoma. Under constant treatment until September 20th, a little more than two weeks, the pupil came under control, the pain

was less, and the transilluminator gave a clear reflex through the region of the detachment; however, no details of the fundus could be obtained because of the very muddy media. A consultation with the late Dr. Alt confirmed my diagnosis and decision to perform an Elliot sclerocorneal trephining, not only in order to relieve pain but also in the hope that the media would clear up and permit some decision concerning the presence of a tumor, because the patient insisted on retaining the blind globe. This was done September 29th and was followed by an uneventful recovery, except that the media did not clear up as we had hoped.

During the after-treatment and observation which extended into January, the patient complained of a neuralgia which simulated sinus pains, especially those which occur deep in the globe—a nerve reference pain. He was referred to Dr. Sauer, who found his paranasal sinuses negative until January 26th, when the patient reported that he had become violently ill the night before and suffered great pain in and around the eye, but there had been no associated redness of the globe. He was again referred to Dr. Sauer, who found pus "pouring from everywhere" and a culture showed a "pure staphylococcus aureus." On the following day there was a beginning orbital cellulitis, and the patient was sent to the hospital. In three days the eye became immobile, the tissues tense, there was great pain and, while all the other sinuses had cleared up, Dr. Sauer found the sphenoid full of pus when he operated.

On February 1st a knife was plunged into the orbital tissue under the outer upper rim of the orbit through the skin, and then, after the lid had been lifted, the knife was again plunged parallel to the globe in such a manner as to reach the first incision. While only a minimum amount of pus was thus released, the tension of the tissues was relieved. The laboratory findings were at this time: Blood: Leukocytes, 16,000; red cells, 4,500; clotting time, five minutes; polymorphonuclears, 77 per cent.; polyeosinophiles, 1.0 per cent.; polybasophiles, 0.0; small lymphocytes, 13.0 per cent.; large lymphocytes, 3.0 per cent.; transitionals, 3.5 per cent.; large mononuclears, 2.5 per cent.; Wassermann, negative.

Urine: Acid, sp. gr. 1014, pale yellow, albumin, marked trace, sugar negative. Microscopic examination: Numerous hyaline and finely granular casts, a few leukocytes, no blood.

On February 8th, when the orbital cellulitis had cleared and the leukocyte count was about 10,000, the patient gave his consent to

enucleation and a spindle-cell melanosarcoma was found behind the ciliary region.

He remained very well for eight months, but in the fall he came with terrific pain in his abdomen. An exploratory operation by Dr. P. Y. Tupper showed the liver inoperable with metastases in the peritoneum and the patient died in a short time.

On June 2, 1920, Mrs. ——, aged forty-four years, consulted me for a change in her glasses. The pupils and fundi were normal. She was given for distance, R.E., +0.75 sph. ⊂ +1.00 cyl. ax. 180° = 23/15; L.E., +0.75 sph. ⊂ +0.25 cyl. ax. 180° = 23/15. For reading, the addition of +1.25 sph. to the above correction.

On October 19th the patient returned with a right supra-orbital headache, worse in the mornings, and with the vision 23/19 for the right eye and 23/38 for the left. Disc somewhat fluffy. There was a peculiarly shaped deposit on the posterior lens-capsule. The case was then referred to Dr. Dames, a competent rhinologist, who simply reported a "loss of drainage" much relieved by treatment. On November 3d the vision of the left eye was 23/24 or two letters better than two weeks before. The condition was unchanged on the 15th and the 30th.

On January 8th, after a long absence, the vision of the left eye was 23/24, but the ophthalmoscope showed that the vitreous was full of floating particles.

May 8th the patient reported that while in Chicago two days before the vision suddenly failed during the night. There was a very distinct blood-clot to be seen at the bottom of a detachment of the retina at the inferior quadrant of the fundus.

June 7th the area of clear retinal reflex above the clot was somewhat increased. The patient had been taking bichlorid of mercury since the appearance of the muddy vitreous in May, and had been under the care of the rhinologist. In July she went West and before she left she was again examined with the transilluminator and the detachment found to be clear of any obstruction to the passage of light.

On October 4th I again saw the case. She had been having deep neuralgia in the left eye and also reported that Dr. Hans Barkan, in San Francisco, had found negative results with the transilluminator.

The exudate behind the detachment had no definite outline by

focal illumination and the ophthalmoscope. She was very nervous and depressed because of a deep "neuralgia" in the left eye. Owing to the limited time conceded for examination the transilluminator was not used.

I again saw the patient on December 5th. In the lower quadrant of the fundus there was a rounded pigmented growth which had just been discovered by Dr. J. B. Ellis, of Chicago. Since they were moving to Chicago I advised them to have the eye enucleated by Dr. Ellis at once and he reported to me that macroscopically there was a pigmented growth in the position established in the clinical examinations.

The microscopic examination, conducted by Dr. E. V. L. Brown, under adverse circumstances, seems not to be very conclusive concerning the diagnosis. With his permission it is here reproduced:

"Paraffin sections from the thin edge of the large mass in the lower anterior temporal chorio-retinal wall of the eye show a 4–5 mm. stretch of densely nucleated, sharp-staining tissue doubling the normal width of the chorioidea and occupying all layers from the sclera to the limitans basalis. Representing, as it does, the thinned-out edge of a massive new formation, it is not surprising that the portion in front and behind the 4–5 mm. mass is found extending not into nor between the layers of the chorioidea, but between the chorioidea proper and the sclera, along the line of least resistance, in the perichorioidea. This also accounts for the fact that where the chorioidea is most widened there are no vessels between the sclera and limitans basalis and that immediately adjoining this avascular area large vessels (only) are seen (pathologically) near the limitans basalis; from this it may be concluded that choroidal vessels are only secondarily concerned in this part of the new formation. Where compressed (between the limitans basalis and sclera), the cell nuclei are oblong in shape with rounded ends, non-granular nuclei, without mitotic figures, and the cells seem to have no marked tendency to extend into protoplasmic processes. Where cells are less compressed, the body is quite large though scarcely of squamous-cell size in proportion to the large nucleus. No increase of pigment is found in between the cells. No evidence of inflammation is found.

"From these sections one may diagnose a malignant tumor of the chorioidea, but cannot say whether it be a carcinoma or sarcoma. The history, the extension in the perichorioidea, its non-vascular nature, and the lack of pigment speak for carcinoma, but

the growing margin of an endothelial type of sarcoma might present the same features.—E. V. L. Brown."

Some time later Dr. Brown sent me several sections taken from the more central parts of the tumor which show an undoubted melano-fibro-round-cell sarcoma originating from the choroid, the diagnosis being confirmed by Dr. George Ives.

This report has been presented, not to establish a fact or theory from two cases, but in order to learn from the members present whether they have had cases of retinal detachment, accompanied by these non-glaucomatous pains, which finally exhibited an intra-ocular growth; and also in a case of such detachment whether one would be justified in operating to release subretinal fluid.

BILATERAL DETACHMENT OF THE RETINA IN TWO SUCCESSIVE PREGNANCIES

EMORY HILL, M.D.
Richmond, Va.

A woman, aged twenty-eight years, was delivered of her first baby in November, 1917. Her blood-pressure and urine were normal, and Wassermann negative. Pregnancy was uneventful until the day before labor began, when she was nervous, developed delusions of persecution, and had to be committed to an asylum for the insane for a period of several months. Two subsequent pregnancies resulted in two normal babies who have lived. This history was obtained from the obstetrician, Dr. M. P. Rucker.

On November 9, 1921, I was asked to see this patient in the obstetric ward of the Virginia Hospital, where she had been admitted in the sixth month of pregnancy in a preëclamptic state, with generalized edema, blood-pressure 245/140, and albumin and casts. Vision had been failing for one week and was reduced to light perception. Both retinas were detached in the lower half, reaching forward 10 D., with flat detachment above, much retinal edema, exudates and hemorrhages, and slight swelling of the nerve heads. Immediate delivery was advised and carried out by the obstetrician, Dr. Greer Baughman, by means of the

Vorhees bag. Twin fetuses were born and died in a few hours. The detachments increased in the next forty-eight hours, when scleral punctures were made. Three days later the right retina was almost *in situ* and the detachment of the left had subsided from 10 to 8 D. Blood-pressure fell to 160/130. She left the hospital two days later, contrary to advice. When seen at her home in the country one week afterward, only flat detachments were found far forward and the edema and hemorrhages were less. Vision = fingers at 5 feet. She had been out of bed attempting to care for her children and could not be persuaded to do otherwise or to report later at the dispensary. Nothing more was heard of her until the complications of another pregnancy forced her to the hospital.

On April 25, 1923, I was asked to see an eclamptic patient in the Sheltering Arms Hospital who complained of blindness. This proved to be the same woman, again in the sixth month of pregnancy, with generalized edema, blood-pressure 240/140, albumin and many granular casts; she had had two convulsions and apparently had been blind for two weeks. The conjunctivæ were chemotic, the pupils 5 mm. wide and fixed, the retinas detached, the right, elevated 10 D. below, reaching nearly to the disc, and 5 D. above; the left, 12 D. above and below, leaving a narrow cleft through which the disc could be seen. The undetached portions were edematous, a few hemorrhages were seen, and the nerve heads were white, with considerable exudate and irregular edges. The retinal arteries were very narrow and the veins were greatly engorged, suggesting thrombotic obstruction. Immediate delivery was advised and carried out by the obstetrician, Dr. M. P. Rucker, by means of the Vorhees bag. A six months' fetus was born alive, but died in a few hours. The next day three scleral punctures were made beneath the high detachments, one in the right eye and two in the left. Gradual subsidence followed in the next forty-eight hours (from 12 to 8 D.), and the blood-pressure decreased to 200/120. No return of vision had occurred at this time and the patient refused to stay longer in the hospital despite the urgent warnings of the obstetrician and myself.

The sad circumstances of this case were made worse by the poor mentality of both the patient and her husband, who insisted that vision would return when they could reach home and use an eye wash. On May 29 Dr. Joseph A. White saw the patient and found the following condition: Both eyes blind; tension normal;

pupils dilated and fixed; scars of former retinitis, and secondary atrophy of the nerves; retinal veins normal in the central area but contracted at the periphery; arteries extremely narrow; no detachment of the retina in the right, but a detachment on the nasal side in the left eye covering the disc.

Despite the tendency of such detachments to subside after delivery it seemed safer to do scleral punctures and release the subretinal fluid promptly. There was very little prospect of vision after the last pregnancy because of optic atrophy, but it was hoped that the blindness might be in part cerebral and some return of vision possible if the retinas should become reattached within a short time.

The recurrence in a second pregnancy is unique so far as I can discover in the literature. Clapp[1] refers to a case of Baduel, mentioned by another writer as an example of slight detachment recurring in five succeeding pregnancies; but this is a mistake. Baduel's[2] original report deals with recurrence of slight retinal detachment at several menstrual periods.

Text-books make but brief mention of this condition, and references in the journals are comparatively few. Polte, for example, discussed the subject of eye lesions in pregnancy and the puerperium in 1906, on the basis of 200 cases examined, and did not mention retinal detachment. Other lesions associated with eclampsia and nephritis of pregnancy are frequently noted, but detachment is inconspicuous among them. Probably this occurs more often than we have believed. The attention of obstetricians is directed to eclampsia or nephritis and eye-grounds are not always examined. Slight detachment far forward may not be detected without wide dilatation of the pupils, especially in the presence of convulsions, and it may recede before postpartum examination is made. In twelve years I did not see this occurrence, whereas three cases have come under my observation, and another has been seen by a colleague, Dr. W. L. Mason, in a space of eighteen months since an examination of eye-

grounds has been made a routine in the study of the toxemias of pregnancy in the obstetric wards. Clapp saw six cases in a similar period in the maternity wards in Baltimore, though he had not seen any cases previous to 1917. Bernard[3] refers to 24 cases occurring with the retinitis of pregnancy, all of which subsequently showed reattachment, some recovering normal vision. In this country, Wadsworth,[4] Greenwood,[5] Cohen,[6] Posey[7] and Blake[7a] have reported single cases. R. Foster Moore[8] collected 17 cases and refers to Heilbron's report of 21 cases. Moore summarizes his conclusions, from a most thorough review of the subject, as follows: Detachment is by no means an uncommon complication of renal retinitis and is especially frequent in the retinitis of pregnancy. It is usually bilateral (40 of 44 cases); nephritis in the absence of retinitis is not a cause; the liability to detachment is in proportion to the severity of the retinal changes; it does not depend upon the presence or absence of general edema; the immediate cause is a subretinal exudate which is derived from the retina and not the choroid; the appearance differs according as the exudate is solid or fluid (flat or lobulated detachment). If the patient recovers, reattachment occurs, unless gross tears allow the vitreous to pass beneath the retina. After recovery permanent visual defects and fundus changes probably always remain. The intra-ocular tension is not raised.

Schiötz[9] has recently reviewed the subject in great detail. Of 680 patients in the Christiana Clinic, 132 were eclamptic and 26 preëclamptic. Twenty-seven of these had retinitis or papilloretinitis, four of whom had retinal detachments. Recoveries were remarkable. Twenty cases which could be followed showed perfect health, without albumin or increased blood-pressure, though 13 had become pregnant again. Schiötz considers the prognosis for sight good in those who survive the eclampsia, though he seems to regard retinal detachment as the chief source of permanent visual loss. He

found evidence of nephritis largely a concomitant of pregnancy, being generally absent both before and after the pregnancy. This supports the opinion prevailing to-day, as expressed by Black,[10] that the retinitis of pregnancy is not albuminuric, nor a true inflammation, but it is the result of syncytiotoxins which are not eliminated.

Generalized edema is frequent in eclampsia, and cerebral edema is sometimes conspicuous. Baehr[11] believes that the latter explains the coma and convulsions. Zangemeister[12] has reviewed the various theories advanced to account for eclampsia and gives convincing arguments for believing it to be due to cerebral edema. He draws a close parallel between the symptoms of increased intracranial pressure, seen clinically and produced experimentally, and those of eclampsia, and states that he has observed the edematous brain after trephining the skulls of eclamptic patients. Lumbar puncture has been practised and advised by Wilson[13] and Snyder.[14] Clapp refers to the similarity of the fundus picture seen in the toxemia of pregnancy (blurred disc edges and retinal edema) to that seen in cerebral edema accompanying fractures of the skull.

It has long been a dictum of ophthalmologists that threatened blindness demands the induction of labor. A further suggestion of value to the pregnant woman is that examination of the eye-grounds should be made in every case of toxemia of pregnancy and this should be done with mydriasis. The presence of marked edema, intra-ocular and intracranial, suggests the propriety of lumbar puncture in addition to the interruption of pregnancy for the more rapid relief of eclamptic symptoms.

REFERENCES

1. Clapp: Detachment of the Retina in Eclampsia and Toxemia of Pregnancy, Amer. Jour. of Ophth., vol. ii, 1919, p. 473.
2. Baduel: Rivista Critica de Clinic Medica, 1902.
3. Bernard: Spontaneous Cure of Retinal Detachment, Klin. M. f. Augenh., March, 1911, p. 379.
4. Wadsworth: Trans. Amer. Ophth. Soc., 1887.

5. Greenwood: Ophthalmology, 1905, p. 8.
6. Cohen: Trans. N. Y. Acad. Med., Ophth. Sec., March, 1914.
7. Posey: A Case of Extreme Edema of the Retina with Extensive Detachment Below, Ophth. Rec., vol. xxiv, 1915, p. 258.
7a. Blake: Bilateral Detachment of the Retina in Nephritis of Pregnancy, Arch. Ophth., v. li, Nov., 1922.
8. Moore: The Retinal Detachments of Renal Retinitis, Royal London Ophth. Hosp. Rep., vol. xxii, 1915–16, p. 262.
9. Schiötz: Pregnancy Retinitis and Amaurosis, Klin. M. f. Augenh., vol. lxvii, 1921.
10. Black: Ocular Manifestations in Pregnancy, Wisconsin Med. Jour., vol. xxii, 1921, p. 181.
11. Baehr: Edema of the Brain, Lancet Clinic, vol. cxii, 1914, p. 696.
12. Zangemeister: Eclampsia, the Result of Increased Intra-cranial Pressure, Zeit. f. Geburt. u. Gynecology, vol. lxxix.
13. Wilson: Lumbar Puncture for the Relief of Convulsions in Puerperal Eclampsia, Jour. Amer. Med. Asso., vol. lxvii, 1916, p. 742.
14. Snyder: Eclampsia and Lumbar Puncture, Jour. Amer. Med. Asso., vol. lxix, 1917, p. 1074.

DISCUSSION OF DRS. CHARLES AND HILL'S PAPERS

DR. A. L. MACLEISH, Los Angeles, Cal.: To Dr. Emory Hill's most remarkable and sad case I should like to add one of happier outcome, which I saw in consultation with Dr. J. Ross Reed, of Pasadena, to whom I am indebted for the history of the case and for permission to report it.

A young woman, seven months pregnant, had a sudden dimming of vision following a uterine hemorrhage. Two weeks later, vision having only partially improved, Dr. Reed was called to see her, and found edema of both retinæ, rather more marked near the discs, no hemorrhages or exudates, but some vessels nearly covered by the swollen retinæ. Following this, the patient developed an eclampsia, with high acidosis, and blood-nitrogen of 50 mg. per 100 c.c. The uterus had been emptied by Cesarean section, and intravenous injections of alkaline solutions used to combat the acidosis. Vision still remaining dim, Dr. Reed was called again to see her, two weeks after the Cesarean section, and called me in consultation on the following day. There is now a marked optic neuritis of each eye, the discs swollen and striated, the striations extending over the adjoining retinæ, which are extensively edematous, especially the right; vessels engorged, especially the veins, which in places are buried in the swollen retinæ; a few small tufted hemorrhages are visible in each fundus. In each eye there is a large bullous separation of the retina, occupying a great portion of the lower segment of the globe, more prominent in the right, in both wrinkled and grayish. The right detachment is bounded above by a sharp curved

border, rising abruptly to 8 to 10 D. The left is flatter, well defined in the center, but at each end fading down into the normal situation, with less abrupt border; at highest elevation taking 6 to 8 D.

We decided to use a light elastic pressure-bandage over the eyes, and trust for the rest to the efforts of her physicians to improve elimination. At the end of two weeks of this treatment the detachment in the left eye had completely disappeared; that in the right eye was still fairly large, while the neuroretinitis had greatly subsided. Three weeks later the discs were nearly normal in appearance and the vessels free of engorgement, the retinæ completely back in position.

Three and a half months after the Cesarean section I had an opportunity to examine the eyes. The fields were normal, with no contraction, and no scotomata, absolute or relative. The discs were rosy, free of swelling, but a little blurred at the edges. All over the fundi, not only in the areas of the detachments but in the upper segments as well, there were found a light choroidal marbling and blotchiness, with a little pigment-heaping, but no marked atrophy. A few spots of retinal pigment deposit were found, with a delicate striation, indicating the upper boundary of the detachment in the right eye. Vision, with correction of a low grade hyperopic astigmatism, was 6/6 in each eye, and this has later improved to 6/5 in each eye, binocularly 6/4 plus 3.

DR. C. A. CLAPP, Baltimore, Md.: Since reporting six cases of retinal detachment in pregnancy in 1919 I have seen but one case. I have had the pleasure of following one of these cases in a subsequent pregnancy. That case showed no detachment nor any toxic symptoms in the second pregnancy.

As to treatment, the first case I saw I gave active treatment and there was rapid reattachment. The next six cases had no local treatment and the reattachment was just as rapid as in the first case that received treatment; so from my personal experience I believe that local treatment is not necessary, and that all practically reattach with normal field of vision.

With reference to Dr. Hill's mention of my report in which I refer to the five detachments reported by Baduel, I am unable to vouch for the accuracy. The original article was obtained from the Surgeon General's library, and the translation was made by one of my Italian medical friends, and that is the translation he submitted. I am unable to read Italian myself.

DR. ALLEN GREENWOOD, Boston, Mass.: Dr. Hill very kindly referred to a case I reported many years ago, at which time I gave a résumé of the literature. I think it is well for the members of the Society to carry away with them the very firm conviction that these cases do not, as a rule, need scleral puncture. Perhaps Dr. Hill's cases may have needed it, but practically the whole literature on the subject emphasizes the fact that such retinal detachments have always become reattached without operative interference.

DR. JOHN GREEN, JR., St. Louis, Mo.: The question has arisen as to the wisdom of scleral puncture in cases of detachment of the retina in which one may expect from the symptoms that there may be tumor. I had a case of this character some years ago in which there was complete detachment of the retina, but the history indicated that there might be a small growth at the posterior pole. Two scleral punctures were made and after the second one (a week after the first) a very small sarcoma was made out at the posterior pole. Of course, I was then justified in enucleation. The case was also complicated by the fact that the tension in this eye was minus—I think it was about 12 as compared with 18 in the other eye. Of course, there is no question but what there is a possibility of disseminating the tumor throughout the body by such procedure, and this should be taken into account. But I do not know of any other means of establishing a diagnosis as between simple detachment and detachment incident to growth at the posterior pole, unless possibly the transilluminator of Dr. Lancaster may be available. I would like to hear from Dr. Lancaster whether in the presence of total detachment information could be obtained from posterior transillumination.

DR. W. B. LANCASTER, Boston, Mass.: I have had no personal experience in such a case. I think a negative result would not be convincing. Of course, if you found a spot, a circumscribed area, where the light did not pass through, that would be very convincing. But if you had no guide as to where to place the transilluminator and had to try all over the globe, it would be rather an extensive procedure.

DR. E. V. L. BROWN, Chicago: I had the pleasure of seeing Dr. Charles' case clinically as well as anatomically. It emphasizes how quickly a pathologic area under suspicion can change from one in which no positive diagnosis can be made, to a very positive condition. Dr. Charles found a detachment without evidence of tumor

in April, 1921, and Dr. Hans Barkan corroborated these findings in September. Seven or eight weeks later a tumor nearly a centimeter in size was found successively by Dr. J. B. Ellis, Dr. W. H. Wilder, and myself.

DR. J. W. CHARLES (closing): From the fact that the gentlemen have not said anything about deep pains in retinal detachment, I take it that my query is answered and that it is an unusual thing to have deep pains which are non-glaucomatous in tumor of the eye.

The first of these cases gave negative sinus findings until an acute infection occurred, while the second gave positive nasal findings to account for the original right neuralgia. The nose seemed normal when the pain began to appear on the side of the detachment. Both eyes were hypermetropic.

DR. EMORY HILL (closing): Just a word in regard to the question of whether something should be done to release the fluid behind the retina. It seems to me logical to do it, but practically it does not seem to be necessary. The removal of the fluid ought to bring about a more prompt reattachment, and, presumably, the more quickly the reattachment occurs the better will be the visual result. My case would not prove this to be true by any means, and I doubt if I should do a scleral puncture in another such case. On the contrary, it is rather a simple thing and I see no objection to it.

OBSERVATIONS ON PHACOANAPHYLACTIC ENDOPHTHALMITIS*

ALBERT N. LEMOINE, M.D.
Boston, Mass.

ALEXANDER E. MACDONALD, M.B. (TOR.)
Boston, Mass.
(By invitation)

A report on 168 patients tested intradermally for hypersensitiveness to lens protein, including 14 patients giving positive reactions, 8 of which developed intra-ocular inflammation, and 2 patients successfully desensitized and operated upon for immature cataract by the ordinary method.

* From the Massachusetts Charitable Eye and Ear Infirmary, Boston.

At the recent International Congress of Ophthalmology held in Washington, Verhoeff and Lemoine[1] showed that about 8 per cent. of individuals are hypersensitive to lens protein, as demonstrated by the intradermal test for protein hypersensitivity. It was further shown that individuals who are hypersensitive to pigs' lens protein are also hypersensitive to the protein of their own lenses, and that where there is a rupture of the lens capsule, traumatic or operative, in such individuals, there results an intra-ocular inflammation which Verhoeff and Lemoine have termed Phacoanaphylactic Endophthalmitis.*

Further, they showed that eyes affected with phacoanaphylactic endophthalmitis have a characteristic histopathologic picture which apparently they have reproduced in animals sensitized to lens protein.

In a more recent paper the same authors[2] showed that an individual hypersensitive to lens protein could be desensitized and successfully operated upon, for immature cataract, by discission and linear extraction.

In the work of Verhoeff and Lemoine, pig, ox, and human lens proteins were used, and both dermal and intradermal tests were employed. In the present work pigs' lens protein and intradermal tests were used exclusively. The methods of preparing the lens protein and of making the tests were essentially the same as those employed by Verhoeff and Lemoine in their later work and were as follows:

Pigs' eyes are obtained as soon as possible, certainly not later than four hours after the animal is slaughtered. The anterior part of each eye is sterilized by flaming in a Bunsen burner; or, better still, by heating a small piece of metal until red hot and singeing the cornea and the surrounding tissues

* In a discussion on cataract extraction before the Ophthalmic Section of the American Medical Association in 1921 Dr. Verhoeff first called attention to the probability that intra-ocular reaction following cataract extraction was, in some cases, due to hypersensitiveness to lens protein. His remarks on this subject were omitted from the published transactions.

for a distance of about one cm. beyond the limbus. A corneal incision, similar to a cataract incision, is made, followed by a capsulotomy. The lens is then squeezed out of the eye into a sterile mortar. The latter is wrapped in two layers of sterile cloth and the lenses allowed to dry in a warm place. The process of desiccation requires twenty-four to seventy-two hours, depending upon atmospheric conditions. One with good laboratory facilities may use an air-tight calcium chlorid chamber. The lenses are then pulverized to a very fine powder with a sterile pestle. The powder is put up in amounts of 0.03 gram in sterile ampules. These can be made by drawing out 3/8 inch test-tubes. After the weighed quantity of lens powder has been added, the ampule is sealed by heat. When a solution is desired (as a matter of fact, only about one-half of the protein goes into solution, the other half remains in the form of a suspension), the top of the tube is broken, and 1 c.c. of fresh* sterile normal saline solution is added. This makes a 3.3 per cent. solution when computed in terms of powdered lens protein, or a 10 per cent. solution in terms of fresh lens protein.

In making the intradermal test, 0.04 c.c. of the above (1:10) solution is injected between the layers of the skin with a Luer tuberculin syringe. For the control, normal saline solution is injected in the same way and amounts, at least 8 cm. away from the area chosen for the test. Following are the symbols employed in recording the reactions:

++++ = a reaction with an area of erythema over 6 cm. in diameter, with an area of elevation at point of injection 1 to 2 mm.

+++ = a reaction with an area of erythema from 4 to 6 cm. in diameter, with some elevation at the point of injection.

++ = a reaction with an area of erythema from 3 to 4 cm. in diameter, and a moderate elevation at the point of injection.

* The normal saline solution should be fresh, as on standing it becomes slightly acid and irritating to the skin.

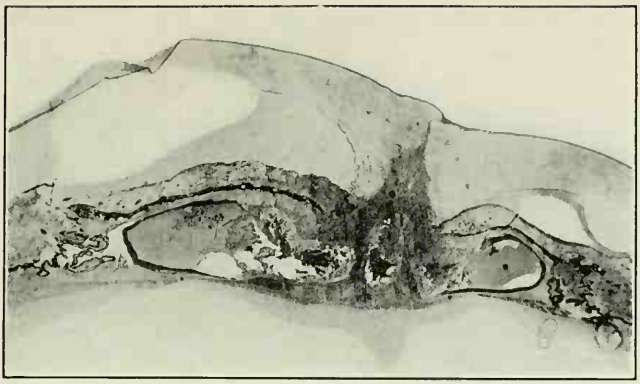

Fig. 1.—Showing wound in cornea, with cone-shaped mass extending from the posterior surface of the lens to the center of the cornea, with purulent infiltration of the cataractous lens-substance.

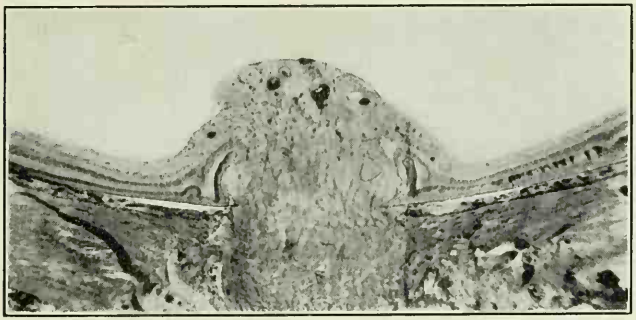

Fig. 2.—Showing extreme swelling of the optic disc.

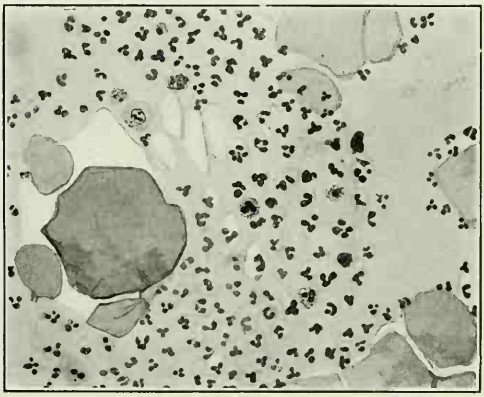

Fig. 3.—Showing infiltration of the cataractous lens with pus; endothelial cells and eosinophiles surrounding the hyaline balls of cataractous lens.

+ = a reaction with an area of erythema from 2 to 3 cm. in diameter, with a slight elevation at the point of injection.

± = a reaction with an area of erythema less than 2 cm. in diameter, with very little elevation at point of injection, but definitely more marked than in the control.

− = when the control and test areas are practically the same.

In a great many cases there is a reaction within a half hour, which in some cases disappears within an hour. The latter cases are considered negative. Only reactions which persist for at least twenty-four hours are considered positive. Occasionally the reaction is delayed twelve to twenty-four hours. These cases are also considered positive.

Before desensitizing a patient one must first ascertain the degree of hypersensitiveness. This is accomplished by making a differential intradermal test—*i. e.*, by making the tests in three or more dilutions—as follows: 1:10, 1:100, 1:1000, etc., solutions of lens protein, computed as of fresh lens. The first desensitizing injection should consist of 0.2 c.c. of the solution giving a ± reaction.

The subsequent injections are given at intervals of seven days, which interval is the same as that used by Dr. Walker[3] in his work with various other proteins, the dose being doubled each time until 1 c.c. of the full strength solution is injected. At this time the patient should give a negative reaction to the full strength solution and may now be operated upon.

As shown by Verhoeff and Lemoine,[2] it is best to continue the injections with the maximum desensitizing dose at weekly intervals after the operation, until the cortical matter is practically all absorbed, as the desensitization is apparently not permanent.

The purpose of this paper is to report the results of the intradermal tests with lens protein in 168 unselected cases of injury to the lens, traumatic or operative, with the end results in the operated eyes.

In none of the cases having a negative skin test, 144 in number, was there any subsequent intra-ocular inflammation, except that in a few cases there was delayed convalescence, due to unavoidable accidents, such as loss of vitreous or loss of the eye due to definite infection. These negative cases, also, include several cases of traumatic cataracts in patients in middle life, whose lenses absorbed entirely without any intra-ocular inflammatory reaction.

There were ten cases in which there was a ± reaction. Eight of these patients made an uneventful recovery. In one of the remaining two, in which considerable cortical matter was left, there was a marked delay in convalescence, and later secondary glaucoma; in the other there was simply delayed convalescence with an ultimately good end result.

There were 14 cases in which the test to lens protein was positive, the reaction varying from + to ++++. They are briefly summarized below:

CASE 1.—Mary M., 38474, female, white, aged fifty years, admitted to the service of Dr. MacDonald August 12, 1922, with mature cataract of the right eye and immature cataract of the left. Physical examination negative.

August 14. Right eye, combined cataract extraction with peripheral iridectomy. No vitreous lost. Anterior chamber irrigated. Little, if any, cortical matter left.

August 15. Little reaction. Anterior chamber reformed. Atropin instilled. Double dressing.

August 25. Pupil funnel shaped, anterior chamber deep, pupil does not dilate with atropin, due to complete posterior synechia.

August 28. Discission, right eye.

September 2. Discharged. Eye white and quiet. Pupil poorly dilated.

V.R.E., +11.00 sph. ⊂ +3.00 cyl. ax. 180° = 20/30; V.L.E., fingers at 4 feet.

Lens protein test not done on this service in August.

October 21. Readmitted for extraction of immature cataract, left eye. Lens protein test, +++. Dr. Verhoeff recommended that the patient be desensitized to lens protein before the operation was attempted.

October 26. Graduated tests with lens protein: 10 per cent. = +++; 1 per cent. = ++; 0.1 per cent. = +. Beginning same date, a full graduated desensitizing course of lens protein was given intramuscularly, alternating right and left deltoid muscles, at weekly intervals.

December 10. Differential intradermal test with lens protein was negative with all dilutions.

December 12. Readmitted for operation. V.L.E., fingers at 3 feet. Iris shadow present. The fundus reflex is seen about the nucleus.

December 13. Left eye, combined cataract extraction with peripheral iridectomy. Van Lint and subconjunctival injections and Verhoeff suture. Anterior chamber was irrigated, but a large amount of cortical matter was left. Iris slightly traumatized, owing to tendency of nucleus to protrude through the hole in iris.

December 15. Eye rather painful. Pupil not well dilated. Anterior chamber reformed. One per cent. atropin instilled daily. Double dressing.

December 18. Pupil not well dilated. Four per cent. atropin instilled.

December 21. Small synechia at four o'clock. One c.c. of a 10 per cent. solution of lens protein injected intramuscularly.

December 25. Synechia has partly separated. Eye whiter and quieter.

December 28. Discharged. Eye white and quiet. There is a small synechia at four o'clock, with some cortical matter remaining. Owing to the presence of the cortical matter the fundus cannot be seen. One c.c. of a 10 per cent. solution of lens protein intramuscularly. V. = fingers at two feet. Not improved.

January 4, 1923. One c.c. of a 10 per cent. solution of lens protein intramuscularly.

January 11. Received 1 c.c. of 10 per cent. solution of lens protein intramuscularly.

January 22. V.R.E., +11.00 sph. ⊂ + 1.50 cyl. ax. 180° = 20/20 −2; V.L.E., + 12.00 sph. ⊂ + .75 cyl. ax. 30° = 20/20−2. Received 1 c.c. of 10 per cent. solution of lens protein intramuscularly.

Eyes white and quiet. Tension normal.

Case 2.—Georgianna F., 38995, female, aged thirty-five years, admitted to the service of Dr. Ryder September 8, 1922.

Previous History: March 2, 1921, the patient had a combined cataract extraction for a nearly mature cataract of the right eye, and was discharged fifteen days later with a congested eye in which considerable cortical matter remained. The out-patient department records show that on April 9th an iritis was present in the right eye.

April 12. Uveitis, right eye.

June 14. An atropin dermatitis had developed from a 1 per cent. solution of atropin t.i.d. The eye was still inflamed and painful.

July 7. Posterior synechiæ and irregular pupil.

September 8, 1921. Discission right eye, as a result of which the eye was still inflamed on October 21.

Physical examination was negative. Lens protein test, +++. V.R.E. with correction was 15/200; L.E. = fingers at two feet, not improved.

Local Examination: Drawn pupil, right eye. Immature cataract, left eye. Lateral nystagmus.

September 9, 1922. Attempted intracapsular cataract extraction, left eye, during which the lens capsule ruptured, and the operation was completed by the ordinary method, leaving much cortical matter.

September 15. Patient gradually developing congestion, pain, photophobia, and lacrimation. In spite of treatment with atropin, dionin, and hot fomentation, the condition became worse, and a descemetitis developed. Pupil will not dilate. Patient has an atropin irritation and hyoscin hydrobromid 1/3 of 1 per cent. was substituted. Paracentesis performed.

October 16, 1922. No relief following paracentesis.

October 22. Descemetitis, congestion, pain, and photophobia are all more marked. Dr. Ryder advised desensitization to lens protein. The graduated intradermal tests with lens protein were positive as follows: 0.1 per cent. = +; 1 per cent. = ++; 10 per cent. = +++; one hour after the tests were made.

October 23. Twenty-four hours after tests were made they were positive as follows: 0.1 per cent. = ++; 1 per cent. = +++; 10 per cent. = ++++.

From October 23d to December 20th a full course of desensitizing intramuscular injections of lens protein was given. Twenty-four hours after each injection the patient had an exacerbation of pain, photophobia, and lacrimation, followed on the third or fourth day by amelioration of symptoms. At the completion of the course the

graduated intradermal tests were still all positive and further attempts to desensitize the patient were abandoned. Discharged on January 2, 1923. Eye congested, descemetitis marked, and pupil drawn up; cortical matter still present. Pain persisted, also photophobia and lacrimation. V.L.E. = light projection, faulty.

Case 3.—John G., 39549, male, aged forty-seven years, admitted to the service of Dr. Derby on October 5, 1922, complaining of loss of vision, right eye.

Past History: Had scarlet fever at age of twelve years. At the age of nine years had an injury to left eye that never caused him any marked trouble, except occasional irritation and pain. The left eye was enucleated at the age of thirty-five on account of recurring irritation and pain.

Present Illness: On December 14, 1921, he was struck in the right eye by a piece of wood, which immediately destroyed the vision. An iritis developed which lasted six weeks. On March 31, 1922, the patient was referred to Dr. Derby for extraction of the resulting traumatic cataract. An iritis followed the extraction which lasted three weeks.

Local Examination: Right eye, lids and lacrimal apparatus apparently normal. The cornea had a scar at 5.30 o'clock, extending from 2 mm. from the limbus toward the center for a distance of 2.5 mm. There was an operative scar in the limbus above. The anterior chamber was shallow and the iris was incarcerated in the traumatic corneal scar. The pupil was drawn up and occluded by a membrane extending to the limbus above and filling the coloboma, which was slit-like. No fundus reflex was seen. Physical examination negative. V.R.E. = good light projection. L.E., anophthalmos. Lens protein test = ++.

October 6. Right eye, iridotomy and separation of anterior synechiæ, by Dr. Derby. Dressed with double bandage and atropin ointment.

October 9. Little reaction. Good anterior chamber. Atropin instilled daily.

October 12. Eye quieting nicely.

October 16. Discharged. Eye white and quiet. Good anterior chamber. Has vitreous opacities, apparently from old hemorrhage. On discharge, V. with + 12.00 sph. = 20/200. Patient not seen since discharge.

CASE 4.—Charles K., 38113, male, white, aged twenty-seven years, admitted to the service of Dr. Thompson, July 24, 1922, with traumatic cataract of the left eye. V.L.E. = good light projection. Physical examination, negative. Lens protein test, 10 per cent. solution = ++; 1 per cent. solution = +.

History: Had steel intra-ocular foreign body May 2, 1922. The steel was removed by the anterior route, May 3d, with the giant and small magnets. Discharged, June 9th, with congested eye and poorly dilated pupil. The lens slowly became cataractous and the eye developed signs of intra-ocular inflammation, and gradually became more painful.

Local examination showed conjunctival and deep circumcorneal congestion. Good anterior chamber. Iris was muddy, discolored, and bound down to the lens by four large synechiæ. Tension normal.

July 25. Left eye, linear extraction with separation of the synechiæ. Considerable cortical matter remained.

Following operation the eye remained painful and congested, in which condition he was discharged to the out-patient department on August 5th, with good light projection. The patient reported regularly at the out-patient department until December 19th, when, owing to the fact that the left eye was still congested, light projection faulty, tension minus, and still very painful, Dr. Ryder advised enucleation. The patient returned to the clinic in February, 1923; the eye was congested and soft, and the light projection still faulty. An intradermal test with uveal pigment was negative and enucleation was postponed.

CASE 5.—Margaret C., 37856, female, white, aged sixty-seven years, admitted to the service of Dr. Thompson July 11th, with nearly mature cataract of the right eye and immature cataract of the left. V.R.E. = shadows, light projection good; V.L.E., with correction, 20/100. The lens protein test, +++.

Physical examination negative, except that the teeth are in bad condition.

July 12. Combined cataract extraction, right eye.

July 18. Pupil small, considerable cortical matter remains.

July 20. Right eye began to be painful. The pupil was not well dilated. Conjunctiva congested.

July 25. Patient sensitive to one per cent. atropin and hyoscin hydrobromid, one-third of one per cent., substituted. Eye very painful. Cortical matter absorbing slowly.

August 8. Eye quieting slowly, but still irritable and painful in spite of hyoscin, dionin, and hot fomentations.

September 1. Eye has quieted very slowly; now nearly white. The pupil is drawn up and there are posterior synechiæ of iris with remnants of cortical matter and capsule that partly occlude pupillary opening. Vision, with correction, = 20/100. Tension, normal.

Case 6.—Annie W., 37224, female, white, aged sixty years, admitted to the service of Dr. Lancaster June 7, 1922, with nearly mature cataract of the right eye. V.R.E. = fingers at one foot.

Physical examination negative.

Lens protein test = +++.

June 8. Combined cataract extraction, right eye. Very little cortical matter left.

June 15. Good anterior chamber. Pupil well dilated. Very little cortical matter present. There is a posterior synechia of the iris at four o'clock.

June 24. Patient discharged. Eye congested. Vision = fingers at one foot, not improved.

June 26. Out-patient department. Eye still congested with slight increase in tension.

August 30. Vision, with correction, = 20/200.

Case 7.—Mary N., 38500, female, white, aged sixty-five years, admitted to the service of Dr. Derby August 14, 1922, with sclerosed lens, right eye. Left pupil blocked from former prolapse of iris, after cataract operation. Lens protein test = +. The patient was a diabetic but is now sugar free, and blood sugar within normal range. Heart and lung negative.

August 22. Combined cataract extraction, right eye. Practically no cortical matter left.

August 26. Some striped keratitis.

September 2. Discharged with pupil well dilated. Some capsule in the pupillary opening. Moderate congestion. Vision, with correction, = fingers at six feet.

Case 8.—James S., 39203, male, white, aged sixty-eight years, admitted to the service of Dr. Derby September 18, 1922, with immature cataract of the right eye and nearly mature cataract of the left. Lens protein test = +. V.R.E., − 1.00 sph. = 20/100; L.E. = fingers at one foot. Light projection good.

Physical examination at the Massachusetts General Hospital showed arteriosclerosis, cardiosclerosis, and chronic nephritis.

September 19. Combined cataract extraction, left eye. Little cortical matter left.

September 21. Patient developed acute dementia and sustained a severe fall that resulted in a fracture of left humerus.

September 27. Transferred for surgical treatment to the Massachusetts General Hospital. No cortical matter in pupillary opening. Eye in good condition. Tension normal. Vision, with approximate corrections, = 20/200 +.

CASE 9.—Herbert M., 39683, male, admitted October 13, 1922, as a private patient (Dr. Verhoeff). Hypermature cataract, left eye. Physical examination, negative. Lens protein test = +. He was operated upon October 14, intracapsular extraction without iridectomy; no loss of vitreous; uneventful recovery.

October 30. Vision, with correction, = 20/15.

CASE 10.—Jeanette H., 39854, female, white, aged seventy-four years, admitted to the service of Dr. MacDonald October 25, 1922, with mature cataract of the left eye and incipient cataract of the right. Lens protein test = +.

Physical examination showed chronic cardiovascular disease (mitral stenosis, aortic insufficiency, and arteriosclerosis) and chronic right otitis media. On October 25th, a combined cataract extraction with peripheral iridectomy was performed on the left eye. Practically no cortical matter remained. She was discharged in ten days, after an uneventful recovery. Vision = 20/100. There was a small amount of lens capsule in the pupillary opening.

CASE 11.—Peter M., 39874, male, white, aged seventy-two years, admitted to the service of Dr. Verhoeff October 23, 1922, with mature cataract of the left eye. Physical examination negative. Lens protein test +. Was operated upon October 26th by the intracapsular method. The lens capsule ruptured as the lens was being delivered, but practically no cortical matter was left. He was discharged in ten days after an uneventful recovery, except a striped keratitis. Vision = 20/20. Eye white and quiet. Pupil well dilated.

CASE 12.—Sarah V., 39244, female, white, aged fifty years, admitted on September 21, 1922, to the service of Dr. Thompson, with a mature cataract of the left eye. Aphakia, right eye, following intracapsular extraction.

Physical examination negative. Lens protein test = +. Sep-

tember 22d, combined cataract extraction of the left eye without complications. No cortical matter left. Anterior chamber not irrigated. The patient was discharged in eleven days with the eye slightly congested. The nasal pillar of the iris was bound down to the corneal wound. V.R.E., with correction, = 20/20. L.E., with correction, = 20/30.

Case 13.—John O., 39455, male, white, aged seventy-seven years, admitted to the service of Dr. Derby, September 2, 1922, with nearly mature cataract of the right eye. Lens protein test = +.

September 3. Combined cataract extraction of the right eye with Van Lint injection of the orbicularis oculi. Considerable cortical matter was left, which appeared to be absorbing well, although the pupil did not dilate. The patient was discharged in ten days with the eye slightly congested and some cortical matter remaining. V.R.E., with correction, 20/200.

Patient was seen twelve days later in the out-patient department; eye was congested.

Fifty-seven days later the eye was still painful and congested.

Case 14.—Calvin R., 39459, male, white, aged eighty-two years, admitted to the service of Dr. Derby on October 2, 1922, with early hypermature cataract, right eye. Immature cataract of the left eye.

Examination negative, except for aneurysm of aorta. Lens protein, intradermal test = +. The right eye was operated upon October 3d by the combined method, leaving practically no cortical matter. He was discharged in eleven days with the eye white and quiet. Some capsule remained in the pupillary opening and at discharge the vision = 5/200, not improved.

In addition to the foregoing cases there were two other cases with positive tests to lens protein, which are not included above, since one (case 15) was, in a sense, selected, the diagnosis having been made by Dr. Verhoeff on the microscopic examination, and subsequently confirmed by the intradermal tests. In the other (case 16) the test was done after the above series was completed.

Case 15.—Arthur M., 38900, Italian, aged six years, admitted to the Massachusetts Charitable Eye and Ear Infirmary, on the service of Dr. MacDonald, on July 23, 1922. Past and family history

negative. One and one-half hours before admission, while reaching to a shelf for an open knife, it fell and struck him in the right eye, inflicting a perforating wound of the eyeball.

Examination on admission: Right eye, the lids and conjunctiva were normal. The cornea was clear, except for a perforating wound extending from the limbus at twelve o'clock to the limbus at six o'clock. There was no anterior chamber and a large portion of the iris, with lens matter and vitreous, protruded through the upper part of the wound. Under ether narcosis all the prolapsed iris, vitreous, and lens were excised, and the edges of the iris were replaced. The apposition of the wound was good, so no conjunctival flap was made. Instilled 1 per cent. solution of atropin sulphate and bichlorid ointment and applied a double bandage.

July 26. Lens much swollen, which caused the corneal wound to gape with a small prolapse of the iris at the top. The prolapsed iris was excised and the upper part of the cornea, where the wound was gaping, was covered with a conjunctival flap dissected from above.

July 29. The conjunctival flap was in position. The anterior chamber was not reformed. Pupil irregular. The eye was treated twice daily with boracic acid solution, one-half of one per cent. solution of atropin sulphate, and bichlorid of mercury ointment.

August 8. The eye was fairly white and quiet. The flap was in position over the upper part of the wound. The anterior chamber was reformed but shallow; the pupil was not well dilated.

August 14. Condition of the right eye about the same, but the pupil was not so well dilated. The left eye showed no signs of involvement.

September 2. Right eye same as above. Left eye, there was congestion of the conjunctiva, also deep circumcorneal congestion. The pupil reacted more sluggishly to light than before. No definite descemetitis. Enucleation of the right eye was refused by the parents, so patient was discharged against advice.

September 6. Readmitted to the wards. Condition of the right eye the same, except that it was painful. Under ether narcosis the eye was enucleated. Left eye showed definite signs of photophobia and tenderness to palpation. Ciliary congestion marked. Descemetitis lower portion of cornea. Pupil dilated. Several posterior synechiæ. Fundus not clearly seen. Atropin sulphate, a half per cent., t.i.d.

September 8. Left eye, there was a fair amount of conjunctival and ciliary congestion with more, but not marked, photophobia.

Eye was sensitive to pressure. Increased deposits on Descemet's membrane. Pupil fairly well dilated. Fundus obscure and disc hazy. Vision = fingers at three feet. Weight, 38½ pounds. Sodium salicylate, gr. x, t.i.d. Blood count, white blood-corpuscles, 8,000; polymorphonuclear, 44 per cent.; lymphocytes, 52 per cent.; large mononuclears, 4 per cent.

September 20. Intradermal test = +++.

September 28. Much better. Eye white and quiet. Vision, with correction, = 20/50.

September 30. Further improvement. Details of fundus made out for first time. Still many dust-like opacities in the vitreous.

October 8. White and quiet. Discharged to out-patient department, with atropin sulphate, one-quarter of one per cent., t.i.d. Sodium salicylate, gr. x, t.i.d.

February 4, 1923. Complement fixation with uveal pigment antigen, by Dr. Alan Woods,[4] was negative.

February 14. The intradermal test with one-tenth of one per cent. solution of uveal pigment was immediately positive, but negative after twenty-four and forty-eight hours. At this time the sympathetic uveitis was not very active.

Pathologic report of the right eye, No. 4602. Fixation in 10 per cent. formalin.

There is a healed perforating wound, extending entirely across the center of the cornea. The corneal epithelium is everywhere intact. The stroma is edematous, and the cornea is thickened, 4 mm. The corneal corpuscles are somewhat increased. There is a cellular infiltration at the periphery of the cornea, extending 3 mm. anterior to the canal of Schlemm, consisting of lymphocytes, eosinophiles, and a few polymorphonuclear leukocytes. A round-cell infiltration also occurs for 2 mm. on either side of the corneal wound, and here the thickness of the cornea is increased to 2 mm. Descemet's membrane, with its endothelial lining, is everywhere intact, except at the site of the wound. The posterior edges of the corneal wound are separated 1.5 mm., and the gap is filled with a mass of granulation tissue that extends backward through the lens and projects slightly into the vitreous. The central part of the mass is markedly infiltrated with pus cells and eosinophiles surrounding numerous globules of lens matter, and shows here and there areas of epithelioid cells and a few giant cells. The pupillary margins of the iris are adherent to the edges of the wound and the mass of tissue extending from it.

The base of the iris is adherent to the ligamentum pectinatum by organizing tissue. The whole iris is markedly congested and infiltrated throughout with mononuclears, pus cells, and eosinophiles, and shows here and there denser nodules consisting chiefly of mononuclears.

The anterior chamber on either side of the mass described above is filled with serum containing many eosinophiles, a few pus cells, and mononuclears. These cells are most numerous on the surface of the iris, from the stroma of which they are apparently derived.

There is a cyclitic membrane that completely surrounds the lens and is continuous with the mass of granulation tissue passing through the center of the lens. Anteriorly, the iris is firmly united to this membrane. On each side of the mass of granulation tissue a considerable amount of lens matter remains inclosed in the lens capsule. This is largely liquefied, but contains, here and there, areas of hyaline globules, which are markedly surrounded with polymorphonuclear leukocytes, among which are many eosinophiles.

There is a rim of normal lens substance about the periphery. From the mass of granulation tissue in the center of the lens numerous fibroblasts and endothelial cells are extending into the lens matter.

The ciliary body is markedly congested and swollen and its surface is covered, as far back as the ora serrata, with a dense cyclitic membrane. From the surface of the membrane there is a marked exudation of endothelial cells into the vitreous.

The posterior part of the ciliary body and the anterior part of the choroid show a marked perivascular infiltration with small round cells. The choroid is congested throughout, and in the fundus shows a moderate number of small foci of perivascular infiltration. These foci consist of lymphocytes and epithelioid cells, such as are seen in sympathogenic uveitis. The retina is *in situ*, except for a microscopic separation at the disc margin. The retina is infiltrated with endothelial cells, some of which form large nodules on its surface. A few of these nodules are found free in the vitreous. The ganglion cells are well preserved in the area of the macula, but much reduced in the periphery. The nerve-fiber layer, especially toward the periphery, shows extensive gliosis. In the anterior part of the retina there is a marked perivascular lymphocytic infiltration.

The optic disc is markedly swollen (2 mm.) and congested

throughout and shows a slight round-cell infiltration. The surface shows some glial proliferation.

Sections stained by the Verhoeff modified Gram stain show no intra-ocular micro-organisms.

Case 16.—John L., 41471, male, Italian, aged twenty-nine years, admitted to the service of Dr. MacDonald on February 5, 1923, with posterior cortical cataract of each eye. V.R.E., shadows, light projection good; L.E., with correction, 20/70 −1.

History: The patient was first seen in the out-patient department on October 21, 1922. At that time he complained that his vision was too poor to enable him to do his special work in a rubber factory. The Massachusetts General Hospital report showed the physical examination to be negative. Blood Wassermann negative. There was one root abscess that was treated.

November 19. The test with lens protein was positive + in twenty minutes and ++ in twenty-four hours. Beginning on November 25, 1922, a full desensitizing course of intramuscular injections of lens protein was commenced and completed February 5, 1923, at which time the graduated tests were negative in all dilutions.

February 6. Discission of the right eye.

February 8. Discharged to out-patient department. Little reaction; pupil well dilated; eye white and quiet; tension, normal. To return half weekly for observation.

February 8 to March 15. The patient received weekly injections of 1 c.c. of 10 per cent. solution of lens protein. The lens became quite opaque. There was considerable cortical matter in the anterior chamber, and the pupil remained well dilated with one per cent. atropin t.i.d. Following the weekly injections the eye was painful and slightly congested for twenty-four hours, but at no time was there severe discomfort.

March 16. Right eye, linear extraction with peripheral iridectomy, using Van Lint and subconjunctival injections. The iris was somewhat traumatized with the capsule forceps. The anterior chamber was irrigated but considerable cortical matter was left on the temporal side. Atropin was instilled and a double bandage applied.

March 18. Moderate reaction, pupil fairly well dilated, considerable cortical matter remains.

March 24. Vision, with correction, 20/30 + 2.

March 25. Discission, left eye.

March 27. Lens rapidly becoming cataractous. Tension, normal. Moderate reaction.

March 31. Linear cataract extraction as for the right eye. During the operation vitreous appeared and a very small amount was lost, atropin instilled, double dressing. A large amount of lens matter was left in the eye.

April 5. Moderate reaction; pupil fairly well dilated. Discharged to out-patient department and advised to return for regular weekly lens protein injection. Tension, normal. No pain or discomfort. Instilled one per cent. atropin, t.i.d., each eye.

May 15. The left eye has shown practically no reaction in spite of the large amount of lens matter present. This has absorbed very slowly and still occludes three-fourths of the pupil. Vision with correction = 20/30 + in each eye.

May 30. Vision 20/20 in each eye.

CONCLUSIONS

In a series of 168 unselected cases tested for lens protein hypersensitiveness, 14 gave positive reactions of varying degree. Seven patients—cases 1, 2, 3, 4, 5, 6, and 13—in whom there remained a fair amount of free cortical matter developed intra-ocular inflammation. This inflammation varied with the amount of cortical matter left, and, also, according to the degree of hypersensitiveness of the patient as demonstrated by the skin test. None of the cases giving a negative test to lens protein developed an intra-ocular inflammation, except those with active infections.

The microscopic findings in the eye affected with phacoanaphylactic endophthalmitis, which was enucleated, were identical with those reported by Verhoeff and Lemoine, except that there was in addition an early sympathogenic uveitis. This complication was merely coincident, as six other patients who had recently had a sympathetic uveitis gave negative tests to lens protein.

Two patients markedly hypersensitive to lens protein were successfully desensitized, as demonstrated by negative intra-

dermal tests, and successfully operated upon for immature cataract, by the ordinary method.

In one case, when the patient was already affected with phacoanaphylactic endophthalmitis, attempts at desensitization, by our present technic, were unsuccessful in ameliorating the condition. This case illustrates the danger of attempting an intracapsular operation on a patient who is under fifty years of age. Therefore, patients with immature cataracts who are under fifty years of age and hypersensitive to lens protein, should be desensitized or, failing in this, the operation should be postponed until the cataract is mature.

After the desensitization of hypersensitive patients under fifty years of age, the operation of discission followed by subsequent linear extraction apparently gives the best results.

The skin test for lens protein hypersensitiveness is apparently necessary only in the following types of patients: 1. Those with immature cataracts. 2. Those with traumatic cataracts. If the test is positive, every effort should be made to remove the lens matter by operation as early as possible. 3. Those failing to develop good vision following a previous operation on the other eye, and particularly those who give a history of long-continued pain and redness following a previous operation for cataract extraction.

We wish to avail ourselves of this opportunity to thank the following surgeons of the Massachusetts Charitable Eye and Ear Infirmary for permitting us to carry on this work on their services, and allowing us to publish our results: Drs. Verhoeff, Derby, Thompson, Lancaster, and Ryder. Also Dr. Alan C. Woods, of Baltimore, for uveal pigment for tests and for the serum examination made in case 15.

We are especially indebted to Dr. Verhoeff for the many suggestions and corrections, and for the microphotographs and the pathologic specimens.

REFERENCES

1. Verhoeff and Lemoine: Endophthalmitis Phacoanaphylactica. Transactions, An International Congress of Ophthalmology, Washington, 1922.
2. Verhoeff and Lemoine: Hypersensitiveness to Lens Protein—Patient Desensitized and Successfully Operated on for Immature Cataract, Amer. Jour. Ophth., vol. v, No. 9, 1922.
3. Walker, I. C.: Personal communication regarding desensitizing of patients in his routine protein therapy work. Also, Study XIV: The Treatment of Patients with Bronchial Asthma with Subcutaneous Injections of Protein to which they are Sensitive, Jour. Med. Research, 1917, vol. xxxvii, p. 51.
4. Woods, Alan C.: Personal communication.

DISCUSSION

DR. W. B. LANCASTER, Boston, Mass.: I want to commend to the members of the Society the use of this test. It is simple to perform. We do it regularly on all the cases at the Infirmary and it is a useful guide. Bear in mind, however, that a vast majority of cases are not sensitive—less than one in ten. So if you find a few cases negative do not be surprised.

It is particularly useful in traumatic cases. If you have some cortical matter left in the anterior chamber of an eye that is injured, you can ordinarily treat the eye with expectant methods; but if you find the patient is sensitive to lens protein, you should immediately evacuate as much as possible of the lens matter before serious inflammation is started.

DR. GEORGE S. DERBY, Boston, Mass.: The lens protein test has been used in all the cataract cases on my service at the Massachusetts Eye and Ear Infirmary during the last eighteen months, and also on most of my private cases. I am glad to testify to the extremely careful and conscientious work of Drs. Lemoine and MacDonald. I think they deserve a great deal of credit for pursuing an investigation of this sort during a busy and exacting service.

As to the value of the test, I do not as yet feel able to form any definite personal opinion. One or two cases have been suggestive. If the results of Verhoeff and the writers are confirmed, it is hardly necessary to point out the great value of the test.

DR. ARNOLD KNAPP, New York: May I ask Dr. Lemoine to tell us if this anaphylactic inflammation has definite clinical signs? Also where the material for the test may be obtained?

DR. W. H. WILDER, Chicago: I think we should be very careful before we come to any positive conclusions on a subject as

complex as this. From experiments of Hektoen and others it has been shown that the lens is not species specific at all, and, furthermore, it seems to be true that certain tissues of the eye that have already been sensitized to certain proteins or globulins or some other complex chemical substances, may react to whatever kind of protein may be injected into the circulation. It seems to me, therefore, before we can determine conclusively that a given eye is reacting because of some lens protein left in the anterior chamber, we must know in each individual case what the conditions are in the tissues of that eye, particularly the uveal tissues. It has been an observation of clinicians for many years that we frequently, but not always, get pronounced reaction when cortical substance is left in the chamber after cataract extraction. We should welcome, therefore, any safe procedure by which we could regulate this. But we cannot be positive, unless it is possible to make controls, that it is the lens protein that is affecting the eye. It may be that in a given eye there is a condition which renders it sensitive to lens protein, but it may be sensitive also to other proteins, such as peptone or even bacterial proteins, that may gain entrance to the circulation. So I say, let us not be too hasty in forming our conclusions, but in all cases have something in the nature of a control.

One other thought in regard to results after cataract operations: There is a great disposition on the part of individuals who report series of cataract cases to judge of the value of any operative procedure by the end results in terms of vision, and that is an error into which the protagonists of the intracapsular operation frequently fall. It would be much more accurate and enlightening in describing the end results to give information as to the severity and duration of the reaction, the clearness and shape of the pupil, the amount of astigmatism, etc., rather than the degree of vision alone.

A case that shows 20/200 vision might have been more of a success in an operative way than one that showed 20/50, or even 20/20. We all know that the degree of vision will depend as much upon the transparency of the vitreous and the condition of the choroid and retina around the posterior pole as it will on the clearness of the pupil. What we want to know is whether a certain method of treatment or operation gave the eye a better chance than some other method, and we should not attempt to justify any procedure merely by end results obtained in terms of vision.

Dr. W. H. Wilmer, Washington, D. C.: It would seem that

there are definite lessons to be learned from this very valuable paper. All of us who have had a moderately large operative experience, over a number of years, have considered cortex left in the eye as a foreign body. We have felt (for years before these scientific advances were made) that it behooved us to get rid of this danger. For this reason we have believed that in certain types of cases the intracapsular operation is the ideal procedure—either the operation as performed by Dr. Knapp or some other similar operation. If no such operative procedure is followed, it behooves us to remove the cortex either by a spoon, by expression, or by some other means. I personally believe that the anterior syringe is a valuable instrument. One can syringe the anterior chamber thoroughly, after the capsule is incised, until all cortex is removed, and we should not be satisfied until this removal is complete.

I believe further that the anterior syringe has another value. It pushes back the little tags of capsule, forces the iris away from the cornea, and prevents adhesion of the cut iris to the corneal wound. With proper precautions it is not dangerous and should not lead to infection. I happened to look over my own operative cases for a number of years, and I find that since 1915 I have had no infection of the wound in any operative procedure in spite of having used the anterior syringe frequently, so one can safely say that it is not dangerous to use the syringe provided the proper antiseptic precautions are taken. Its use does not increase the traumatism and it does enable one to expel the cortex from the anterior chamber, so that I am certain that the anterior syringe still has its place in ophthalmic surgery today.

DR. ALBERT LEMOINE (closing): In reply to Dr. Knapp's questions, the signs of intra-ocular inflammation are similar to those of iridocyclitis, a contracted pupil, congested iris, and the cortical matter assumes a milky, granular appearance. It is whiter and more granular than ordinary cortical matter. Very frequently there is descemetitis associated with it, which may be very severe. There is also pain, and the lacrimation is usually very marked in comparison to the inflammation present. Case 2 was of this character; the descemetitis covered the whole cornea and it persisted for several weeks.

Lens protein is not on the market. The only place it can be obtained is at the Eye and Ear Infirmary. Miss Taylor, in Dr. Verhoeff's laboratory, is preparing some for the doctors who ask for

it. I also have been preparing what I need for my personal use and have supplied some of the oculists with small quantities.

As to Dr. Wilder's remarks, we had 144 control cases. All of these cases had cortical matter left in the eye. All gave negative tests to lens protein, and none had intra-ocular inflammation excepting where there was an active infection.

MONOCULAR DIPLOPIA, WITH ESPECIAL REFERENCE TO THAT ASSOCIATED WITH CEREBRAL LESIONS

WILLIAM ZENTMAYER, M.D.
Philadelphia, Pa.

The conditions in which monocular diplopia is met have been stated by de Schweinitz to be—(1) anomalies of refraction, particularly astigmatism; (2) opacities in the cornea and lens; (3) irregular cramp of ciliary muscle; (4) hysteria or allied functional nervous disturbances—for example, neurasthenia and cerebral asthenia; (5) organic disease of the brain or its membranes; (6) simulation. To these should be added (7) dislocated lens and (8) detachment of the retina.

In an excellent article on "Monocular Diplopia; Its Relation to Hysteria," Charles makes a somewhat different classification: (1) That form which proceeds from physical causes. (2) That resulting from the activity of a pseudo-fovea simultaneous with that of the anatomic fovea. (3) A form associated with cerebral lesions. (4) A form not accounted for by any other hypothesis than that there is a cortical dissociation, which is the basis upon which hysteria is explained by the majority of modern neurologists.

Cases falling under several of these heads are well known and of no particular interest. There are, however, cases of exceptional causation, little known, which are deserving of a brief mention.

Bull, G. J., points out that under certain circumstances a temporary monocular diplopia is produced by the partial or complete closure of the lids in the action which may be termed "constriction." He endeavors to show that it is immediately connected with the effect of constriction of the lids upon the anterior surface of the cornea. Allied to this class are the cases due to prolonged use of one eye at near work, such as microscopy, the monocular diplopia occurring in the unused eye.

Snellen describes a personal observation in monocular diplopia. When looking at the 6 m. line of test letters at 6 m., a second less distinct row was seen in upright position, but distinct enough to equal a visual acuity of 6/6. To see it plainly required 0.5 D. accommodation more than that required for the true image. He explained this by supposing that it arose from rays which were reflected from the anterior surface of the lens toward the anterior surface of the cornea, and from here were reflected back as from a concave mirror into the interior of the eye.

Rochat in explaining a similar case attributes it to decentration of the refracting surface and to spheric aberration.

To touch for a moment upon hysteric monocular diplopia, Wolfflin says that in many of these cases the primary cause is other than the hysteric element, often a trauma. Even when hysteria appears to be the cause, the real factor is faulty accommodation. He thinks the hysteria is only a predisposing cause arising from the increased sensitivity for mental impressions. Too often conditions are attributed to hysteria that have a physical basis. The diagnosis of hysteric monocular diplopia rests upon the effect of suggestive therapy.

Charles takes exception to the tendency to dismiss all cases of hysteric monocular diplopia with the explanation that it is accommodation. He holds that while it is true that physical causes (from cornea, iris, or lens) are the usual causes, in the light of modern knowledge of hysteria, it is unscientific to

denominate these symptoms "hysteric conditions" when they are not directly referable to a cerebral disturbance. The mere fact of association of monocular diplopia due to spasm of accommodation does not make it hysteric whenever it happens to occur in hysteria. He believes, as has already been said, that monocular diplopia in hysteria is due to a cortical dissociation which is the basis upon which hysteria is explained by modern neurologists.

Of especial interest are cases of monocular diplopia where, in the words of Moore, "there was no local cause in the eyes to explain it, and in which, after careful critical consideration, malingering and hysteria could be ruled out as the cause." The following case belongs to this class:

Miss B., aged sixty-one years, school teacher, has been under my care for twenty-eight years for anisometropia and for a low esophoria. For the latter condition a careful tenotomy of the internal rectus was performed in 1898. Since then she has been seen at irregular intervals averaging once a year. In 1911 there was noticed for the first time a small, dot-like opacity at the posterior pole of each lens, denser in the right. These have undergone very little change. In February, 1913, she had a spontaneous subconjunctival hemorrhage, at which time the retinal vessels began to show some thickening of the walls. In 1915 there was a recurrence of the subconjunctival hemorrhage and she was seen by the late Dr. Fussell, who reported a high blood pressure. In 1918, she complained of a spot before the left eye without impairment of vision. No vitreous opacity was discovered.

There is nothing further of interest until March 24, 1923, when she returned, stating that ten days previously she developed diplopia, which was present in binocular vision and also when the right eye was closed. An examination showed a paralysis of the left external rectus muscle with characteristic homonymous diplopia. When the right eye was closed there were still two images occupying the same relative position as the double images in the binocular vision. Her vision was 5/7.5 right eye and left eye 5/6 pt., about the same as it has been for the past five years. The ophthalmoscope showed the upper inner border of the left nerve head veiled, veins enlarged but not tortuous. She was sent to Dr. George W. Norris who re-

ported the blood pressure to be 158 and 85, and the liver greatly enlarged.

The patient had great difficulty in convincing me that she had monocular diplopia, especially as it was coincident with the development of the paralysis.

A pertinent caution sounded by Tilley concerning a similar experience is worth quoting: "In our endeavors to avoid being deceived, especially relative to a statement to which we cannot assign a well-formed theory, we are also in danger of deceiving ourselves."

While the literature contains quite a number of cases of monocular diplopia belonging to categories 4 (hysteria, neurasthenia and cerebral asthenia), 5 (organic disease of the brain or its membranes), and 6 (simulation) of de Schweinitz's classification, a rather cursory review shows only 9 or 10 similar to my own, of paralysis of an ocular nerve of probably cerebral origin, associated with monocular diplopia. All of the cases, except that of de Schweinitz, were abducens palsies, and in several there was a dilatation of the pupil on the affected side.

In Ord's case, a boy of thirteen years, both sixth nerves were affected. There was a binocular diplopia followed in a few days by monocular diplopia with either eye, later limited to the left eye. Postmortem examination revealed a large cavity occupying the usual position of the lateral ventricle, with which a small aneurysm was communicating in the right cerebral hemisphere.

Abercrombie's case was a girl, eleven years old. Paralysis of the right external rectus, binocular diplopia, and diplopia when the left eye was covered were present. Autopsy showed an abscess in the right temporo-sphenoidal and occipital lobes, completely or nearly destroying Gratiolet's fibers.

Gunn and Anderson's patient was a man, thirty-four years of age, with many evidences of gross cerebral disease.

The left sixth nerve was paralyzed. The pupil was enlarged. Both binocular and left monocular diplopia were present.

de Schweinitz's case was unusual in that both in binocular and monocular vision the diplopia was vertical. The patient was a middle-aged man who had received a head injury followed by unconsciousness. The condition was still present years later. de Schweinitz considers the possibility of either organic brain trouble or hysteria in this case.

Nettleship saw a pure case with cerebral symptoms in a young man. The right external rectus was paralyzed and there was diplopia. The monocular diplopia, of the right eye, was present chiefly, if not only, when great effort was made by the paralyzed muscle.

Juler's case was a woman, forty years of age. There was slight paralysis of the left external rectus muscle with homonymous diplopia, but also diplopia with the left eye alone.

Bonvaret and Chapato's patient had left incomplete hemiplegia, right partial ptosis, paralysis of the left third and sixth nerves, and diplopia of the left eye. There was beginning bilateral optic neuritis. Autopsy showed a tuberculous tumor of the peduncles.

Brailey's case had the same syndrome, but there were other conditions that may take the case out of this class, namely, a myopia of 7 D. and opacities in the posterior lens capsule.

Gunn and Anderson emphasize three points in the four cases of monocular diplopia reported before the Ophthalmic Society of the United Kingdom, to which reference has already been made: (1) The occurrence, as a concomitant, of abducens paralysis, accompanied in the two cases where the pupil condition is noted, by dilated pupil. (2) The disappearance of the monocular diplopia in two of the three cases pari passu with the disappearance of the abducens paralysis, which tempts to the generalization that either abducens

paralysis and monocular diplopia are cause and effect, or that both phenomena are due to a common central cause. (3) The presence of coarse cerebral disease in the two cases where there has been a postmortem examination, and the occurrence in the other two of nervous symptoms, consistent with, although not decisive of, coarse cerebral lesion, the lesion in the two cases recorded being of such a nature and extent as to be unavailable for localization, while one furnishes no assistance on this head.

In three of the cases cited in this paper the existence of a gross cerebral lesion was demonstrated anatomically, and in two there were clinical evidences of gross cerebral disease. The accompanying dilated pupil probably has no bearing on the monocular diplopia, as Nettleship has observed this symptom in a large number of sixth nerve palsies.

Fontan suggests that impressions received by each eye are transmitted respectively to the right and left hemispheres, and in normal conditions these impressions are fused by communicating fibers. When these communicating nerve-fibers, however, are disturbed, double monocular vision occurs.

Abercrombie says if each optic nerve is connected with the cortex of both hemispheres of the brain, then it is conceivable that in cases such as these the right hemisphere did not act in perfect unison with the left in interpreting the impressions received upon the right retina, hence the double vision; but upon this hypothesis there ought to have been double vision with the left eye also, which was not present.

Nettleship has reason to suspect that in his case the patient's monocular statements were in some way based on his experience of binocular sixth nerve diplopia.

Moore believes this the correct explanation of the phenomenon.

In view of the fact that hysteria often exists in the presence of gross cerebral lesions and our knowledge that monocular diplopia is known to occur in hysteria, it is possible that in

some cases this may be the explanation of this unusual symptom.

The observation of Nettleship that the monocular diplopia was noted only when the paralyzed muscle attempted to function, might be explained by assuming that in the effort of the paralyzed muscle to rotate the globe, there was a second recognition of the object by another point on the retina while the first image still persisted.*

DISCUSSION

DR. J. W. CHARLES, St. Louis, Mo.: Dr. Zentmayer's paper has more than ever convinced me that all things are possible to the hysterical cortex, or dissociation of consciousness; whether manifested by inhibition, as in amblyopia; by crossed wire effects, as in transference of sensory stimuli to motor nerves or vice versa; or in exaggeration or diminution of effect, as in megalopsia or micropsia, the interpretation by the brain of an image caused by stimulation of let us say 1,000 cones to that of 5,000, or the reverse.

The images doubled by physical causes can be redoubled by prisms. It must not be forgotten that actual cerebral lesions can cause dissociations.

DR. W. B. LANCASTER, Boston, Mass.: I should like to ask the reader of the paper to illustrate on the blackboard the position of the double images, whether they were the same distance apart in all parts of the field.

DR. WILLIAM ZENTMAYER (closing): The images as seen monocularly were like those in ordinary cases of paralysis of the external muscle. That is, the most distinct image was on the opposite side and the false image was on the same side as the eye affected. The separation of the two images belonging to the one eye was not great and did not increase with rotation of the eye in the direction of the paralyzed muscle.

* I am indebted to Dr. Jonas Friedenwald for assistance in looking up the literature.

METASTATIC CHOROIDITIS FROM FOCAL INFECTION

ALLEN GREENWOOD, M.D.
Boston, Mass.

We are all more or less familiar with the severe type of metastatic suppurative choroiditis which sometimes complicates a virulent septicemia or general pyemia. Those of us who saw service in France are able to recall cases of metastatic suppurative choroiditis of this type coming on rapidly and resulting in panophthalmitis and destruction of the eye in soldiers who had septic compound fracture wounds of the thigh. We are less familiar, however, with the type of metastatic choroiditis which occasionally complicates a mild type of focal infection, such as occurs at the roots of teeth. This type of choroiditis is sometimes described as acute exudative choroiditis. It is a true suppurative choroiditis, but remains largely confined to the choroid and retina. Sometimes it is confined to a small area and again is more diffuse. It does not progress to the point of causing abscess of the vitreous or complete endophthalmitis. The infrequency with which one sees such cases makes it seem advisable that the two following should be put on record:

Case 1.—Mr. T. M., aged forty-nine years, first seen May 9, 1921.

Past History: Other than a moderate amount of myopia, for which he has worn glasses, the eyes have always been normal.

Present History: About two weeks ago he had several teeth removed which had apical abscesses. Shortly after this operative work on the jaw he noticed a beginning blurred vision of the right eye which increased until he came to the office.

Examination: Right eye: lids normal, no disturbance with the

lacrimal apparatus, conjunctiva normal, cornea clear, iris normal, pupil normal with normal reaction to light and accommodation, lens and vitreous clear. The upper central quadrant of the retina and choroid was swollen and edematous, the swollen area having a white appearance with a slightly yellowish tinge. This V-shaped area of acute exudative choroiditis was most clearly marked up and in and shaded off into the surrounding retina so that there was no clear line of demarcation. It extended upward about three disc diameters from the edge of the disc and spread out fan-wise until its greatest breadth was also about three disc diameters in width. The field of vision showed a partial scotoma downward, corresponding to the fan-shaped area of choroidal inflammation. Vision was 20/70—.

Diagnosis: Acute exudative choroiditis metastatic from apical abscesses.

The affected teeth having been removed, there was no necessity for further treatment directed to the cause of the ocular condition and a favorable prognosis for recovery was given.

Aspirin was ordered to be taken, ten grains three times a day, and saturated solution of iodid of potash, ten drops three times a day, the dose to be increased two drops daily. The iris and pupil having been found normal no atropin was ordered.

May 13, 1921. The vitreous presented slight nebulous clouds and it was thought best to add to the previous medication a solution of 1 per cent. atropin, to be used three times a day, believing that the anterior portion of the uveal tract would be involved.

May 22, 1921. It was found that the vitreous had become so cloudy that it was difficult to see the area of choroiditis. Deposits had formed on Descemet's membrane, with the usual triangular figure. Vision had dropped to 20/200. The iris itself appeared quite normal and the pupil was fully dilated. There was no sign of any circumcorneal injection. The aspirin was omitted and the atropin and iodid of potash continued.

May 24, 1921. The vitreous showed a little less cloudiness and the vision had risen to 20/100. The patient was told to continue with the treatment and report in two weeks, it being felt that the process was subsiding and there had been no development of iridocyclitis. He was, however, to report at any time that there were any unfavorable symptoms.

June 13, 1921. Vitreous much clearer and the same fan-shaped localized exudate in the choroid could be seen dimly. There was

still considerable descemetitis, but the iris appeared normal and there were no anterior synechiæ.

June 29, 1921. Only a few spots of descemetitis remained and the vision had risen to 20/50. The vitreous was still quite cloudy.

August 5, 1921. All signs of descemetitis had disappeared, but the vitreous was still cloudy. Atropin was omitted.

September 22, 1921. Vision still 20/50. Vitreous was cloudy and it was difficult to make out the outlines of the choroidal disturbance. Pupil normal size and responded actively to light and accommodation. Iris healthy.

December 28, 1921. Vision remained 20/50. The vitreous was much clearer, however, and a large area of atrophied choroid could be distinctly seen above the disc, extending over the area previously outlined. There was much pigment deposited around the edges of this area and some pigment scattered throughout. The retinal vessels could be seen crossing the white exposed sclera. The visual field had the very definite scotoma, as shown on the chart.

A carefully done refraction at this time gave the following results: R.E., -5.75 sph. $\bigcirc$ $-$ .75 cyl. ax. 65° = 20/40; L.E., -5.75 sph. $\bigcirc$ $-.75$ cyl. ax. 5° = 20/15.

March 14, 1923. Conditions were found to be as reported for December 28, 1921. Vitreous showed only a few faint clouds and the defect in the retina and choroid could be easily mapped out. Vision remained the same and the scotoma unaltered.

In this case while some descemetitis developed there was at no time any other evidence of involvement of the anterior portion of the uveal tract, the whole force of the infection being spent on the area of choroid above the disc.

Case 2.—Mrs. B. A. H., aged thirty-three years, a rather robust young woman of medium height; first seen July 12, 1921.

Past History: Ten years previously the right eye, which had been a blind and useless organ since childhood, was removed. There had never been any trouble with the left eye until November 18, 1919, when she had a slight catarrhal conjunctivitis which responded very quickly to sulphate of zinc solution.

Present History: Came to the office for treatment for what she considered was a return of the acute catarrhal conjunctivitis, there being a feeling of sand in the eye and some inflammation.

Examination: Slight follicular conjunctivitis, particularly on the

conjunctival surface of the lower lid, the conjunctival surface of the upper lid being slightly affected. The same solution of sulphate of zinc was ordered.

The following day, July 13, 1921, the patient stated that the left eye had become more inflamed and more uncomfortable. Examination at this time showed the conjunctiva of the lids more normal but the ocular conjunctiva seemed more injected, but no deep circumcorneal injection was present. The pupil was normal in size and reacted normally to light and accommodation. There was a suspicion, however, of the iris being disturbed, and, therefore, atropin was ordered for diagnostic purposes. Because of the discomfort, five grains of aspirin were ordered to be taken three times a day. At this time the patient was sent to an odontologist to have *x*-rays of the teeth made, it being feared that there might be an apical abscess as the cause of a possible impending iritis.

July 14, 1921. Odontologist reported teeth negative, except one devitalized lateral incisor which was not sufficiently covered by the *x*-ray to show a picture of the tip of the tooth.

July 15, 1921. The patient stated that the eye was quite comfortable but that she had found the vision disturbed on arising that morning. Examination showed the iris healthy in appearance and the pupil dilated. The conjunctiva around the cornea showed a moderate chemosis without there being any deep circumcorneal injection. Ophthalmoscopic examination showed the vitreous slightly cloudy and a large yellowish massive exudate in the choroid extending from the nasal side of the disc and outward as far as the fundus could be observed occupying practically the whole nasal quadrant. Corresponding to this defect in the fundus there was a relative scotoma in the left temporal quadrant of the field. The exact outlines of the massive exudate in the choroid were difficult to make out, owing to the clouding of the vitreous. The patient could see to get around, the central vision being about 20/70. The patient was seen in consultation by Dr. Verhoeff, who confirmed the diagnosis of metastatic choroiditis. She was at once sent to the Massachusetts Charitable Eye and Ear Infirmary to occupy a private room where she could be under the care of Dr. Verhoeff and myself. When admitted the temperature was 99.6° F., pulse 80, respiration 20. The one per cent. solution of atropin was continued and ordered to be used four times a day and ten grains of aspirin ordered four times a day.

July 16, 1921. Seen with Dr. Verhoeff consulting. Examination

showed no iritis, pupil well dilated, vitreous moderately cloudy, and the massive exudate in the choroid had spread upward and downward so the whole nasal half of the fundus was involved. The chemosis was markedly increased, and it was feared that the case would prove to be one of virulent suppurative metastatic choroiditis resulting in panophthalmitis. Vision was reduced to counting fingers at one foot. Another x-ray of the teeth was ordered.

July 17, 1921. The report came back that the left upper incisor had a large apical abscess. The tooth was immediately extracted and the contents of the abscess examined and found to contain streptococci. Chemosis was much increased and the upper lid swollen. The lower part of the chemotic conjunctiva protruded slightly from the lids when the eye was closed. In spite of this severe conjunctival chemosis the iris was still clear, the vitreous only moderately cloudy, and the patient still retained some vision. Laboratory tests failed to suggest any bodily conditions likely to prove contributing causes.

July 18, 1921. The patient could still see to count fingers at one foot, but it was evident that the condition was spreading and, on the advice of Dr. Verhoeff, 5,000 units of diphtheria antitoxin were given subcutaneously. Rhinologists made exhaustive examinations but found nothing abnormal by direct examinations and roentgenographs.

July 19, 1921. There being no improvement, in spite of the withdrawal of the tooth, an additional 5,000 units of antitoxin were given and the patient was given a pilocarpin sweat and mercurial inunction, with the order that the mercurial inunctions be continued every day and the pilocarpin sweat every third day.

July 20 and 21, 1921. The patient was given on each day 5,000 more units of antitoxin. There was still no involvement of the iris, but the chemosis was somewhat increased and there was a slight proptosis.

July 22, 1921. Conditions seemed to be slightly improved, there being less chemosis and the fundus could be more easily seen.

July 23, 1921. Chemosis had markedly increased, and the yellowish exudate in the choroid had increased so that it nearly surrounded the disc and was extending into the temporal portion of the fundus both above and below. Five thousand more units of diphtheria antitoxin were given and the other treatment continued as before.

July 24, 1921. Conditions were much the same.

July 25, 1921. There was a marked improvement accompanied by a drop in temperature. The chemosis was much less, but the whole fundus gave a yellowish reflex, showing that the entire choroid had become involved, and the vision was reduced to the bare perception of moving lights.

From this time on there was a steady improvement in the inflammatory manifestations, but no improvement in the vision, the chemosis rapidly subsiding. The vitreous remained cloudy and there was seen throughout the fundus a yellowish-white reflex.

The patient was seen almost every day by Dr. Verhoeff, as well as myself, and by other members of the Infirmary Staff, including Dr. Walter B. Lancaster. Some of the observers volunteered the statement that they had never seen a case having all the appearances of a beginning virulent suppurative choroiditis with intense chemosis and apparently likely to go on to a panophthalmitis which remained rather sharply localized as a suppurative process involving the choroid without extending.

The patient continued to improve from July 25th to August 4th, as can be seen by the temperature chart, when she was discharged from the hospital. After returning to her home she was seen every few days and on September 16, 1921, the following was noted: Eye perfectly white and quiet. No signs of any involvement of the iris or ciliary body, but the vitreous was too cloudy to allow a view of the fundus. The reflex of the latter was the same yellowish color as reported before.

From this time for two months the patient was given occasional pilocarpin sweats and periods of inunctions of mercury, with gradually increasing doses of iodid of potash. Dionin was used occasionally, but only produced a slight reaction which did not seem to be of any benefit. During all this time the pupil had been kept dilated with atropin, used once a day.

November 10, 1921. The condition remained the same, but a few drops were observed on Descemet's membrane in the lower quadrant of the cornea and the lens showed slight beginning cloudiness. The eye was soft.

January 5, 1922. The lens had become entirely opaque and the eye was soft and assuming a quadrilateral shape. A very slight descemetitis still remained. The patient from then on continued with the daily use of a mydriatic in the form of hyoscin combined with one per cent. holocain.

Patient last seen May 15, 1923. Eye still soft, with a quadrilateral shape and a perfectly white lens. Vision = blind.

In this case a yellowish massive exudate came in the choroid prior to any definite signs of anterior uveal involvement. This was accompanied by a rapidly increasing severe chemosis with edema of the upper lid or early signs of beginning panophthalmitis. The infection, however, was not virulent enough to produce this latter condition, so that the case went on as one of progressive non-virulent metastatic choroiditis involving the whole choroid and later resulting in descemetitis and opacification of the lens, with softening and shrinking of the globe; at no time was there any evident iridocyclitis. The iris was still in a healthy condition when the patient was last seen. Being a very unusual case it seems well worth reporting with the hope that a helpful discussion may result.

DISCUSSION

DR. CARL FISHER, Los Angeles, Cal.: I would like to ask Dr. Greenwood to give us a little more data regarding the etiology of these cases. I gathered from the abstract that they were considered due to apical abscesses of the teeth.

I have more than once found myself, as well as my colleagues, misled by the mere finding of a plausible source of chronic focal infection. Some cases in which the relationship between the disease and focal infection seemed diagrammatic, as shown by a coincidental improvement, have turned out to be syphilitic or tuberculous, for example.

DR. E. C. ELLETT, Memphis, Tenn.: In the following cases the relation of dental infection to uveitis seems well established:

J. C., aged thirty-nine years, seen August 6, 1917, with the history that five days previously he had a gold crown put on an upper front tooth, and that afternoon he noticed a black spot or web before the left eye. Vision was 20/30 and J. 3, improved to 20/20 by +1.00 cyl. ax. 90°. There was a small pterygium on the eye. Intraocularly, there could be noted numerous vitreous opacities and fine deposits on the posterior surface of the cornea. The fundus details

were obscured, but there were no areas of choroidal exudate seen, and the eye was not inflamed. The crown was removed and several abscessed teeth were extracted; iodids were given internally. Recovery was slow and incomplete. Vitreous opacities were noted three months later. June 5, 1923, the vision was 20/20−2, with +.25 cyl. ax. 90°; presbyopia had developed. The cornea was clear, the fundus normal, and the vitreous showed a large floating ring, like a smoke ring, which Sir William Lister described at the International Congress last year as representing probable detachment of the vitreous.

R. H., aged sixty years, was seen in the spring of 1918 with iritis and secondary glaucoma of four months' duration. All of the laboratory and other tests had been made with negative results. He had no teeth. Treatment, including paracentesis of the cornea, seemed to have no effect on the course of the disease, and the vision was reduced to 2/200. On May 28, *x*-ray of the jaw showed an encysted and infected root, which was at once removed. On May 30 the eye was clearer, vision better, and the tension had fallen from 120 (McLean) to 55; June 20, vision 20/40; July 10, 20/20. The tension did not become normal until about August 1st. There was a mild return of the iritis a little over a year later, but when last seen, in February, 1922, the vision was normal and the eye well. The dental condition is shown in the photograph.

DR. W. H. WILDER, Chicago: It is interesting to see how the evidence is increasing that E. C. Rosenow is quite right in his ideas in regard to focal infection; and I feel quite sure he is also right in this, that there may be varying degrees of virulence in the same micro-organism In one case a bacterium might possess a virulence sufficient to excite what we would call an acute suppurative metastatic choroiditis, and in still another case the same kind of micro-organism with less virulence might be responsible for a more or less plastic process going on in the uvea. I think that is one thing we ought to consider in these cases. We do not now see the virulent cases we formerly saw, because evidently we do not so frequently encounter the virulent forms of micro-organism, nor do we have them sent out into the circulation in such great showers as in the days of pre-antiseptic surgery and midwifery.

I appreciate the essayist's reference to my remarks on that subject. However, I do not wish the impression to get abroad, as his

words might imply, that my experience antedates the advent of antiseptic surgery.

DR. EMORY HILL, Richmond, Va.: Dr. Greenwood's cases bring out the very difficult question that confronts us as to how to study such conditions. Recognizing, as we must, that intra-ocular inflammation is secondary to lesions elsewhere in the body, it follows that we are dealing with a secondary consequence. We are rather helpless in solving the problem of the etiology of these cases. They have not a single causal factor; there may be many.

I rise simply to suggest the propriety, as it seems to me, of regarding these cases as medical cases and placing them in the hands of the internist—not to the exclusion of the ophthalmologist's care, but placing the responsibility upon the man who is able to take a much more comprehensive view of the case and to search quickly and thoroughly for all foci of infection. In certain cases the result will not be any more beneficial to the patient, of course; but in the long run I feel that the results will be more beneficial to the patient if these cases are regarded primarily as medical cases and put into the hands of the medical man.

DR. ALLEN GREENWOOD (closing): I presented these two cases in the hope of starting discussion and did not intend in any way to go into the whole literature of the subject. I will state, in reply to the question of Dr. Fisher, that these cases were studied exhaustively. The young woman had various laboratory tests and was examined by two rhinologists twice with great care and with the aid of the *x*-ray, and everything possible was done to determine any other focal infection. There may have been some infection that escaped us, but the Wassermann and tuberculin tests were negative.

I have never seen tuberculosis of the eye come on with such intense rapidity. I considered the rapidity and the tremendous ecchymosis in this case ruled out a tuberculous process, which in my conception is chronic. In this case the disease was violent, sudden, and acute.

I did not wish to suggest that Dr. Wilder was so much the dean of all of us that he antedates asepsis, but he came into practice during the time when the carrying out of asepsis had not reached its present state, particularly in regard to obstetrics, for Dr. de Schweinitz has called attention to the fact that metastatic suppurative choroiditis used to be more common after childbirth than in any other condition.

OPTIC ATROPHY MANIFESTED BY VISUAL DISTURBANCE FOLLOWING DISTANT HEMORRHAGE

DELAMERE F. HARBRIDGE, M.D.
Phoenix, Arizona

The occurrence of visual disturbance followed by optic atrophy, after the loss of blood at remote parts of the body, seems of sufficient rarity to warrant recording each additional case coming under observation. This seems particularly true of the rather greater infrequency in the case of so common a condition as epistaxis.

Mrs. B., aged forty years, was a well-developed woman, weight 150 pounds, with a generally healthy appearance, but rather erratic temperament. Family history negative, so far as able to obtain. Personal history, widow, married about fifteen years ago, mother of twins (apparently healthy girls, aged thirteen years). She has suffered with frequent epistaxis of more or less severity all her life. Slight injuries, such as a cut finger, heal with no untoward symptoms. About three months previous to the birth of the twins she suffered a severe nasal hemorrhage. This was followed about twenty-four to thirty-six hours later by gradually increasing loss of sight, leaving her practically blind for upward of three months. Then followed a gradual improvement during the succeeding months, more marked in the right eye than in the left. This condition remained until about two years ago, February 4, 1916, when she suffered another severe attack of epistaxis, lasting about twelve hours and soiling a dozen bath towels. She fainted and upon regaining consciousness the left eye was blind; the right showed a marked reduction in vision. She was exceedingly ill for several days. During the ensuing period of three or four months vision again gradually improved to about that which obtains at the present writing. About two months previous to coming under observation, following a more moderate nasal hemorrhage, her

vision became misty. This, however, cleared shortly without any apparent further reduction of vision. These attacks of hemorrhage are usually preceded by pain in the nucha, radiating over the head to the brow. The left eye had been red and inflamed recently, and also two years previously. She believed that in some way this condition was associated with her impaired vision.

At the time of examination, V.R.E., 5/7.5; L.E., 5/60. Both irides respond to light and convergence. The right pupillary area was a shade under and the left a trifle over 5 mm. in diameter. To the nasal side in the left eye is a small inflamed pterygium. Right eye, media clear, disc horizontally oval, the inner half of its outline hazy, the rest, more indistinct, pallid. The vessels were pale; the arteries slightly undersized. Left eye, faint haze in the lower portion of the lens; a few fine vitreous opacities; disc vertically oval, not well defined; definite gray atrophy with no excavation. Arteries reduced in size and streaked; veins practically normal in size. Fields, right form reduced about 10–15 degrees. Left, for form reduced to 30 degrees; color to 10 degrees.

General Examination: Lungs and internal organs apparently normal; nasal cavity normal except the mucous membrane which was sensitive and apparently thinned, but no erosions or ulcers present; septum and turbinates practically normal. No well-defined nervous lesions were made out; the patient irritable and erratic. Wassermann, T.B. fixation, and urine, negative.

It is now twenty years since Sweet[1] presented his paper on optic atrophy following intestinal hemorrhage before this Society. In 1912, before the section on Ophthalmology of the American Medical Association, Zentmayer[2] made his excellent contribution. The purpose in again bringing the question before you is, that inasmuch as it presents some unsolved problems, the discussion may bring out certain phases which will lend support or confirmation to certain theories already offered, or suggest new possible explanations. While the condition is of infrequent occurrence, yet the possibility of it presenting itself, and usually with such serious results as to produce more or less permanent impairment of vision, seems to warrant an attempt at considering certain etiologic factors.

It does not follow any particular type, nor is it related to any particular degree of hemorrhage. Many suffer severe hemorrhage but do not develop optic nerve disturbance nor any apparent interference with vision. Yet, comparatively small but frequently repeated hemorrhages may result in serious impairment. The problem is particularly perplexing in a patient with negative laboratory findings and whose general appearance is that of health.

Careful studies of statistical data on this condition have been presented in the literature. A summary of these observations may be stated as follows: Haab[3] did not observe one undoubted case in 60,000 patients. Dufur[4] observed it but once in 30,000 patients. As to age, from young adult to middle life seems to furnish the greatest number of cases, yet the condition has been observed in the two extremes of life. Sex, apparently more frequent in females; this, however, should be qualified according to the source of the hemorrhage. While there are possibilities of serious visual disturbances due to hemorrhage from any part of the body, yet the greatest number are associated with intestinal or uterine bleeding, nasal hemorrhage occasionally, and other sources very infrequently. There seems to be a wide difference as to the amount of blood lost. Visual disturbance is usually bilateral, a small percentage being unilateral. The degree of loss of vision varies from serious embarrassment to blindness. One eye may show greater impairment than its fellow. Blindness usually occurs three or four days after the hemorrhage; in one instance, eighteen days. Impairment may clear up only to recur following subsequent hemorrhages. It may be permanent from the start. Sterling[5] estimates one-third remain blind. The balance recover to a degree, rather promptly at first, and then slowly, over a period of weeks to months, to fair improvement. About 10 per cent. will show fairly good visual acuteness. The fields vary widely as to the degree of contraction and the presence of scotomas. The fundus

appearance may show only slight haziness, a very moderate vascular contraction, retinal edema, neuritis or frank evidence of optic atrophy. It hardly seems correct to place within the scope of the condition under consideration cases in which either haziness or actual transient blindness occurs at the time of or immediately following the hemorrhage, which immediately and completely clears up with those more or less prominent changes coming on later.

The disturbance may be within the eye, the retrobulbar region, or the brain. It is more than likely that the pathology is not uniform. A few have been studied microscopically. The interval between the hemorrhage and the time of sectioning the eyes being considerable, these studies have not assisted materially. However, Goerlitz[6] was able to obtain, in his case, both eyes a few days after the onset of blindness. The ganglion cell degeneration theory of Ward Holden[7] seems to possess substantial possibilities; yet it is known that certain transient ischemias, such as result from toxic agents or vessel spasm, fully recover. The condition under consideration, however, is one in which vision is not usually lost for several hours to days, recovers to a certain point, but practically never entirely. The agent, whatever it may be, is active during this time, its destructive effect being permanent.

These above observations contribute much information of value. However, they are factors subject to considerable variation. The important questions for clinical investigation are an exact knowledge of the general health, the state of the individual's metabolism, his resistive powers, not only at the time but particularly preceding the attack. This demands careful search of the patient's personal history, the general physical well-being, together with laboratory investigations for some vague or obscure symptoms. The use of certain toxic agents, such as quinin, tobacco, or alcohol, should not

be overlooked. In this way possible progress may be made in discovering the underlying causative factor or factors.

In the case reported above there are certain outstanding features. The hemorrhage, likely venous, was from a frequent source and yet one of the less frequent in causing visual disturbance. Two serious losses of sight with fairly good recovery, followed by a mild transient attack. This in a temperamental female with a history, since childhood, of periodic nose-bleeding. During one of these attacks she was very ill, nauseated, and greatly prostrated for several days.

An endocrine imbalance is suggested. Variations in perimetric findings are at least suggestive—perchance a dysfunction of a polyglandular nature. Hypo-adrenalism impairs muscle tone and lowers blood-pressure. At times profuse bleeding occurs on account of endocrine gland disturbance; sometimes the administration of thyroid extract is successful in stopping such bleedings, and at other times suprarenal extract is beneficial.[8] Hetoghe,[9] Merklin and Walther,[10] Perles,[11] and Taylor[12] have all demonstrated these facts by experimentation. Bottaro and Fournier[13] report the case-history of a female, aged twenty years, subject to severe menstruation and epistaxis, but no eye symptoms. Thyroid therapy reduced the menstruation to three days and arrested the nasal hemorrhages. When the remedy was withdrawn, the disturbance immediately returned. Darier[14] used adrenalized serum successfully in hemorrhage causing visual disturbance. Underlying these known facts, however, there must be some metabolic process causing the endocrines to function wrongly.

Little help can be offered patients with profound visual disturbance coming under observation late. The conditions present are the end results of the injury. In early cases intravenous injections of adrenalized serum followed by transfusion of saline solutions and the administration of suprarenal and thyroid therapy seem to be the palliative measures indi-

cated which would afford an opportunity for a more complete physical investigation.

The literature since 1912 has been searched and all reported case records, as far as possible to obtain, have been summarized. These 18 case reports in connection with Singer's[15] 198 in 1901, and Zentmayer's 24 cases in 1912, making a total of 240 cases, give a fairly complete summary up to the present time. Ages ranged from thirty to fifty-seven years. Sex, 10 were females and 8 males. Hemorrhage, epistaxis 3, gastric ulcer 6, uterine 6, injury 1, amputation 2. All showed optic atrophy except two. Fields contracted to varying degrees. Visual disturbance occurred from twelve hours to ten days after the hemorrhage. Improvement in vision, from counting fingers to 6/7.5. Goerlitz's patient died, the eyes were examined microscopically a few days after the hemorrhage.

Pincus:[16] Five patients, all with optic atrophy following a papillitis. The ocular disturbance came on from two to eight days after serious hemorrhage; two due to amputation; one, epistaxis; one, gastric ulcer; one, uterine hemorrhage. One theory is the production of grave posterior cord lesion; the other, reduced blood-pressure, augmented by a reflex vascular tone.

Perrin:[17] First case, blindness followed two hours after a severe gastric hemorrhage. After intravenous serum injection, vision was partially restored. Second case, blindness four days after severe epistaxis. Fields became normal, vision 1/6.

Cantonnet:[18] Blindness following hematemesis. Vision improved; contracted fields remaining.

Terrien:[19] Female, aged thirty years. During the succeeding four months following confinement, at which time considerable blood was lost, the patient complained of impaired vision. V.R.E. = 1/4; L.E. = 1/5. Discs, atrophic and well defined; vessels, normal; fields, contracted with absence of the lower half.

Terrien:[19] Male, aged twenty-four years, suffered with a crushed leg. Twelve to fifteen days after the injury the discs were indistinct; the vessels were dilated; fields greatly contracted and almost entirely absent below. Gradually vision improved; some pupillary

reaction returned; atrophy of the discs was quite marked, and the arteries were somewhat narrower. He believed the trouble was of retinal origin.

Darier:[14] Female, sudden complete amaurosis of both eyes following metrorrhagia. No light perception or pupillary reaction. Sight was recovered after eighteen days, after a subconjunctival injection of mercury salicylarsinate.

Duhot:[20] Optic neuritis following profuse hemorrhage.

Oyenard,[21] A.: Optic atrophy following metrorrhagia.

Oyenard, A.: Female, aged forty-five years, following abortion bled until unconsciousness. Regaining consciousness, objects appeared misty; three days later vision was reduced to counting fingers at one meter. Later, V.R.E., 2/3; L.E. = 1; fields markedly contracted.

Calhoun:[22] Female, aged thirty-eight years, suffered a nervous breakdown four years previous to present attack. Profuse uterine hemorrhage lasting one week which followed the passage of large blood-clots. Then occurred a violent hemorrhage, from which she collapsed, becoming unconscious and nearly dying. Hemorrhage ceased. Ten days later when able to sit up discovered she was unable to see. This lasted three weeks when slowly sight was partially restored. Four months later, first ophthalmic observation was made. Patient, anemic and weak. V.R.E. = 20/100, with −2.75 sph. ⊂ −1.50 cyl. ax. 90° = 20/50; L.E. = 15/200, unimproved. Discs, very pale; retinal anemia; vessels, contracted; partial hemianopsia.

Goerlitz:[6] Male, aged fifty-seven years, hemorrhage from duodenal ulcer; blind within ten days, and death a few days later. Opaque discs and edematous retinæ. The vessels very thin and pale, no venous stasis. Sections showed intense edema of the disc. Between the nerve-fibers were peculiar projecting nodules consisting of polymorphous, partly nucleated formations. Behind the lamina cribrosa were foci of degeneration, possibly due to a thrombotic process.

Alt:[23] Male, aged forty-five years, exsanguinated and semi-unconscious, due to several hemorrhages from a gastric ulcer. Eyes examined one month later while in a partial stupor. Bare light perception in the right, and fingers at 6 feet with the left. Both pupils fully dilated; the right, fixed; the left, reacted slightly. Later, right pupil smaller, slight reaction, fingers at 6 feet. The left pupil reacted normally; vision, 1.00 sph. = 20/30. Fields,

nasal 10, above 15, out and down 20. The discs and vessels as when first observed.

Harbridge: Female, aged forty years, erratic temperament, suffered more or less severe epistaxis all her life. Three months previous to birth of twins suffered an especially severe hemorrhage, which was followed twenty-four hours later by loss of sight. Sight gradually improved during the succeeding months to practically normal. Eleven years later, following a very severe attack of epistaxis, at which time the patient was very ill, a second, but not as complete, loss of sight occurred. At time of examination, right field moderately contracted. V.R.E. = 5/7.5. Left field markedly contracted. V.L.E. = 5/60. Both nerve heads atrophic.

REFERENCES

1. Sweet: Trans. Amer. Ophth. Soc., v. x, p. 183.
2. Zentmayer: Jour. Amer. Med. Asso., v. lix, p. 1050.
3. Haab: See Zentmayer reference.
4. Dufur: See Calhoun reference.
5. Sterling: Ophth. Rev., v. xxiii, p. 219.
6. Goerlitz: Klin. M. f. Augenhk., v. lxiv, 1920, p. 764.
7. Ward Holden: Arch. Ophth., 1899, v. xxviii, p. 125.
8. Osborne: Text Book, 1922.
9. Hetoghe: Les Secretions Internes, Leur Influence Sur Le Sang, p. 72.
10. Merklin, P., and Walther: Bull. Mém. Soc. Méd. Hôp. (Paris), 1890, v. 7, pp. 859–864.
11. Perles: Semaine Médicale (Paris), 1907, v. 27, p. 298.
12. Taylor: Monthly Cyclopedia (Phil.), 1905, v. 8, pp. 298–300.
13. Bottaro and Fournier: Endocrinology, July, 1920.
14. Darier: Clin. Ophth., 1922, v. xxvi, p. 93.
15. Singer: Beitr. z. Augenhk., Hamb. and Leipz., 1902, v. vi, No. 53, p. 1.
16. Pincus: Arch. f. Ophth., v. xcviii, p. 3.
17. Perrin: Arch. d'Opht., v. xxxix, 1922, p. 53.
18. Cantonnet: Arch. d'Opht., v. xxxix, 1922, p. 53.
19. Terrien: Arch. d'Opht., v. xxxviii, 1921, p. 263.
20. Duhot: Arch. d'Opht., v. xxxiv, 1915, p. 782.
21. Oyenard, A.: Rep. Oftal. Hosp. Buenos Aires, v. ii, pp. 1–13.
22. Calhoun: Ophth. Rec., v. xxii, 1913, p. 358.
23. Alt: Amer. Jour. Ophth., v. xxix, p. 74.

TRAUMATIC NEUROLOGY OF THE EYE IN RELATION TO CEREBRAL AND OTHER INJURIES*

HUNTER W. SCARLETT, M.D.
Philadelphia

Cranial wounds comprised a large percentage of injuries of the World War, while ocular manifestations were among the most important diagnostic symptoms.

The mass of neurologic data at hand confirming previously known facts about traumatic conditions of the eye, and the theories advanced relative to the cortical localization of the retina, are of sufficient importance greatly to interest the ophthalmologist. Even a cursory perusal of the literature reveals the enormous field for study resulting from injuries to the central nervous system and from other conditions surrounding military operations. No such opportunity has ever before been afforded, and let us trust it will never again be presented under similar circumstances.

In approaching this subject it has been found convenient to discuss it, as far as possible, under anatomic headings, such as Brain, Spinal Cord, Peripheral Nerves, Orbit, Pupils, and Cervical Sympathetic Nerve.

Brain.—Uhthoff[1] said wounds of the eye formed 8 per cent. of all war injuries, while wounds of the head with hemianopsias formed 9 per cent. of visual disturbances following trauma. According to Pierre Marie, cranial injuries gave ocular manifestations in 10 per cent. of cases, such as cortical blindness, hemianopsias, and scotomas. In many instances they indicated intracerebral foreign bodies, which were confirmed by the *x*-ray.

Direct injury by shrapnel, rifle ball, or fragments of shell,

* Candidate's thesis accepted for membership by the Committee on Theses.

producing a loss of bony and brain substance, accounted for the majority of visual defects, although some were recorded without any visible external wounds. In many of the latter a small fracture of the inner table no doubt produced the accompanying lesion, which later improved or disappeared. Only a few cases are recorded where permanent damage to the visual apparatus resulted without evidence of an injury.

Hemianopsias in varying degrees and positions, with scotomas, were the most important symptoms of lesions of the occipital region. Axenfeld[2] said one-half of the cases of hemianopsias observed were of the bilateral inferior type, either quadrant or complete, indicating a lesion of the occipital lobe above the level of the calcarine fissure. Superior hemianopsias were rarely seen, as an injury causing this type would probably have involved the cerebellum, straight or lateral sinuses, or the torcular herophili, and would therefore have proved fatal.

Homonymous hemianopsias from gunshot wounds differ from those in civil practice, because of the arterial arrangement in the occipital area. The posterior and middle cerebral arteries meet in the region of the macular center, and if one is occluded by an embolus, this area receives nourishment from branches of the other vessel, therefore in civil practice hemianopsias rarely extend to the fixation point.

Prior to 1914 physiologists placed the cortical representation of the macula in the anterior portion of the visual area, while the periphery was located in the posterior portion. Intermediate areas from the macula to the periphery were allocated to corresponding positions from before backward. Schmid and Loquer,[3] however, reversed this order and placed the macula in the posterior portion of the calcarine fissure. Monakow and Déjérine believed the center for the macula was spread out over the entire occipital cortex.

Holmes,[4] in his comprehensive study of cranial injuries, deduced the following conclusions:

1. The upper half of each retina is represented in the dorsal, and the lower half in the ventral, part of each visual area.

2. The center for the macular and central vision lies in the most posterior part of the visual cortex—probably on the margins and on the lateral surfaces of the occipital lobes. The macula has not a bilateral representation.

3. The centers for vision subserved by the periphery of the retinæ are situated in the anterior parts of the visual areas, and serial concentric zones of the retinæ from the macula to the periphery are represented in this order from behind forward in the visual cortex.

4. Those parts of the retinæ adjoining their vertical axes are probably represented in the dorsal and ventral margins of the visual areas, while the retinæ in the neighborhood of the horizontal axes are projected on to the walls and floors of the calcarine fissures.

5. Severe lesions of the visual cortex produce complete blindness in the corresponding parts of the visual fields, or, if incomplete, an amblyopia, color vision being generally lost. White objects appear indistinct, or only more important stimuli, such as abruptly moving objects, may excite sensations.

6. Defects of vision in the fields of the two eyes are always congruous and superimpossible, provided no abnormality of the peripheral visual apparatus exists.

7. Lesions of the lateral surfaces of the hemispheres, especially of the posterior parietal regions, may cause certain disturbances of higher perceptual functions with intact visual sensibility, such as loss of visual orientation and localization in space; disturbance of the perception of depth and distance, visual attention loss, and agnosia.

The above deductions are, in the main, accepted by all who studied cranial injuries during the World War, but, as Holmes himself says, his conclusions cannot be regarded as final, for the determination of cortical representation of vision

based on injuries to the brain, without operation or necropsy, must be regarded with reservations. It is impossible to be certain the lesion is sharply defined, as softening from hemorrhage may alter the brain at an area more remote than that primarily affected.

Whether the macula has a unilateral or bilateral cortical representation is far from being settled. Howell,[5] speaking from the standpoint of experimental physiology, said the macula had a bilateral representation. Souques and Odier[6] reported the case of a soldier wounded in the right occipital region, traversing to the left side, and injuring both occipital lobes. He presented a macular hemianopsia and paramacular scotomas. This, they believed, indicated a decussation of the macular fibers.

Morax,[7] in discussing the pros and cons of a circumscribed cortical center for the macula, took the affirmative, but further said he had never found fixation disturbed in hemianoptic scotomas by a unilateral lesion, but found it lost when both occipital poles were traumatized. He believed it was necessary to admit of a small zone at the fixation point, of about one degree in extent, which had an overlapping innervation from each occipital lobe, otherwise the retention of fixation in unilateral occipital wounds could not be satisfactorily explained. He concluded:

1. Each macula, like the periphery of the retina, was divided vertically into two halves, each of which was connected with the corresponding occipital visual center of the same side.

2. The peripheral and macular centers were not identical, the latter being more posterior near the tips of the occipital poles.

3. Occipital lesions could affect the peripheral or macular centers either separately or conjointly, producing the different kinds of hemianopsias observed during the war.

4. The preservation of normal acuity of vision was com-

patible with destruction of one macular center, *i. e.*, the center in either the right or left occipital lobe.

Morax, referring to an article which he wrote with Moreau and Castellain,[8] said they had found the same alterations in the periphery of the macula as in the peripheral field properly speaking, *i. e.*, a quadrant, complete or irregular hemianopsia. This occurred either in conjunction or not with peripheral field changes.

Wilbrand and Saenger[9] also assumed that the macula had bilateral cortical connections, and reported several cases with hemianopsia to the fixation point, without loss of acuity of central vision. Fleisher and Ensinger,[10] analyzing 67 cases of gunshot wounds of the head, leaned toward the unilateral innervation of the macula.

Moreau[11] claimed the macula had a bilateral cortical innervation, and it was more important to study from a physiologic standpoint why central vision was so often intact in lateral and even bilateral hemianopsias, than to investigate the contour of lost areas of peripheral vision. He advocated complementary studies to determine the form, depth, dimensions, and color of objects, as a means of properly studying the acuity of vision in cerebral injuries. He divided the field of vision into three zones of perception, distinction, and central fixation from the periphery to the macula, as he said, roughly speaking, we perceived in the periphery, then we differentiated in the middle zone, and finally with central vision we conclusively saw.

According to Widmark, each macular fiber divides into two parts in the chiasm, one going to the macular center of each side, while Hirschberg and Rönne think the fibers cross in the retina and not in the cranial pathways. Lenz, partisan of a cortical macular center, believes commissures exist between the corpora quadrigemina and the macular centers, and that they traverse the corpus callosum, connecting the radiations of one side with the macular center of the opposite side.

Holmes said, in his conclusions, above quoted, that the hemianopic fields were exactly congruous and superimpossible. In a series of 13 cases Scarlett and Ingham[12] found defects of the visual fields, resulting from occipital lobe lesions, were roughly symmetric but not exactly superimpossible.

Riddock,[13] in discussing the appreciation of movement in the blind field and its prognostic value, stated that movement could be recognized as a special visual perception, and could be dissociated completely or partially from that of stationary objects; also appreciation of movement returned before that of the object itself, and in cases where there was perception of movement in the blind field, there was some return of vision, but where there was no perception of movement after several months, the field affected would remain blind. The types of dissociation were analogous to those of general somatic sense impressions occurring in cerebral lesions.

Marie and Chatelin,[14] in speaking of cranial injuries, said that lateral homonymous hemianopsia was most frequently due to lesions in the parietal region affecting the optic radiations, or to a projectile entering some other part of the skull and cutting the optic radiations in its course; but that it was seldom seen in direct injury to the occipital region, where it destroyed the cortical visual area as a whole. Lateral homonymous hemianopsia presented no particular clinical symptoms except that right hemianopsia almost always showed aphasia and some alexia.

In their opinion quadrant hemianopsias were usually caused by lesions of the optic pathways or of the corpora quadrigemina, although some were due to injuries of the radiations of the visual area. Later they[15] reported four cases with defects in the superior fields, three of superior quadrant hemianopsias, and one of bilateral superior scotoma. *X*-ray examination showed the presence of foreign bodies which had injured the inferior portion of the visual sphere and optic radiations. In three, the projectiles were in the parietal

region, a little above the level of the mastoid. Thus defects occur exceptionally in the superior fields, and should be sought for in wounds of the parietal and mastoid regions.

Heine,[16] in contrast to Marie and Chatelin, said hemianopsias were apt to be complete if the injury was at or near the occipital pole.

Epilepsy, with a quadrant hemianopsia, following a wound in the left occipital region, was described by Laignel, Lavastine, and Fay.[17] It came on with a visual aura of seeing a vertical line extending into a ray down and out in the right field. *X*-ray showed a foreign body in the left occipital lobe, corresponding to the superior calcarine fissure. They believed the epilepsy was due to a lesion in this area. Lereboullet and Mouzon[18] reported another case wounded by a ball in both occipital lobes, which developed epilepsy with aura of hallucinations. Vision diminished to complete blindness, and the hallucinations then disappeared. It was thought these were due to a lesion in the region of the calcarine fissure.

Thus far discussion has been concerned only with hemianopsia from lesions posterior to the primary optic centers. Although this was the most usual form observed, a few cases were recorded due to anterior lesions. A case of oblique hemianopsia from a wound of the optic chiasm was reported by Stewart and Griffith.[19] A piece of shrapnel had destroyed the right eye and had lodged above and in front of the sella turcica. Complete blindness of the left eye resulted temporarily. A month later the sight began to return in the nasal side of the left eye. Two months after the injury the disc was atrophic, the pupil was widely dilated, and a hemianopic reaction was present. The field showed an irregular hemianopsia, beginning thirty degrees to the inner side below, and extending to the same point on the outside above. The lesion was placed at the left side of the anterior portion of the chiasm, at the termination of the optic nerve. On the other

hand, it might have been located at the inner side of the optic nerve in front of the chiasm.

Another interesting case of homonymous hemianopsia from traumatism of the right optic tract was studied by Marie and Chatelin.[20] A soldier was wounded by dirt and stones thrown forcibly into his face from a shell explosion. Immediately he became blind in the left fields, and shortly afterward unconscious. On recovering he was entirely blind for a time, gradually regaining vision in the right fields. Ocular examination showed a complete left homonymous hemianopsia up to the fixation point, with normal acuity of vision. External musculature was normal, but there was an inequality of the pupils, the left being larger. The pupillary reaction of Wernicke was completely typical for the left eye. Fundus examination presented no retinal or macular lesions, but the right disc was very pale on the temporal side, while the left disc showed a diffuse atrophy. An *x*-ray revealed a foreign body a little above, behind, and to the right of the clinoid process of the sella turcica, corresponding to the right optic tract. Such a condition, due to traumatism of the optic tract alone, was rare, and the particular symptoms noted served to differentiate between lesions of the anterior neuron (chiasm and tract) and the posterior neuron (radiations and cortical area).

Inequality of pupils with the larger one on the side opposite to the lesion was important, as was the atrophy of the papilla, which was also more pronounced on the opposite side. This latter condition was due to the fact that the crossed fibers outnumbered the direct ones. The reaction of Wernicke and the modification of the papillæ are absent in central hemianopsias. In hemianopsia of cortical origin, with unequal pupils, the larger pupil is usually on the side of the lesion.

According to Holmes, achromatopsia did not occur with intact vision for white. Marie and Chatelin saw one case

following a concentric contraction of the fields, but it was difficult to explain the cause.

A series of 13 cases of head injuries studied by Scarlett and Ingham at the United States Army Hospital No. 11 illustrate a few of the points thus far discussed.

For a detailed account of this series with illustrations the reader is referred to the Archives of Neurology and Psychiatry, September, 1922, viii, pp. 225–245.

Hemianopic scotomas were divided into macular, paramacular and multiple. Small paracentral scotomas limited to the upper or lower homonymous quadrants were frequently encountered. Their position in the fields bore distinct relation to the site of the wound. Bilateral paracentral scotomas were less common. Anatomically the macula has a larger area of cortical representation than other parts of the retina, is more exposed, and thus the frequency of areas of blindness in the region of the fixation point.

Scotomas frequently gave valuable information as to the situation of the lesion of the visual pathways. If the scotomas in the two fields were exactly symmetric and superimpossible, a central lesion could be inferred. If, however, they were irregular, non-superimpossible, or unilateral, a lesion anterior to the chiasm, either of the optic nerves, retina, or choroid, was postulated. Marie and Chatelin[21] reported a case of hemianopic paramacular scotomas from an occipital wound, and a macular scotoma by a unilateral lesion of the retina, in the same patient. The same authors observed five other cases of macular and paramacular scotoma, as well as three of purely macular scotoma and four of the multiple type. In most of these cases there were lesions around the occipital protuberance, with penetration of fragments of shell or bone into the brain tissue. Usually there was complete blindness at first, with a rapid return of partial vision. Some exhibited signs of irritation of the visual cortex, with flashes of light, and one presented a scintillating scotoma.

Jefferson[22] saw a case, wounded in the occipital regions, presenting marked diminution of vision, with central scotomas and no disturbance of the peripheral fields. At the end of seven days the vision had returned to normal and the scotomas had disappeared. Irritative phenomena with scintillating scotoma and hallucinations were occasionally seen following injury to the occipital lobes. Such a case was seen by Marie and Patrikios.[23] Wound of the left occipital region with absolute macular and paramacular scotomas. Four months after the injury scintillating scotomas developed, and six months later hallucinations, coming on after the scotomas. In the beginning consciousness was not lost, but a few months after the appearance of the hallucinations the patient would become unconscious at the end of the hallucinatory period. The attacks came in rhythmic fashion: First, a severe one with hallucinations and loss of consciousness, then a mild one, with or without hallucinations, and no loss of consciousness. They would be separated by an interval of one month. The scintillating scotoma was simply an aura of the epileptic attack.

Concussion or cerebral commotion was a condition commonly observed among war injuries. According to Marie, Pieron, and Bouzansky,[24] this syndrome is expressive of a profound cerebral disturbance, manifested by various accidents. The cerebral affection is undeniable, but is purely functional, meaning that the organic basis is not known. It may be a vascular phenomenon or an affection of the nerve cells, but it is capable of retroceding, and rapidity of cures has often been observed in such grave conditions as blindness and deafness. On the other hand, there are cases which resist all therapeutic or suggestive measures.

Lepine[25] said that emotion should not be confounded with commotion, as the symptoms of the latter can be explained mechanically. Analogy can be found in a sudden atmospheric decompression or a brutal and simultaneous suppression of

air, which produces a dilatation of the deep vessels, causing a sudden battering, ram-like circulatory action, the effects of which are felt in non-extensible cavities, such as that in which the nervous system is encased. This circulatory action causes pain in the abdomen, dilatation of the vessels of the brain and cord, and at times a rupture of the vessels, producing bloody spinal fluid. Hemorrhage into the cerebrospinal fluid may disappear in a few days, but the hypertension remains.

Hypotension rarely results, in which case there is a dilatation of the retinal veins, with a feeble heart action.

Symptoms usually referable to the eyes are changes in the retinal vessels and alterations in the pupils. The condition may affect the sympathetic, cause general paralysis, congestion of the brain, and general vasomotor disturbances.

Commotional lesions producing ocular manifestations may be central or peripheral. The former, either discrete or diffuse, were more frequent, and consisted in disturbance of the visual or nerve centers. Conditions simulating meningitis and pseudo-tabes, as well as the actual production of exophthalmic goiter, and the oculo-sympathetic syndrome of Claude Bernard-Horner, were encountered.

Pastine[26] studied the case of a soldier thrown to the ground by a bursting bomb. He was unconscious for a short period, but there was no evidence of external injury. He developed external and internal ophthalmoplegia, with diminution of vision, became deaf, and had anesthesia and hypesthesia of the fifth nerve, with disturbance of equilibrium. Recovery was slow. Lesions were due to minute hemorrhages in the nuclei of the affected cranial nerves. Wilson[27] reported a soldier's injury in the posterior mid-line, which caused unconsciousness at first, with complete blindness that gradually recovered, accompanied by slight hallucinations lasting two weeks. Examination two months later showed the pupils and fundi negative, with concentric contraction of the

fields, which could be developed into spinal curves through fatigue. The author thought it was an example of severe concussion, but the exact nature of the lesion was unknown.

Convergence of both eyes in certain cases of concussion was seen by Descoups, Euzierre, and Merle.[28] This symptom appeared at times when the eyes came to a stop, but at other times it was necessary to produce lateral or other movements to affect it. This indicated a disturbance in the motor equilibrium between the adductors and abductors, due probably to small cerebral lesions. Marked convergence with contraction of the pupils followed air concussion in a case observed by Zakharchenko.[29]

Two interesting cases of concussion were studied by Pitres and Marchaud. In the first they found symptoms simulating meningitis. There was a Kernig sign, stiffness of the neck, headache, and ptosis, with internal strabismus. The spinal fluid contained blood. The patient improved under repeated lumbar punctures, and after ten months only a functional paresis of the legs remained. The second case was one of pseudo-tabes, which gradually improved. The patient had abolition of patellar and Achilles reflexes, Romberg and Argyll-Robertson signs, with motor incoördination. He improved, did not have a gastric crisis nor muscular weakness, so tabes was excluded.

A rare condition following commotion was reported by Babonneix.[30] Two cases of Basedow's disease were seen following a severe concussion. It proved, contrary to opinion, that exophthalmic goiter could be caused by traumatic commotion.

Another phenomenon infrequently met with was the Claude Bernard-Horner syndrome. Leri and Thiers[31] had rather a unique case in that, together with the oculo-sympathetic lesion, it had rupture of both tympanic membranes, with resulting deafness in the left ear. In addition there was adduction of the left eye, whenever and wherever a peripheral

stimulation was produced by hot or cold water or by pinching. It made no difference whether it was on the right or left side, on the ears, nares, hands, or feet. They concluded adduction had some relation to labyrinthic troubles, as this patient also showed a disturbance of equilibrium, with a tendency to fall to the left.

Amaurosis following a severe concussion in which unconsciousness lasted twenty days was succeeded by meningeal symptoms. Accompanying these was a slight external strabismus of the left eye and limitation of all extra-ocular movements. There was a slight involvement of the discs, probably from a retrobulbar neuritis. The condition improved under hypodermic injections of mercury. The author believed the condition was one of severe concussion with a luetic taint. Three cases of temporary blindness produced by the commotion of a shell exploding near by was the subject of a discussion by Crouzon.[32] The blindness gradually disappeared and vision returned.

According to Dupouy,[33] true cerebral commotion with organic lesions usually presents a mydriasis with unequal pupils, while Henri Claude reported choked disc among other symptoms. All were apparently benefited by lumbar punctures.

The most constant of the peripheral symptoms of concussion were manifested in the pupils. Among these mydriasis was more frequently seen, although unequal and irregular pupils, with or without loss of light reflex, paradoxic light reaction, and Argyll-Robertson pupils were not uncommon. The changes were usually transitory, lasting from three to twenty days, and ultimately disappeared. In cases presenting blood in the spinal fluid it was a question whether the toxin from the blood caused these pupillary alterations, but Guillain and Barre[34] thought they were due to peripheral changes, either a true commotion of the retina or of the

nerves of the intrinsic eye muscles resulting in temporary asthenia of these muscles.

A converging spiral contraction of the visual field was a rare manifestation of commotion, but Mairet and Durante observed such a condition. It appeared in only one field, and therefore hysteria, fatigue, and a central lesion were eliminated. There was no ophthalmoscopic lesion of the retina or optic nerve. They believed it due to a veritable claudication of the retina, dependent on a vascular disturbance, interfering with the regular nutrition of the retina.

General head injuries, aside from those producing concussion or coming under a special anatomic heading, were not infrequently observed, and in many instances the symptoms resulting therefrom were due to the intracranial hypertension and were relieved by lumbar punctures.

Terrien[35] mentioned three essential symptoms following such injuries, namely, transient diplopia, narrowing of the visual fields, and papillary stasis. Pierre Marie described another syndrome due to cranial injuries, the principal symptoms of which were headache and pseudo-vertigo. This was seen in 30 per cent. of head cases, especially in frontal and occipital wounds. Babinski said, in head injuries without apparent organic lesions, there would be residual trouble, indicated by papillary hyperemia and vertigo. Bilateral Argyll-Robertson pupils from a bursting shell, which knocked the patient down but produced no visible wound, were seen by Bergl.[36] Lues was eliminated, and the condition disappeared in three weeks.

According to Sollier, mydriasis was an important symptom in head injuries, being present in 52 out of 79 cases. It was more frequent after frontal wounds, and was either unilateral or bilateral. When unilateral, it was more often on the side opposite the lesion. The cause was not discovered.

Frequently cranial wounds were followed by a marked loss of vision, amaurosis, unilateral or bilateral, or complete

blindness. It was often impossible to determine the exact cause. Some cases revealed trouble with the extrinsic motor apparatus or lesions of the fundus. A comparatively rare lesion, observed especially after frontal wounds, was a spotted hemorrhage in the macula or an annular white area (hole in the macula).

A case of transitory cortical blindness from an occipital wound was seen by Rosenmeyer. The condition lasted eight days.

Acceleration of the oculocardiac reflex in head injuries, especially of the frontal lobe, was reported by Carlo Beta.[37]

Cerebellar lesions, according to Holmes,[38] were characterized by the deviation of the eyes to the side opposite to the lesion. This condition lasted several days, and was known as the skew position. It was difficult to make the patient so affected move his eyes conjugately to the injured side. Vertical movements and convergence were not similarly affected. Nystagmus, seen, as a rule, only on fixation, was present in most cases. In one case a soldier developed trouble in station and equilibrium. Eye examination revealed nystagmus on extreme lateral movements, or passive movements of the head. Oscillation appeared when the cornea approached the angle of the orbit, most pronounced to the right. He had bilateral choked discs with hemorrhages. Vision was markedly reduced. At autopsy a tumor at the ponto-cerebellar angle was found. Another case of cerebellar disturbance presented headache, vomiting, lateropulsion, nystagmus, and complete paralysis of the right internal rectus. In one month the patient was well.

Spinal Cord and Fluid. In a patient who received a severe trauma of the posterior cervical region Claude and Meuriot[39] saw the general signs of intracranial hypertension, with vomiting, vertigo, venous hyperemia of the retina, and papillary stasis. There were also local signs of pressure, producing irritation of the cervical sympathetic, with exophthalmos and

mydriasis. This case rapidly improved after a lumbar puncture. In another case of trauma in the occipital region Kutzinski reported the discharge of cerebrospinal fluid, with bilateral choked discs. Guillain observed hypertension of the cerebrospinal fluid with bilateral choked discs, peripapillar hemorrhages, and loss of tendon reflexes, following the ligature of the internal jugular vein in a wound of the cervical region. The fluid was under extreme pressure and the condition improved after three lumbar punctures. Symptoms of cerebrospinal hypertension, from a contusion of the cervical region of the spinal cord, were the result of sympathetic irritation, and consisted of mydriasis and exophthalmos.

Peripheral Nerves: Affections of the peripheral nerves were, for the most part, of central origin, but in some instances it was difficult to isolate a cerebral lesion causing peripheral symptoms from a purely peripheral lesion. Andre and Thomas saw a case in which the facial, the lingual, and superior maxillary nerves were sectioned by the same missile. A tongue of the temporal muscle was attached to the orbicularis, with a fair result. The writer personally observed a case in which a bullet entered the left temporal region, severing the left optic nerve, and coming out through the right orbit, destroying the right eye. A second case presenting a wound of entrance in the left mastoid region, and one of exit in the right malar region, showed a typical atrophic right optic nerve. In this instance there was probably a fracture of the orbital bones, pinching the nerve.

Koenig and Lafage described a very interesting case in which the patient was wounded in the right eyebrow by a shrapnel ball. He developed ptosis and complete paralysis of all the eye muscles, with maximum dilatation of the pupil on the right side. Vision was lost, due to a rupture of the choroid, while the ophthalmoplegia was due to a fracture radiating from the sphenoidal fissure and the presence of a hematoma. The x-ray showed the ball deep in the orbit. In

the case of Uhthoff[40] there was a lesion of the first and second branches of the fifth nerve, causing epithelial erosion of the cornea, anesthesia of the cornea, and absence of lacrimation. A foreign body was located in front of the Gasserian ganglion on the right side.

Orbit and Globe. From the extensive studies of Lagrange[41] it was learned that certain laws governed injuries of the orbit with conservation of vision:

1. When a projectile passes above the orbit, involving the frontal bone and cerebrum, fractured radiations extend to the optic foramen and sphenoid fissure with consequent effect upon motor and sensory nerves.

2. When it passes below the globe, without fracturing the orbit, results of concussion occur, producing severe macular lesions.

3. When it fractures the orbit, there are concussion lesions in the macula and choroid. The latter occur in the form of a rupture, where the sides of the orbit are affected.

4. When it traverses the orbit without touching the globe, the same lesion occurs, especially a tearing of the orbital contents, sectioning of the optic nerve, and at times a tearing of the pupil.

5. When the projectile touches the globe tangentially without rupturing it, there are produced, immediately at the point of contact, lesions such as rupture of the choroid, detachment of the retina, and retinitis proliferans. The macula is often affected, but never separately.

Ormond[42] said there were four ways in which concussion effects were produced on the eyeballs: 1. By a missile traversing the orbit without rupturing the globe. 2. By vibrations, the results of blows upon the orbit and face, transmitted to the interior of the eye. 3. By vibrations, from direct blows, on the eye, through the corneoscleral coat to the interior of the eye. 4. By vibrations, the results of air pressure or windage. He reported the case of an officer who had his

lids torn off, and an eyeball torn out of the socket, by a shell exploding over him, though he was not touched by a piece of metal. In the same manner hemorrhage and injury to the macula, leaving a central scotoma, were produced. Laceration of the pupil, iridodialysis, defects of accommodation and hippus, were noticed as a result of the shock. Rupture of the choroid and retina were due to injury to the so-called dangerous area of Dantrelle, which is the area extending 1 cm. back from the edge of the orbit. Detachment of the retina was present in 10 per cent. of wounds in this area. According to Collins, edema of the retina and pigmentary changes were commonly the result of contusion.

Speaking of disturbances of the globe from a sudden displacement of air by the explosion of a large shell, Landolt[43] said it was a mistake to believe that intra-ocular lesions were due simply to air displacement, but thought there was always evidence of an injury, either direct or secondary to trauma in some other spot. Vielle frequently found foreign bodies in such cases.

Atrophy of the optic nerve was frequently seen, not only in wounds involving the orbit, but in face wounds, without any external visible lesion of the eyeball. Here again there was a transmission of shock through the bony structures, probably causing a fracture of the orbit near the optic foramen, with subsequent injury to the optic nerve.

Pupils and Ocular Movements. Alterations in the size, shape, and reaction of the pupils were fairly constant signs in head injuries, where they produced Argyll-Robertson pupils or simply a mydriasis. The latter was present more frequently in frontal wounds, 14 out of 16, next in temporal lesions, 11 out of 15, then parietal injuries, 24 out of 40, and finally occipital wounds, 3 out of 8. Mydriasis was bilateral in one-half of the cases of head injuries, usually more pronounced on the side opposite to the lesion. When unilateral, it was crossed in relation to the lesion in three-fifths of the cases.

Prior to 1909, it was thought that lues was the sole cause of Argyll-Robertson pupils, when Guillain, Rochon-Duvigneaud, and Trosier demonstrated that it might result from trauma to the cerebral peduncles. Dufour[44] described a case, wounded by the explosion of an obus, which developed an Argyll-Robertson pupil, with a slight cerebellar gait. *X*-ray and Wassermann examinations were negative. The author thought there was a lesion at the level at the peduncular nuclei of the third nerve. He thinks there are separate cells in the third nerve nucleus responding to light stimulus which might explain the Argyll-Robertson pupil.

Paralyses of the intrinsic and extrinsic muscles having been touched on in previous paragraphs, the discussion of ocular movements will be confined to nystagmus and nystagmoid movements. Cerebellar lesions were the most prominent in affecting the muscular equilibrium of the eyeballs, and numerous cases of gunshot wounds in this region were recorded, with resulting nystagmus. Of equal interest were those cases which resulted from wounds in other parts of the brain. Déjérine and Mouson described a soldier wounded in the left parietal region, with resulting paralysis of elbow, arm, and hand on the right side, which rapidly improved. At the end of six months ocular movements were full, but there was a slight transitory nystagmus on looking to the right. Objects placed in the right field were not seen as distinctly as those in the left field.

Cervical Sympathetic. The first clinical description of the oculo-sympathetic syndrome was given by Horner in 1861, when he described the classic symptoms of enophthalmos, miosis, and narrowing of the palpebral fissure, following a lesion of the cervical sympathetic nerve. The first case of a traumatic nature was reported during the Civil War by Mitchell, Moorehouse, and Keen, who described one due to a gunshot wound of the neck.

A better appreciation of the symptoms of this syndrome

can be obtained by a glance at the anatomy and physiology of the cervical sympathetic. The ciliospinal center of Budge is situated at the level of the seventh and eighth cervical and the first to the fourth dorsal vertebræ. The pupillary fibers probably proceed from the seventh and eighth cervical and the first dorsal roots, while vasomotor and pseudomotor fibers proceed from the last three roots. They all pass into the cervical ganglia, inferior, middle, and superior, from whence they are collected into the internal carotid plexus. Here they divide, the more inferior branches going to the sweat-glands and blood-vessels of the face, and the superior ones going by the way of the ophthalmic branch of the trigeminal nerve to the ciliary ganglion, and then through the long and short ciliary nerves to the eyeball and orbit. Here they supply the unstriped muscle-fibers comprising the musculus orbitalis of Müller, which is in the periosteum and fills in the fissures of the orbit. They also supply the unstriped fibers in the levator muscle of the lid, the tarsal muscles, and the dilator fibers of the iris. A lesion producing a stimulation or one cutting off the supply to these unstriped fibers causes characteristic responses. In the first instance there is an exophthalmos, widening of the palpebral fissure, and mydriasis. In the second the reverse occurs, namely, an enophthalmos, miosis, and narrowing of the palpebral fissure. Other symptoms may or may not accompany the latter. Anhidrosis has been noted if the vasomotor and pseudomotor fibers have been cut. Hemifacialis and heterochromia irides have been observed.

Bussy[45] reported a case of evident irritation of the ocular sympathetic, with transitory amaurosis, mydriasis, and anemia of the retina, following a severe bombardment.

An interesting Claude Bernard-Horner syndrome, present on the same side as the lesion and disappearing at irregular intervals, was seen by Marie and Benisty; while Faure and Bearline studied one in which the difference between the two

pupils alternated from side to side, the right being larger at one examination and the left at the next. Hyperemia of the conjunctiva was always present on the side of the miosis. It appeared as though the ciliospinal center of Budge was kept in a pathologic balance, now on one side, now on the other. It resembled the alternating mydriasis of de Lapersonne and Cantonnet, with the difference of being a miosis instead of a mydriasis.

Numerous types of injuries caused the oculo-sympathetic syndrome, such as bayonet thrusts, sabre and knife wounds, pieces of shrapnel, and those from machine guns and rifle balls. Laignel and Lavastine saw a wound from a rifle ball which presented the appearance of pulsating aneurysm with the Claude Bernard-Horner syndrome. They also observed this condition due to a tuberculous pleurisy at the right apex of the lung. Pollack reported a case with the wound of entrance above the upper central incisor and exit behind the right mastoid. Besides the ocular symptoms there were hoarseness, difficulty in speaking, and regurgitation of food.

Seldom did this syndrome occur alone but was associated with hemiplegia, tetraplegia and quadriplegia. The most common variety of paralysis was the Klumpke type, with atrophy of the small muscles of the hand.

In civil life the usual causes of the oculo-sympathetic syndrome are cervical ribs, enlarged glands, mediastinal tumors, and aneurysms.

Eleven cases illustrating the common symptoms and signs of Horner's syndrome, namely, enophthalmos, ptosis, miosis, narrowing of the palpebral fissure, and the discrepancy between the two pupils on the instillation of cocain, were personally observed by the writer. The records of this series, with charts and photographs, were published in the Archives of Neurology and Psychiatry, June, 1920, iii, pp. 636–653.

General Conclusions

1. The nervous system may sustain severe organic and psychic damage, but is capable of tremendous recovery.

2. The macula has a circumscribed cortical center in the posterior portion of the visual area, but the question has never been definitely settled as to whether it has a unilateral or bilateral innervation, although the weight of evidence seems to favor the latter. The preservation of normal acuity of vision is compatible with the destruction of one macular center, either the right or the left.

3. Hemianopic fields are roughly symmetric, but are not always exactly superimpossible. Superior defects are less frequent than inferior.

4. Visual fields are gradually restored from the center toward the periphery. White objects are recognized before colored ones

5. The character and form of scotomas may give valuable aid as to the location of the lesion causing them.

6. Concussion producing ocular manifestations was seen more often than other cerebral injuries. Pupillary changes were the most constant symptoms of this condition.

7. Mydriasis is the most important symptom of general head injuries, especially of frontal wounds. It is usually on the side opposite the lesion.

8. Argyll-Robertson pupils are not necessarily the result of lues. They may be caused by concussion or general head injuries affecting the cerebral peduncles. They improve as the general condition ameliorates.

9. Lumbar puncture frequently repeated is a valuable procedure in relieving the symptoms of cerebral concussion, general head injuries, and wounds of the spinal cord.

10. In sympathetic nerve injuries lower lesions affecting the brachial plexus roots, through which sympathetic fibers run, are the most severe. Lesions higher up, involving the

sympathetic nerves, produce less severe symptoms, as a rule, than root lesions. Contusions of the cord result in the least pronounced phenomena, and are more prone to complete recovery.

11. Pupils of cases with root and nerve lesions do not usually dilate under cocain. Those with cord contusions do dilate.

REFERENCES

1. Uhthoff: Hemianopsias from Cranial Wounds, especially of the Occipital Region, Klin. M. f. Augenh., lv, p. 104, July, August, 1915.
2. Axenfeld: Hemianopsia from Cranial Injury, Klin. M. f. Augenh., lv, p. 126, July, August, 1915.
3. Schmid and Loquer: Virchow's Arch., 1900, p. 158.
4. Holmes: Disturbances of Vision by Cerebral Lesions, Brit. Jour. Ophth., 1918, ii, p. 353.
5. Howell: Text-Book of Physiology, 1908, pp. 198–199.
6. Souques and Odier: Revue Neurologique, August, Sept., 1917, p. 45.
7. Morax: Discussion des Hypotheses faites sur les Connexions Corticales des Faisseaux Maculaire, Ann. d'Ocul., 1919, cl, p. 25.
8. Morax, Moreau, and Castellain: Les Differents Types d'Alterations de la Vision Maculaire dans les Lesions Traumatiques Occipitales, Ann. d'Ocul., 1919, clvi, p. 1.
9. Wilbrand and Saenger: Neurologie des Auges, 1917.
10. Fleisher and Ensinger: Klin. M. f. Augenh., 1920, lxv, p. 181.
11. Moreau: Sur les Troubles de la Vision Maculaire Produit par les Lesions Traumatiques de la Region Occipitale, Ann. d'Ocul., 1918, clv, p. 357.
12. Scarlett and Ingham: Visual Defects Caused by Occipital Lobe Lesions, Arch. of Neurol. and Psych., Sept., 1922, viii, pp. 225–245.
13. Riddock: Dissociation of Visual Perception Due to Occipital Injuries, with Special Reference to the Appreciation of Movement, Brain, 1917, xl, p. 15.
14. Marie and Chatelin: Les Troubles Visuels aux Lesions des Voies Optiques Intra-Cerebrales et de la Sphere Visuelle Corticales, dans les Blessures du Crane par Coup de Feu, Revue Neurol., 1915, Nos. 23, 24, p. 882.
15. Marie and Chatelin: Les Troubles Visuels Consecutifs aux Blessures des Voies. Optiques Centrales de la Sphere Visuelle Corticale, Soc. de Neurol., Seance de 6 Janv., 1916.
16. Heine: Brit. Jour. Ophth., 1918, ii, p. 12.
17. Laignel, Lavastine, and Fay: Epilepsie a Aura Visuelle avec Hemianopsie en Quadrant par Lesion Occipitale, Revue Neurol., 1918, i, p. 500.
18. Lereboullet and Mouzon: Halluc. de la Vue et Crise Jacksonienne dans Un Cas de Lesion du Cortex Visuel, Revue Neurol., 1917, ii. p. 17.
19. Stewart and Griffith: A Case of Oblique Hemianopsia from a Wound of the Optic Chiasm, Lancet, 1916, July 15, p. 104.
20. Marie and Chatelin: Un Cas de Hemianopsie Laterale de la Bandelette Optique Droite, Revue Neurol., Nov., Dec., 1915, p. 1230.
21. Marie and Chatelin: Scotomes Para Maculaites Hemianopsiques par Lesion Occipitale et Scotome Maculaire par Lesion Retinien Unilateral, chez le Meme Blesse, Soc. de Neurol. de Paris, Seance 29 Juin, 1916.
22. Jefferson: Brain Injury with Scalp Wounds, without Fractures, Brain, June, 1919.

23. Marie and Patrikios: Phenomenes d'Irritation de la Sphere Visuelle et Mal Comitial, Consecutifs a une Blessure de la Pointe du Lobe Occipital Gauche, Soc. de Neurol. de Paris, 3 Mai, 1917.
24. Marie, Pieron, and Bouzansky: Le Syndrome Commotionel au Point de Vue du Mechanisme Pathogene et de l'Evolution, Bull. de l'Acad. de Med., 22 Juin, 1915, p. 710.
25. Lepine: La Commotion des Centres Nerveux par Explosion. Considerations Pathogeniques et Cliniques, Bull. de l'Acad. de Med., t. lxxv, No. 27, p. 9, 4 Juillet, 1916.
26. Pastine: Paralisi Multiple dei Nervi Crainei da Scroppia da Granata, Senza Lesione Externi, Riv. di Patol. Nerv. e Ment., 1918, xxxiii, p. 1.
27. Wilson: Lesion of the Visual Center from War Concussion, Lancet, cxciii, No. 1, p. 1, July 7, 1917.
28. Descoups, Euzierre, and Merle: Bull. et Mêm. de la Soc. Méd. des Hôp. de Paris, An. xxxiv, pp. 385–389, 1918.
29. Zakharchenko: Un Nouveau Syndrome dans les Contusions Aeriennes, Gaz. Russe Psych., No. 4, 1915.
30. Babonneix: Deux Cas de Goitre Exophtalmique Surveniss a la Suite d'une Commotion Nerveuse, Bull. et Mêm. de Soc. Méd. des Hôp. de Paris, 1 Juin, 1917, pp. 738–739.
31. Leri and Thiers: Syndrome Oculo-sympathetique de Claud Bernard-Horner par Commotion d'Obus. Phenomene de l'Adduction Oculaire, provoque par toute Excitation Peripherique, Soc. de Neurol. de Paris, 5 Juin, 1919.
32. Crouzon: Cecite Temporaire provoque par l'Eclatement d'Obus a Proximite, Bull. et Mêm. de la Soc. Méd. des Hôp. de Paris, 22 Janv., 1915, pp. 57–59.
33. Dupouy: Notes sur les Commotions Cerebro-medullaires par l'Explosion d'Obus sans Blessure Exterieure. Bull. et Mêm. de la Soc. Méd. des Hôp. de Paris, An. xxxi, Nos. 31, 32, p. 926, 29 Octobre, 1915.
34. Guillain and Barre: Les Troubles des Reactions Pupillaires dans la Commotion par Eclatement des Gros Projectiles sans Plaie Exterieure, Bull. de l'Acad. de Méd., 1917, 21 Aout, p. 156.
35. Terrien: Valeur Diagnostique du Syndrome Oculaire d'Hypertension dans les Blessures du Crane, Paris méd., 1918, No. 41, p. 277.
36. Bergl: Deut. med. Woch., xxxix, p. 1161, Sept. 23, 1915.
37. Carlo Beta: Rivista Italiana di Neuropatologia Psichiatria ed Elettroteropia, xi, p. 193, July, 1918.
38. Holmes: Unilateral Lesions of the Cerebellum. Disturbance of Ocular Movements, Nystagmus, Brain, 1917, xl, p. 461.
39. Claude and Meuriot: Syndrome of Cranio-spinal Hypertension following Contusions of the Cervical Vertebræ, Rev. Neurol. and Psych., July, 1917, p. 240.
40. Uhthoff: Klin. M. f. Augenh., April, May, 1915, p. 391.
41. Lagrange: Bull. de l'Acad. de Med., t. lxxv, No. 26, pp. 771–781. 22 Juin, 1916.
42. Ormond: Concussion Injuries, Trans. Ophth. Soc. U. K., 1917, xxxvii, p. 60.
43. Landolt: Apropos des Desordres Oculaires dus au Seul Deplacement de l'Air par Explosion des Gros Projectiles, Reunion Med. de la VI Armée, 4 Nov., 1915.
44. Dufour: Signe Argyll-Robertson Unilaterale Consecutif a une Blessure du Guerre, Soc. de Neurol., 1917, i, p. 130.
45. Bussy: Amaurose Transitoire chez les Commotiones, Ann. d'Oculi., clv, p. 423, 1918.
46. Calhoun: Causes of Heterochromia Irides with Special Reference to Paralysis of the Cervical Sympathetic, Amer. Jour. Ophth., April, 1919, p. 255.

EXAMINATION OF THE BLIND SPOT OF MARIOTTE*

CONRAD BERENS, JR., M.D.
New York

This paper will be limited to the discussion of a simple clinical routine for distinguishing the abnormalities of the blind spot, and no attempt will be made even to outline all the methods of examination.

It may not be unprofitable to quote the description of the first method of examining the blind spot, as given by Mariotte[1] himself:

"Having often observed in anatomical dissection of men as well as brutes, that the optick nerve does never answer just to the middle of the bottom of the eye, *i. e.*, to the place where is made the picture of the objects we directly look on, and that in man it is somewhat higher and on the side towards the nose; to make, therefore, the rays of an object to fall upon the optick nerve of my eye, and to find the consequence thereof, I made this experiment; I fastened on an obscure wall, about the hight of my eye, a small round paper, to serve me for a fixt point of vision; and I fastened such another on the side thereof towards my right hand, at the distance of about 2 feet; but somewhat lower than the first, to the end that it might strike the optick nerve of my right eye, while I kept my left shut. Then I placed myself over against the first paper and drew back little by little, keeping my right eye fixt and very steady upon the same; and being about 10 feet distant the second paper totally disappeared."

This experiment convinced Mariotte that the retina was

* Candidate's thesis accepted for membership by the Committee on Theses.

continuous across the place of entrance of the nerve, from which he argued that the choroid was the seat of visual sensation, although he concluded by saying: "Upon this, I desire you would give me your thoughts with freedom, since I am none of those that love to obtrude conjecture by demonstration."

Before studying the method of examining the blind spot we will consider a few of the indications for making the examination:

1. Whenever the vision cannot be improved to normal by correcting lenses, no cause for this phenomenon being evident.

2. When there is a history of headache or nasal trouble, chronically inflamed eyelids or conjunctivæ, or congested eyes that do not improve rapidly under treatment. These symptoms and physical signs lead one to suspect sinus involvement, particularly if accompanied by retrobulbar tenderness.

3. When dacryocystitis or stenosis of the nasolacrimal duct is present, frequently accompanied by sinus disease as an etiologic factor.

4. When glaucoma is present or suspected, or disease or anomalies of the deeper structures of the eye, particularly when the optic nerve is involved.

Since the discovery of the blind spot, many methods of examination have been proposed. The most important factor in the delimitation of the blind spot after the radius has been adjusted is the steadiness of fixation. These factors are controlled by the confrontation test with a meter string, and by this method patients may frequently be shown that they have a blind spot, after which it becomes possible to outline it by one of the recording methods. The following method of outlining the blind spot by the confrontation method proves particularly useful for neurologic patients, whose fixation is frequently difficult to control. The con-



Fig. 1.—Front view of hand campimeter showing 5 x 8 inch record card in place.



Fig. 2.—Back of hand campimeter.

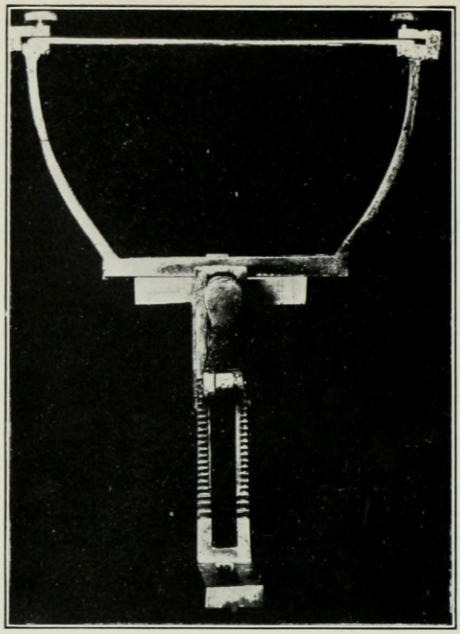

Fig. 3.—Mouth-bit fixation for use with Hare perimeter, which permits vertical lateral and anteroposterior adjustment.



Fig. 4.—Adjustable tube to be used in a trial-frame in obtaining binocular fixation at 27 cm.

frontation test as usually described and practised is unreliable, at least in my hands, because of the examiner's inability to maintain a fixed distance with the test object. However, with the aid of a modified Maddox[2] rule, or with an ordinary string one meter in length, the test may be made with accuracy. The patient holds the end of the meter string on a level with the right eye, while the observer holds the other end on a level with his own left eye. The eye not under examination is closed or covered, and a white-headed pin or point of light is tied into or passed through the string at 50 cm. and carried temporally slightly below the horizontal, eye fixating eye, until the blind area is found and compared with that of the observer. This method is rapid but accurate, for it controls distance and fixation, and with a little practice will be found to be a helpful clinical test.

In every case it is well to have the record of the size of the blind spot even when normal, and for roughly outlining the limits of the blind spot by the stereoscopic method the Haitz charts are satisfactory. This method will not detect slight changes, but has clinical value where a rapid simple test is required.

The Peter[3] hand campimeter is a useful instrument for bedside and office examinations, an apparatus of this type being desirable, particularly if the charting can be done directly on a card for filing purposes.

The radius of this instrument (6.5 inches) is too short, for without magnification the blind spot at this distance is too small, and well within the near point of presbyopic patients, even with their correction. Furthermore, there is no way of adjusting the distance from the point of fixation, which, as is the case with all non-adjustable apparatus, permits errors, for Cohn[4] has shown in normal subjects variation of 22 mm. in the position of the cornea in relation to the orbital margin.

The main disadvantages of the Peter campimeter are

overcome, at least in part, by an instrument made by E. B. Meyrowitz, having a rack and pinion for adjusting the distance from the point of fixation. The distance from the cornea to the point of fixation is 27 cm., and a 5″ x 8″ card for direct recording is supplied. The card may be used at the same distance by setting it in the near type holder of a phoroptometer, after fitting it with a stiff plate, by attaching it directly to the arc of a perimeter, or clipping it into a holder which may be hung on the arc of a perimeter, furnished with an adjustable chin rest.

This instrument may be employed as a rotary or stationary campimeter. The rotary feature is used by Elliot for the study of paracentral scotomas extending from the blind spot. Another feature is a slot for the test-object carrier which permits the test object to be moved without the distraction produced by the carrier. Fixation may be maintained by the use of a mirror with a cross or the ordinary dot. The surface of the instrument and charts are neutral gray, which produces less retinal fatigue than white, and the after-images do not interfere with color perception. Recording may be done directly on the instrument, on 5″ x 8″ cards or on a chart which includes the 25° circle. Dr. Cutler has modified Peter's campimeter by drawing the arm out to 25 cm., and charting directly on millimeter paper.

For more accurate work the Bjerrum screen or one of its modifications is the most useful, and 75 cm. is a practical distance, although 60 cm., as used by Gradle,[5] one meter as suggested by Elliot[6] and Hudson,[7] two meters as originally practised by Bjerrum,[8] and 1.5 meters used here by Duane[9] may all be used.

A tangent curtain has been made by E. B. Meyrowitz which has several distinctive features. The screen is for use at 75 cm., as this distance has been found useful for plotting diplopia fields, as well as for studying the blind spot and central visual field. A wooden frame 6′ x 6′ is covered by

½-inch felt and over this is stretched a dark neutral gray cloth. Five degree circles, 1° small, lightly marked squares, and 4° large, heavily marked squares, are drawn in brown. In addition, radiating lines are drawn from the center, 15° apart. The heavy felt makes it easy to mark out scotomas with pins; the dark neutral gray cloth permits accurate outlining of scotomas for colors. The size of the screen permits its use up to 50°, which is as large a tangent screen

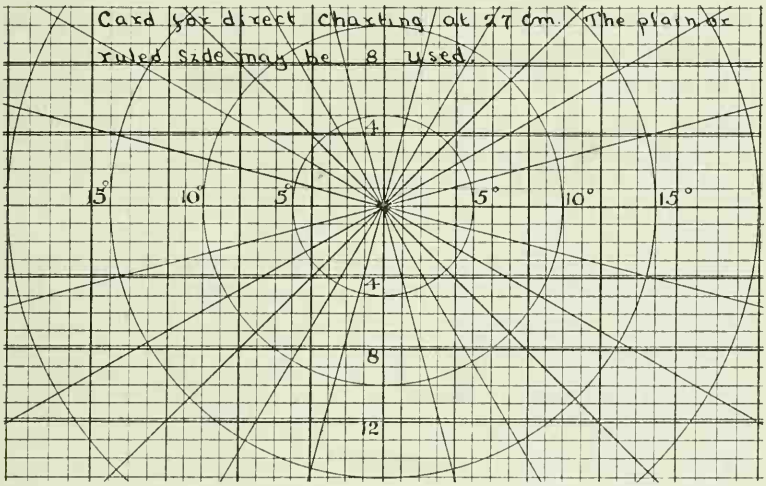

Fig. 5.—Small chart for direct charting at 27 cm. The small squares are every 1 degree and the larger squares are every 4 degrees.

as is useful for accurate work. Marking the cloth in brown makes the lines almost invisible and does not conflict with any test object that may be used. Charting directly from the surface of the screen is easy and time saving. The 1° and 4° markings were made after considering Cowan's[10] suggestion for a new perimetric chart. These markings make possible a rapid determination of the size of scotomas, for, as Cowan has shown, 4° correspond to 1.02 mm. on the retina, and, therefore, each degree corresponds to about

0.255 mm. Roughly speaking, on the retina 1° equals ¼ mm. and 4° equal 1 mm.

The Lloyd stereocampimeter is one of the best devices for studying the central visual field for scotomas, but is not as accurate for the examination of the blind spot.

Size and Location of the Blind Spot.—In estimating the size of the blind spot there are so many variable factors that one cannot deprecate too strongly the belief that it has but one invariable size or location. The drawn-in outlines in use on many charts would lead one to believe that normal variations are slight.

In searching for the blind spot it is only necessary to remember that it is usually found between 12.5° and 18.5° temporal to the point of fixation, and slightly below the horizontal, doing away with all outlined areas for the supposed "normal" blind spot.

In the present state of our knowledge each investigator should establish his own standard of normal for his method of examination and the conditions under which he works, in regard to illumination, size and type of test object, the rapidity and direction of motion of test object, and distance from the point of fixation.

For clinical tests, it is preferable to use a campimeter or tangent screen of neutral gray color for both motion and colors, illuminated by artificial daylight of constant intensity, fixing the distance from the point of fixation by a mouth-bit or other suitable adjustable method, using a white test object for motion, and Hering standard pigment papers for color perception. Peter's[11] suggestion of the use of minutes and degrees in regard to test objects is a good one. He suggests test objects of 30 minutes, one, two, and three degrees for each type of perimeter or tangent screen. It is advisable, because of the differences in visual reaction time of patients, to note the size of the blind spot when the test object is moved from the blind to the seeing area, and vice versa,

recording the mean of these findings as the size of the blind spot.

In determining the average normal blind spot, it may be useful to make the following measurements: 1. Nasal border from the point of fixation. 2. Temporal border from the point of fixation. 3. Height of blind spot above point of fixation. 4. Distance of blind spot below point of fixation. 5. Horizontal diameter. 6. Vertical diameter.

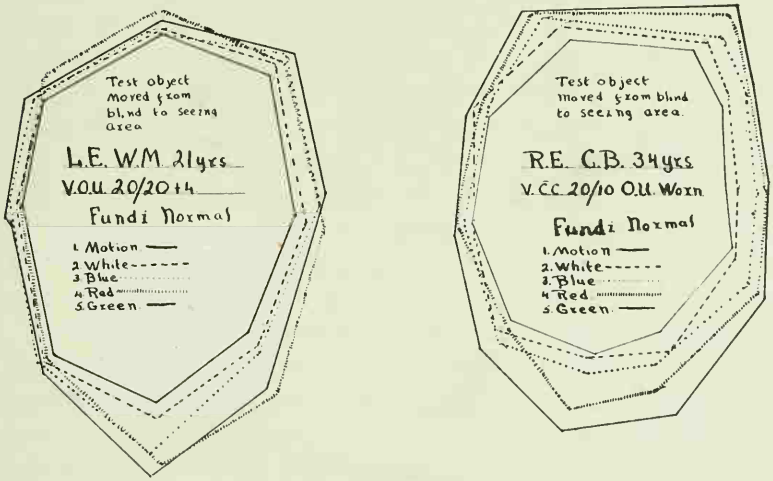

Fig. 6.—Blind spots of two normal subjects for motion, blue, white, red, and green. Light gray side of Duane tangent curtain. Macbeth daylight lamp at 1 meter, 5 mm. test object for motion and white, 10 mm. for colors. Note how closely some of the points coincide.

In most cases, for practical clinical work, it would seem necessary to record only the mean vertical and mean horizontal diameter, unless the enlargement of the blind spot toward the point of fixation is being studied. It will be found simple to mark the limits of the blind spot when the test object is moved from the blind spot to the seeing area in black, at eight points, then find the point of disappearance when the test object is moved from the seeing to the blind

area at the upper, lower, nasal, and temporal sides, marking the mean between the points and recording the measurements in millimeters. The following figures in millimeters recording the sizes of the blind spots in patients with normal vision and fundi and no myopia are useful for comparison:

Average of 28 blind spots taken with uncontrolled daylight illumination on a black screen at 1 meter with a 3 mm. white test object for motion; mean of the in and out findings:

Nasal border, 245 mm.; temporal border, 347 mm.; above horizontal, 55.5 mm.; below horizontal, 98 mm.; horizontal diameter, 102 mm.; vertical diameter, 153.5 mm.

The blind spots were plotted of ten patients with normal vision and fundi, in order that averages might be obtained for comparison. Artificial daylight illumination was obtained by the use of the Macbeth daylight lamp, and the intensity was 4.3 foot candles at the point of fixation. A 10 mm. blue test object was used and the size of the blind spot marked for the mean of the in and out motion on the white side of the Duane tangent curtain:

Vertical diameter, right eye, 104 mm.; left eye, 104.3 mm. Horizontal diameter, right eye, 81.7 mm.; left eye, 81.5 mm.

Eight patients with normal vision and fundi were studied under the same conditions except that the black side of the Duane tangent curtain and a ten millimeter red test object were used. The point when red was seen and when it disappeared was marked and the mean between these findings recorded in millimeters:

Vertical diameter, right eye, 108.1 mm.; left eye, 113.5 mm. Horizontal diameter, right eye, 86.9 mm.; left eye, 86.4 mm.

The following data should appear on the blind spot record:

1. Name of patient.
2. Number of patient.
3. Date.
4. Type of apparatus used.

5. Facial asymmetry (particularly vertical orbital).
6. Mental reaction time (quick or slow).
7. Distance from the point of fixation.
8. Method of signaling, voice or mechanical, for example, a light.
9. Size of test object.
10. Type of test object.
11. Vision, with correction.
12. Correction worn or not during test.
13. Whether test object was stationary, or moved, and whether findings are the mean of the in and out motion, or exactly what they are, example, blind spot to seeing area.
14. Lighting: *a.* Daylight, state time of day, condition of sky and exposure, or better, intensity in foot candles. *b.* Artificial, type and intensity in foot candles or preferably the brightness of the surface in millilamberts.
15. Apparent size of the nerve and any abnormalities.
16. Name of observer.

The size and location of the blind spot as given by different authors vary, and this is not to be wondered at if only on anatomic grounds. Salzmann[12] gives the measurements of the horizontal diameter of the inner opening of the optic nerve canal as varying between 1.26 and 1.6 mm., and says that at times the vertical diameter is slightly greater than the horizontal. Furthermore, there are great differences in the methods of examination, which, as we will try to show later, make variations in the size of the blind spot.

Some authors have tried to compare their findings on the tangent screen with the known anatomic size of the nerve head, and seem pleased when their findings agree exactly with the anatomic measurements. Inasmuch as we are not measuring pathologic material with a pair of calipers, but are conducting a functional test with many variable factors, is it reasonable to expect the figures to agree absolutely, particularly when we realize how great are the anatomic variations?

The following table gives the measurements of the blind spot as found by several authors, and, in addition, measurements of 79 blind spots of 40 normal patients, outlined by the author at 27 cm. with the assistance of E. L. Goar:

Average blind spots of 79 male and female patients in millimeters at 27 cm., 2 mm. black test object, and 75 watt, 110-volt nitrogen daylight lamp, 50 cm. from the screen at an angle of 45 degrees.

These averages were compiled with the thought that differences between the size of the blind spot in male and female patients and between the right and left eye might be marked. The differences are apparently so slight that they may be ignored in clinical examinations.

There have been three views in regard to the limits of the blind spot. First, that the entrance of the optic nerve over its entire surface is insensible to light; this was Mariotte's view. Second, that the point of entrance of the retinal artery and vein alone is blind; this view was championed by Pequot.[13] The third view was advanced by Griffin[14] who said that not only is the disc blind but also the area immediately surrounding it is relatively blind; he found that the diameter of the blind spot varies within limits inversely as the intensity of the stimulus.

According to Groenouw,[15] the area of absolute blindness is surrounded by a zone of relative blindness in which large stimuli are visible, but smaller ones are not. Most authors of to-day agree that there is a relative scotoma for white and colors, surrounding the absolute blind spot scotoma. Ramsay and Sutherland[16] state that there is a narrow zone of relative or transitional amblyopia for white surrounding the area of absolute blindness. Outside of this is the limit of the absolute scotoma for blue, then for yellow, then for red, and lastly for green. Van der Hoeve states that the absolute scotoma is surrounded by a relatively blind zone for white of $\frac{1}{8}°$ to $\frac{1}{4}°$ and this by a zone of relative color

TABLE 1.—BLIND SPOT—MEASUREMENTS FOR MOTION BY VARIOUS AUTHORS

Author's Name and Number of Cases	Distance of Eye From Point of Fixation	Nasal Border From Point of Fixation	Temporal Border From Point of Fixation	Horizontal Diameter of Blind Spot	Distance Above Horizontal	Distance Below Horizontal	Vertical Diameter	Center of Blind Spot From Point of Fixation
Gradle, H. S. 13 cases	60 cm.	14.13 cm. 13°15′35″	19.68 cm. 18° 9′35″	5.55 cm. 4°54′	3.223 cm. 2°85′	5.169 cm. 4°47′	8.393 cm. 7°45′	17.31 cm. 13°15′32″
Elliot, R. H. Several	1 meter			5° 48′			8° 15′	
Van der Hoeve 100 cases between 18 and 22 years				5° 43′			7° 26′	
Berens, C. 79 blind spots 40 normal cases	27 cm.	57.44 mm. 12° 0′ 36″	90.74 mm. 18° 34′ 34″	33.30 mm. 6° 33′ 58″	12.95 mm. 2° 38′ 54″	28.64 mm. 5° 50′ 27″	41.59 mm. 8° 29′ 21″	15° 20′ 41″

Number of Cases		Nasal Border	Temporal Border	Above Horizontal	Below Horizontal	Vertical Diameter	Horizontal Diameter
25	Male Right eye	58.76	92.12	14.44	26.52	41.04	33.36
24	Left eye	54.75	88.62	11.37	30.00	41.50	32.79
15	Female Right eye	60.40	93.80	14.46	26.86	40.66	33.32
15	Left eye	55.86	88.40	11.53	31.20	42.80	32.53
49	Male Blind spots in right and left eyes	56.75	90.37	12.90	18.26	41.27	33.04
30	Female Blind spots in right and left eyes	57.63	91.10	12.99	29.03	41.73	32.92
40	Average Blind spot in right eye male and female	59.58	92.96	14.45	26.69	40.85	33.34
39	Average Blind spot in left eye male and female	55.30	88.51	11.95	30.60	42.15	32.66
79	Average Blind spots right and left eyes male and female	57.44	90.74	12.95	28.64	41.59	33.30

blindness averaging ½°. Observations of Van der Hoeve and Ramsay and Sutherland are fairly well borne out by investigations on normal subjects, except that with accurate observers, when using a black screen, daylight illumination, and large colored test objects, the fields for colors, white, and motion all coincide so closely that it is difficult to say that they are not all observed at practically the same time. When a white or light gray screen is used the findings are variable, and it is frequently difficult to reproduce the blind spot scotoma for colored test objects without great variations in size. With a black or dark gray screen and constant artificial daylight illumination the subjects tested were quite accurate in reproducing findings.

The use of colored test objects for outlining the blind spot has given such varying results, particularly when illumination was not constant, that such tests are not used routinely for clinical diagnosis, but are frequently employed when there is suspicious enlargement. The rapid fatigue for colors and white, which occurs early in optic nerve involvement in the area immediately surrounding the blind spot, is a valuable early physical sign. In patients who show this rapid fatigue one usually finds a great difference between the limits of the blind spot with the motion of the test object in and out of the blind area. This is a valuable early sign of beginning optic nerve involvement and seems to have been neglected by the authors writing on the blind spot. The blind spot is most noticeably enlarged when the test object is moved from the blind to the seeing area. This may be due to a partial lack of sensitivity of the surrounding retina which, although sufficiently sensitive to carry an impression of an object seen, is not sufficiently sensitive to receive and transmit a fresh sensation.

Variable Factors in the Examination which may Change the Size of the Blind Spot.—The distance from the point of fixation is undoubtedly the most important factor and should

be carefully measured and held constant. A metal measuring rod or fish-line attached to the point of fixation makes a rapid means of determining the correct distance. The rod may be applied against the closed eyelid which, for practical purposes, may be considered the cornea. All apparatus should have means of easily varying the distance from the point of fixation, and, if possible, should hold the head steady. A Bausch and Lomb head rest attached to a perimeter table, or set into a stand, will do this. A stand designed to hold wooden tongue depressors was used as a mouth-bit, and a similar attachment employed for a time for the perimeter, but proved distasteful to patients in office practice.

Fixation, particularly in relation to accuracy and steadiness, is next in importance. It is a difficult task to hold steady fixation while attempting to see an object by indirect vision, for visual fixation and attention are closely allied. Practice in fixating and using indirect vision almost invariably tends to narrow the limits of the blind spot. It may, therefore, be easily demonstrated that the practice error is large, and should always be considered in analyzing results. Binocular fixation seems to give more uniform results than monocular fixation, and a simple way to obtain it is by the use of a card held between the eyes, with a place cut out for the nose. A small cylindric tube may be held over one eye and such a tube has been made to set into a trial-frame, for use at 27 cm. If a monochromatic red glass is held over one eye, and a blue or green test object employed, the blind spot or other scotomas may be accurately outlined while binocular fixation is maintained. A monochromatic red toric lens with a base curve of 9 fitted with a handle has been made by E. B. Meyrowitz. A mirror with a cross, as used on the Schweigger perimeter, is a valuable means of obtaining steady fixation. Intermediary fixation as employed by Gradle,[17] in which a small point is brought into position between the observer's eye and the fixation

point, helps to assure accurate fixation. Even with these devices the observer should watch the eye under examination; this may be done directly, and is facilitated in some instruments by making a small aperture at the point of fixation, as first suggested by Bardsley.[18]

The anatomic variations in the size of the nerve must be considered before making a diagnosis of a pathologically enlarged blind spot. A pseudo-neuritic type of nerve head is frequently smaller than one with a large physiologic cup.

The influence of fatigue on the size of the blind spot in subjects with normal eyes is considered slight by Ferree and Rand,[19] who state that the varying determinations of the limits of the blind spot when a stimulus of constant intensity is used are due to the practice error, rather than to retinal fatigue, for were it due to retinal fatigue, these authors would expect the size of the blind spot to increase upon prolonged fixation, which was not the case. Ovio,[20] on the other hand, believes that the retina readily becomes fatigued around the blind spot for colors more than for white. Certainly the fatigue factor has confused some of our observations, particularly for colors when a white or a light gray screen was used, although the practice error is undoubtedly more important.

If the patient is permitted to close his eyes, frequently this difficulty will be partly obviated. When pathologic enlargement of the blind spot is beginning, but still more when advanced, we frequently see rapid fatigue with enlargement of the blind spot during the test. As stated above, this is apparently valuable as an early sign of optic nerve involvement.

In outlining the blind spot for motion, illumination is an important practical factor only when markedly reduced. For clinical testing for colors, artificial daylight illumination is preferable, for we all know how blue appears as black with the ordinary yellow artificial lamp. A lamp has been de-

signed by Mr. Norman Macbeth, of the Artificial Daylighting Company, Inc., to be used in connection with the tangent screen and hand campimeter.

This is a floor-stand lamp, adjustable in height from 36 inches to 60 inches, and affording various distributions of light from vertically downward for the illumination of horizontal surfaces to light directed horizontally from the lamp for lighting vertical surfaces. The cone of light is not concentrated but is over a wide angle, practically 160 degrees. The adjustment for varying the direction of light is through the rotating of the porcelain enameled parabolic-shaped reflector, enclosing an ordinary clear glass 150-watt tungsten filament lamp (or Mazda C lamp) of the voltage adapted to the circuit on which it is used. The particular feature of this lamp, aside from its construction, is that the light has all the visual qualities of natural daylight. The lamp herein described was especially made for use with the tangent screen and hand campimeter, and was fitted with a filter to correct the light to an equivalent of daylight from a light overcast sky.

In using the daylight lamp with the neutral gray modified Bjerrum screen, it should be adjusted as in Fig. 8, and placed above and in back of the observer's head, 1 meter from the screen, and 35 cm. above the point of fixation. The intensity of light at the point of fixation with this arrangement is 4.3 foot candles, and this variation in intensity did not exceed 10 per cent. within the 25° zone. At 50° the intensity is approximately 50 per cent. of the maximum at the point of fixation. These values, as they are of the incident light flux, would be the same for any screen. The brightness of this particular screen within the zone of 50 per cent. varied from a maximum of 0.5 millilambert to 0.4 mL.*

* The millilambert is the unit of brightness approximately equivalent to 1 foot candle on a surface having a reflection factor of 100 per cent. It is exactly equal to the brightness of a perfectly diffusing surface emitting 0.929 lumen per square foot.

In using the lamp with the modified Peter campimeter, the filament should be 24 inches from the surface of the instrument. At this distance, when employing the neutral gray chart which is supplied, the brightness is 4.2 mL. This light seems to give better illumination for determining color values than that supplied with the Lloyd stereocampimeter, and when it is placed 18 inches above and 4 inches to the left of the center of the recording plate, the intensity at the fixation point is 15.7 ft. c. The brightness on the white recording chart is 8.8 mL.

The visual reaction time of the individual is an extremely important factor in determining physiologic variations in the blind spot, and for this reason measuring the blind spot from the seeing to the blind area, and vice versa, has been suggested. By this means some idea of the lag in perception may be obtained, although it is probable that some of the error is due to unsteady fixation.

The test objects must be sufficiently large, for the visual acuity diminishes rapidly as it becomes eccentric. Sulzer[21] estimates that at 10°13′ the vision is $\frac{1}{19}$ of the normal, while at 16°17′ the vision is only $\frac{1}{45}$ of normal. If we expect our results to be comparable, we should follow Peter's suggestion in regard to the size of the test objects. The former should be round, and if pigment colors are used, it is well to use the Hering standard series. Some observers use a light and examine for the area deficient in light sense. This method, although not as delicate as other tests, is undoubtedly of value if the intensity of the stimulus can be controlled, for the diameter of the blind spot varies within limits inversely as the intensity of the stimulus.

That the brightness of the preëxposure and the surrounding field is an important factor in perimetry, particularly when colored test objects are used, has been shown by Ferree and Rand.[22] Quoting from their monograph: "The brightness of the surface to which the eye is preëxposed may change

the apparent limits of the visual field in certain meridians as much as 17° to 20°. A pre-exposure lighter than the color gives a dark, and one darker than the color a light, after-image. These after-images change profoundly the saturation of the color sensation, also its hue. A background or surrounding field, lighter or darker than the color, produces a similar effect on the limits, but not so great. In this case the disturbing chromatic effect is due to physiologic induction or contrast. The variable effect of brightness of pre-exposure and of surrounding field can be eliminated only by making both a gray of the same brightness as the stimulus color. Here again a precise control of the intensity of the illumination for all points of the perimeter arm becomes important. That is, the shade of gray which is needed to match the color in brightness changes with change of illumination; therefore, the selection of a gray which will match the color in brightness for all points of work presupposes constancy and uniformity of illumination. A further advantage is gained by making the background of the same brightness as the color. That is, when color and background are of the same brightness, the stimulus disappears completely when the limit of sensitivity to that color is reached, instead of turning into a gray concerning the colorlessness of which the patient is apt to be in doubt. This gives the effect of the disappearance type of photometer, and, like it, adds greatly to the ease and certainty of making the judgment."

In Ferree and Rand's new perimeter the control of brightness of preëxposure and surrounding field is provided for by using cards covered on one side by grays equaling the brightness of each of the four colors, that is the red, yellow, green, and blue of the Hering standard series of pigment papers. A disc of the appropriate color subtending a visual angle of one degree is pasted at the center of each of these cards. If the stationary method of giving the stimulation is used, the color is covered by a card, on one side of which

is a gray of the brightness of the color. If the moving stimulus method is used, the surrounding field also serves as the preëxposure. The perimeter arm and body are painted gray, of a shade which is approximately mid-gray to the blue and yellow, the darkest and lightest of the stimuli employed. For practical clinical use it would seem as though a campimeter or tangent screen, neutral gray in color, illuminated by artificial daylight of constant intensity, and the use of standard colors are all that is required to eliminate the serious errors due to preëxposure and the surrounding field.

The stationary stimulus method will not be considered, as it requires too much time for practical clinical use.

The movable stimulus method: Many methods have been devised for moving the test object mechanically, and probably the most ingenious is the one employed by Gradle, which consists of a magnet at the back of the screen by means of which magnetic spheres are moved on the front. Errors due to the patient's distraction by the test-object carrier or the observer's hand are more imaginary than real, particularly if the hand and carrier are covered by a material of the same color and brightness as the background, and the test-object carrier lies as much as possible in the blind area. For example, when studying the upper border of a scotoma, have the carrier emerge from the lower border of the blind area. It is important that the test object be moved at a uniform rate but slow, because, particularly in patients with a slow reaction time, the limits of the in and out motion of the test object from the scotoma will vary markedly if the test object is moved rapidly.

Visual Acuity and the Wearing of Correcting Lenses.—If the test object subtends a sufficiently wide visual angle, and the vision is nearly normal, the wearing of correcting lenses makes no appreciable difference, inasmuch as we usually test for motion and not for form.

However, as practically we are testing the central fields of

vision, and, therefore, get little distortion from eccentric vision through the lenses, in the following instances it is advisable to have patients wear their correction: Whenever visual acuity is improved by correction, to overcome fatigue, as in fixating a near test object in high hypermetropia; also in presbyopic patients; when using an instrument with a short radius which brings the point of fixation and the test objects close to or within the near point of accommodation.

CONCLUSIONS

1. There is no one method or apparatus for examining the blind spot equally useful in all cases, and each investigator should establish his own standard of normal for his method of examination. If but one apparatus is selected, some form of portable campimeter with a neutral gray chart for direct recording is probably the most universally useful.

2. Any intelligent person can outline the blind spot with sufficient accuracy, if the practice error is minimized. There are, however, so many variable factors to be considered that if the findings are to be properly interpreted special training is required.

REFERENCES

1. Mariotte: A New Discovery Touching Vision, Philosophical Transactions, 1668, v. iii, pp. 668–669.
2. Berens, C.: An Accommodation Rule with New Features, Amer. Jour. Ophth., 1923, v. vi, pp. 26–28.
3. Peter, L. C.: A New Hand Campimeter, Ophth. Rec., 1915, p. 331.
4. Cohn, H.: Messungen der Prominenz der Augen mittelst eines neues Instrumentes des Exophthalmometers, Klin. M. f. Augenh., 1867, v. v, pp. 339–351; see p. 347.
5. Gradle, H. S.: The Blind Spot, second communication, Ann. of Ophth., Oct., 1916.
6. Elliot, R. H.: New Form of Scotometer and a Sign Charted by its Use, Trans. Ophthal. Soc. U. K., 1918, p. 185.
7. Hudson, A. C.: Large Perimeter with Eccentric System of Registration, Ophthal. Soc. U. K., v. xxxviii, p. 213.
8. Bjerrum: Nordisk Ophthalmologisk Tideskrift, 1890, v. ii, p. 141.
9. Duane, A.: Tangent Curtain, Archives of Ophth., 1914, v. xliii, No. 6.
10. Cowan, A.: A Suggestion for a New Perimetric Chart, Amer. Jour. Ophth., 1920, v. iii, pp. 49–50.
11. Peter, L. C.: Uniformity in the Essentials of Perimetry, Amer. Jour. Ophth., 1920, v. iii, pp. 584–587.

12. Salzmann, M.: Anatomy of Human Eyeball, Trans. by E. V. L. Brown, Chicago, 1912, p. 96.
13. Pequot: Philosophical Transactions, 1668, v. iii, p. 669–671.
14. Griffin: London Medical Gazette, New Series, 1838, v. ii, pp. 223–32. quoted by Ferree and Rand, Amer. Jour. Phys., v. xxix, p. 400.
15. Groenouw: Arch. f. Augenh., 1893, xxvi, pp. 125 and 126.
16. Ramsay and Sutherland: Spindle-shaped Enlargement of the Blind Spot Associated with Congestion of the Optic Disc, Ophth. Rev., 1906, v, xxv, p. 1.
17. Gradle, H. S.: Ann. of Ophth., 1916, v. xxv, p. 740.
18. Bardsley: A New Scotometer, The Ophthalmoscope, v. vi, p. 867.
19. Ferree, C. E., and Rand, G.: The Spatial Values of the Visual Field Immediately Surrounding the Blind Spot, Amer. Jour. Phys., 1912, v. xxix, p. 402.
20. Ovio, C.: Osservazione sulla regione cieca di Mariotte, Ann. di Ottal., 1907, v. xxxvi, p. 107.
21. Sulzer: Enc. Fr. d'Opht., 1904, v. iii, p. 760.
22. Ferree, C. E., and Rand, G.: Trans. Am. Ophth. Soc., 1920.

THE EFFECT OF GENERAL TUBERCULOSIS ON THE EYE, WITH A REPORT OF FREQUENTLY OVERLOOKED SYMPTOMS*

H. H. STARK, M.D.
El Paso, Texas

Since the advancement in medicine following the discoveries in bacteriology with the complement-fixation test and other pathologic procedures, there seems to be a loss of the clinical sense, causing us to depend too much on laboratory reports in making a diagnosis.

In contrast to this is the work of those identified with the early history of medicine, who made observations based on clinical facts which remain standard to the present day.

An eminent English ophthalmologist once remarked to me that there had been no modern discovery in ophthalmology which had not previously been forecast by Mackenzie. This statement may not be correct; however, in consulting Mackenzie's works, one is impressed with the remarkable descriptions of pathologic and clinical eye conditions made almost one hundred years ago. These men developed this

* Candidate's thesis accepted for membership by the Committee on Theses.

keen clinical sense, no doubt, because of the fact that during their entire medical lives they were not far removed from contact with general medicine, and, at all times, had the clinical condition of the patient, both general and special, constantly under observation.

Bearing these facts in mind, I present this report on clinical observations made during my study of active and inactive tuberculosis, hoping to add to our knowledge of the effect of this disease on the eye, as well as its effect on other parts of the body.

In the eye may be observed not only the complete cycle of the development and healing of the infection, but the effect of the toxemia on the tissues, and the functional changes accompanying it.

I beg you to remember that these are clinical observations, many of which cannot be proved by diagnostic methods now known, but which may be demonstrated in the future.

From those who have made a study of general tuberculosis, we learn that the majority of persons are infected with tubercle bacilli, which infection usually runs its course and leaves a relative immunity for a variable period.

The infection may take place through the gastro-intestinal or the respiratory tract, with the predominance of evidence pointing to the latter as the route of invasion. The glandular system is principally involved, but there may, also, be pulmonary lesions.

The healing is the result of the development of tissue resistance to the toxin and the production of a localized exudate around the lesion, which subsequently organizes and shrinks, thus limiting the activity of the bacilli, with a possible eventual destruction of the organism. However, some of the foci may remain apparently inactive for many years, with a gradual attenuation of the bacilli, causing no impairment in the individual's health. This is proved by the percentage of positive dermal tests made with old tuberculin in the adult,

indicating that there still exist antibodies which are stimulated by the toxin from the tuberculous foci.

Neither age nor environment excludes the possibility of this disease, as is illustrated by the following cases which occurred in my practice: a five months' old child, of a tuberculous father, developed typical pulmonary tuberculosis, demonstrated by radiograph; a ten months' old child with eczematous keratoconjunctivitis, with a positive reaction to tuberculin, the condition aggravated by intestinal disturbance, especially by overindulgence in sugar; a low-grade uveitis in a seventy-year-old patient, who gave positive reactions to subcutaneous injections of tuberculin.

That open air and hygienic mode of living do not always prevent localized tuberculosis is illustrated by the case of a trapper who spent most of his life in the mountains of the Southwest yet developed tuberculous choroiditis.

The study of tuberculosis should be divided into three periods, owing to the fact that while some symptoms may be common to all, certain symptoms are more often found in stated periods of life: first, infancy to puberty; second, puberty to adult life; third, adult life; studying each in the active and passive stages of the disease.

First Period.—The most pronounced cases in childhood are those of eczematous keratoconjunctivitis, with the corneo-limbus ulcer, photophobia, eczema, nasal discharge, and enlarged glands, no doubt due to a tuberculous toxemia. I am aware that tuberculosis is not universally accepted as the cause of this condition, but the preponderance of clinical and therapeutic evidence seems to favor this theory. However, there may be contributing factors, such as digestive disturbance, improper diet, or the absorption of toxic products from infected tonsils and nasal sinuses. These seem to interfere with the natural process of healing, either by flooding the system with toxic products or by interfering with the action of the antibodies and antigen, possibly through

the absorption of the complement. When the secondary toxic material is eliminated by removing the source of its supply, the rapidity of cure is sometimes startling. Another contributing factor, in my opinion, is a high degree of hypermetropia, which refractive error is sufficient to produce ocular symptoms in children who otherwise might escape.

I have had under observation during the last few years 20 patients with severe eczematous keratitis,—19 Mexicans and one American,—on whom I have tested the efficiency of tuberculin. Previous to treatment some of the patients had repeated attacks. The diet and hygienic surroundings of all were bad. Without correcting the diet, intestinal toxemia, or using surgical interference on the tonsils or nasal sinuses, treatment was commenced with small subcutaneous doses of old tuberculin. Under this treatment a number showed focal reaction in the eye with doses of tuberculin as low as 1/50,000 milligram, and under continued treatment for a few months the eyes became clear in all except one case, and have remained apparently well. An American child made a slow recovery over a period of three months. Finally the acute symptoms subsided, but recurred three years later following an attack of tonsillitis. After tonsillectomy, an improvement of the eye condition could be noted within twenty-four hours and continued uninterruptedly.

A lower grade of tuberculous toxemia is found in those children who have no gross lesion of the eye, but who do have a photophobia of more or less marked degree, together with headaches, usually in the afternoon. They are substandard in weight, highly nervous, and frequently with irritable tempers. The correction of any refractive error does not relieve the symptoms, as the same condition may occur with an emmetropic eye.

The fundus discloses a congested retina, with silvery reflexes playing over it and along the vessels. The disc is

frequently congested at the edge. The patient has an irregular temperature, many times found only on repeated examinations. Both temperature and pulse may increase with exercise. The dermal test is usually positive. Some cases improve following tonsillectomy, change of diet, and correcting the intestinal absorption, while with others the symptoms continue over a term of years, even throughout the second and third periods of life.

In childhood there undoubtedly occurs involvement of the retina and choroid, which goes undiscovered because of the inability of the child to call attention to the condition. Due to the natural tendency of the disease, these heal spontaneously, to be discovered later as pigmented or atrophic areas.

Second Period.—There is no fixed age at which this period begins and none at which the complete development of immunity takes place, as it depends altogether on when the infection occurs, and on the general health of the individual.

Should the patient be constantly exposed to infection, the activity is usually longer and may result fatally. When the living standard is high and no disease exists with which one may come in contact, the period is shorter. The cases where the infection results in a relative immunity and the life of the individual is carried on without too much physical or mental strain may remain inactive. However, there may be redevelopment of the original lesion, or distribution of the infection through the circulatory system at any time the resistance is lowered.

There is no sharp line of demarcation drawn between the disease of childhood and that of adult life, but we may safely say that the period between late youth and the first few years of adult life is an extremely dangerous one. It is at this time, if the individual has not developed tissue resistance, that the redevelopment of the disease or re-infection is most disastrous.

It has been my experience to find, frequently in early adult life, cases of monocular mydriasis, said by Fuchs[1] to be due to involvement of the sympathetic nervous system. One case under my observation developed monocular mydriasis at the age of twenty-four, as the only symptom, and died five years later of pulmonary tuberculosis.

There are often found, during this period of life, the same symptoms as in the second stage of the disease in childhood, which, in the adult is usually ascribed to eyestrain. The importance of recognizing this symptom is illustrated in the following case: A man, aged twenty-four years, two years ago developed his first eye symptoms with headache, nervousness, and "spots before the eyes." He consulted an oculist and was told that his eyes were normal. Six months later a diagnosis of pulmonary tuberculosis was made.

Under treatment his physical condition improved, and with this improvement the eye manifestations subsided. He soon became an arrested case, only to break down again with a recurrence of the eye symptoms, which he now recognizes as the first sign of his physical condition.

In the second period also occurs involvement of the deeper tissues of the eye, there being especial affinity for the cornea and sclera, the latter tissues frequently showing involvement when no activity can be found in other parts of the body.

Third Period.—In adult life the cases with marked active pulmonary involvement are disposed to have symptoms similar to those found in the second stage during childhood; the headache is frequently more severe and often corresponds to the time of temperature rise. They complain of photophobia and aching eyes, aggravated by close work. The symptoms may exist without a discoverable error of refraction, but are usually worse with refractive errors, whether myopic or hypermetropic.

Examination shows the retina markedly congested and occasionally the disc. The vessels have a light reflex along them, and those of the disc, at times, are partially covered with a thin exudate. The extrinsic muscles show a variable action from day to day.

The headaches may be so severe as to lead one to suspect meningitis, and usually are not relieved by putting the eyes at rest with atropin.

These cases are best treated by correcting the refractive error, limiting the amount of close work, and protecting the eyes from light, but many times no relief comes until the physical condition is improved.

The active stage seldom has involvement of the deeper tissues of the eye, due, no doubt, to the protecting influence against the infection stimulated by the systemic condition.

The second group of cases in the adult is made up of those who have overcome their primary infection to such an extent that they are usually classified as healthy individuals.

There may remain, however, a few latent foci, either in the lungs or glands, which are of so trifling a nature that they are not producing enough toxin to stimulate the development of anti-bodies. The bacilli have become attenuated and are less virulent than those producing the initial lesion, so that when an infection from one of these foci enters the blood stream, there is little resistance given to its invasion of other parts.

Consequently it is patients of this character who have involvement of the uveal tract, shown as localized choroiditis, tubercles of the iris, and other intra-ocular involvements. Contributing factors, the same as those found in childhood, must also be considered, and especial consideration should be given the teeth and gall-bladder.

A grade lower are the cases that report symptoms resembling those in the second stage of childhood, and in addition, they are highly nervous, have migraine, and present

the picture familiar to us as hysteria or neurasthenia. They are frequently underweight and have been most of their lives.

In some of these cases we find a silvery reflex over the retinal vessels. Old corneal nebula may occasionally be found, indicating eczematous keratoconjunctivitis in childhood.

Correcting the refractive error may improve the condition to a slight degree, but many cases are examined year after year, going from one ophthalmologist to another, without relief.

It is not infrequently that from these symptoms I have been led to suspect pulmonary tuberculosis, which was later confirmed by physical examination. On a close study of certain patients I have been able to determine increased activity in the lungs by the eye symptoms.

Diagnosis.—We are assisted in making a diagnosis in active cases by a physical examination of the chest; however, the tendency of the average physician is to report negative those cases having no physical findings similar to those of active tuberculosis. In other words, where no râles are found in the chest, nor any rise of temperature above normal occurs, the average physician considers there is no active tuberculosis. Therefore, in making a diagnosis in the occult or latent cases of tuberculosis, we are compelled to resort to other methods.

The history of the individual's life in childhood should be secured, as occasionally information may be obtained which throws a strong light on the present condition.

In all cases the temperature should be taken at least four times a day for a number of days. In the adult it is frequently found to be subnormal in the mornings, occasionally as low as 95°, sometimes not even reaching normal during the entire twenty-four hours; at other times slightly above normal in the afternoon. A variation of two degrees in the

reading is a strong indication of tuberculosis. However, the disease may be present without this variation in temperature. In the adult there is usually a subnormal blood-pressure.

The use of tuberculin in one or all of these methods is without doubt the most positive way of making a diagnosis; the dermal or intradermal tests, the subcutaneous, or the therapeutic. In the use of this agent, however, we are confronted by Kolmer's[2] statement that no true tuberculin has as yet been developed. I have felt for some time that the tuberculins on the market were far from being standard, owing to the fact that the culture used in their manufacture is often from bacilli of attenuated virulency, due to repeated cultures of the same strain, and that the virulency might have some effect on the strength of the tuberculin. In addition to this fact, old tuberculin, the most commonly used, depends for its standardization only upon the length of time it has grown in contact with certain media.

Having had these views for a number of years, I was gratified with the recent report of Cunningham and Radcliffe.[3] Their test of 1200 children with both human and bovine tuberculin applied by the von Pirquet method and the intracutaneous method of Mantoux showed that only one out of six different products employed were suitable for use in determining the presence of tuberculous infection. Therefore, we can readily see that any of the three tests based on the use of tuberculin may be negative even in positive cases, provided the tuberculin is not of the proper strength.

The action of the tuberculin in any of the three methods depends on the presence of an allergy stimulated by the toxin. Where the antibodies are not present, we may have a negative reaction until such time as they are stimulated. Where they are present and the reaction does not occur, we should look for the cause of interference.

According to von Pirquet,[4] the dermal test may be negative:

(1) In the first stage of infection, that being the period when antibodies are not formed in sufficient number. (2) In the final stage of tuberculosis, especially in miliary tuberculosis. (3) In cachexia. (4) During measles. (5) During continued treatment with tuberculin a long time after the onset of tuberculosis, as with increased age the action becomes less sensitive.

Undoubtedly this could also be an explanation for the absence of both the general and focal reactions in certain instances. It explains the difference in the size of the dose necessary in childhood and in the adult, as with increased age the tissue resistance to toxin has developed to a great extent, and in the apparently healthy individual the foci are so few in number that frequently large and repeated doses are necessary before reaction occurs.

The therapeutic test depends on whether we are dealing with a specific proteid or not. On this point I am firmly convinced, as otherwise we would not have the three reactions occurring with a two minims injection, representing 1/50,000 milligram, or less, of tuberculin, as the amount of proteid in a dose of this size is infinitesimal.

On the other hand, it has been shown conclusively that enormous doses of tuberculin may be given to a non-tuberculous individual without reaction.

The therapeutic results, especially in children, are at times remarkable. With the use of very small doses, in a few months the eye condition improves. There is a general increase in weight, disappearance of enlarged glands, and marked improvement in the physical condition. In adult cases the results are slower, and the treatment should be continued for a longer period.

It is necessary to determine the exact dose for each individual, the best dose being undoubtedly the one producing

a very slight reaction. I have seen sclerotizing keratitis gradually develop in a patient under treatment with tuberculin, which immediately started to improve following a dose producing a slight general, local, and focal reaction.

The length of time this treatment should be continued varies with each case. I have under treatment with therapeutic doses of tuberculin a highly intelligent nurse who had 15 intra-ocular hemorrhages during the six years before reporting to me. The vitreous opacities were so dense for two years that she was not able to count fingers at a few feet. Owing to an obscure chest condition, the dose was very gradually increased, at no time reaching over three-tenths of a milligram. The vitreous opacities have now almost entirely disappeared and she has practically normal vision with her correction, the improvement being more marked each time after a dose producing a slight reaction.

The nervous type of occult tuberculosis under treatment with tuberculin usually shows a marked improvement in the general condition and the eye symptoms. The weight increases, they sleep better, and many of the nervous symptoms disappear. However, it is seldom that they regain normal nerve tone, because the toxemia has undoubtedly produced a certain amount of degenerative change in the nerve system.

Conclusions.—Tuberculous infection in our race is almost universal and may be present at any age or under any condition of life.

Special symptoms are found most often at certain periods of life.

The disease may manifest itself as localized infection or functional changes.

Localized infection is not so often found in the individual having general activity as in the latent cases, due no doubt to the protecting influences of the antibodies in those having activity.

At times the disease seems to be influenced by toxic products from other infection, indicated by the rapidity of improvement following their removal.

Therapeutic doses of tuberculin, when properly used, seem to be the most efficacious remedy.

What we learn in a study of gross lesions and functional changes in the eye may be applied to both localized, general, and functional changes wherever located in the body.

REFERENCES

1. Fuchs: Text Book of Ophthalmology; Fuchs: Duane's Translation, Fourth Edition, p. 433.
2. Kolmer, J. A.: Infection, Immunity and Special Therapy, Second Edition, W. B. Saunders, Philadelphia.
3. Cunningham, A. R., and Radcliffe, A. R.: Tubercular Infection in Childhood, Boston Med. and Surg. Jour., November 16, 1922, p. 691.
4. von Pirquet, C. E.: Arch. Int. Med., February and March, 1911, pp. 259–440.

SOME OF THE ESSENTIALS IN LEGISLATION FOR THE RELIEF OF THE BLIND*

F. E. WOODRUFF, M.D.
St. Louis, Mo.

The condition of the indigent blind and the provisions made for their relief in the various States have been forcibly brought to my attention during the past three years.

A constitutional amendment providing pensions for the indigent blind of Missouri was passed by popular vote in the general election of November, 1920. The details connected with this amendment were drawn up and passed by the State Legislature and approved by the Governor in March, 1921. At that time and subsequently I served as Chairman of the Consulting Staff of the Missouri Commission for the

* Candidate's thesis accepted for membership by the Committee on Theses.

Blind and consequently was brought in contact with a great many applicants for pensions. I was also in close touch with the Missouri Commission for the Blind.

Among the applicants for pensions we found the deserving and the undeserving; the blind and the near blind; the needy and the impostor. The pension law was intended solely for the relief of the indigent blind, but we found that there were many among all the above mentioned classes who were ready to accept a pension who had no legal right to such relief. The burden on the tax-payer has proved much greater than was anticipated.

The Constitutional Amendment provided that the pensions should be paid out of an annual levy of one-half to three cents on the one hundred dollars valuation of the taxable property in the State two years ago. The Legislature, believing that a rate of two cents on the hundred would provide adequate funds, specified this rate. It was within the power of this body to decide what the tax rate should be. Should there be any surplus it was to go to the school fund of the State. At this rate of two cents the average yearly income of 1921 and 1922 was estimated at about $930,000; at the highest legal rate (three cents) about $1,400,000 would have been available.

An estimate based on the 1920 Federal census led us to believe that we would have about 2,500 on our pension list, but the number has steadily increased until now there are about 6,000 enrolled. With this number it is impossible to pay the annual pension of $300 each out of a tax collection of $930,000. Even with a rate of three cents a hundred, $1,800,000 would be required to pay $300 yearly to the 6,000 persons now on the roll.

It was also found that many of the blind who had received training or education were unable or unwilling to do their utmost toward self-support. Some who were able and willing to work found that the returns from their labor were dissi-

pated in trying to dispose of their product. Some were too poor to purchase raw material. Some, through pride, tried to conceal their real condition. It was also discovered that there were many on the pension roll who were not entitled to relief; some who should not be classed as indigent; some had misrepresented their vision or had been placed on the list through influence or pressure from various sources. The more we learned the more complicated the problem appeared.

A study of the measures adopted by the various States for the care of the blind forced upon us the conclusion that no one line of action was suitable for all members of this unfortunate class. Each case appeared to be a law unto itself and demanded individual thought and investigation for its proper relief.

Measures adopted in different States are greatly at variance regarding the necessity for relief for the blind in determining who shall be considered blind, the degree of blindness entitling one to a pension, the amount of the pension, and the method of granting it. Some seem to consider that money pension or gratuity is the entire duty of the State, leaving further relief measures to private organizations. In many States there is no appreciation of the necessity of providing for the care of the youths trained in some trade or profession in the State Schools during the period after graduation and before they can establish themselves and thus become self-supporting, or partly so. The consequence has been that, in large measure, those who at school learned a trade or occupation have been unable to pursue it as a means of livelihood and in many cases have ceased to follow the work for which they were trained and have finally joined the class of those who idly sit with outstretched hands.

The following is a list of 127 graduates of the Missouri School for the Blind and their occupations:

	Graduates Boys	Graduates Girls	Total
	55	72	127
Married and housekeeper	..	13	
Housekeeper	..	2	
Assistant housekeeper	..	11	
Music teacher	3	6	
Literary teacher	2	5	
Voice teacher	1	..	
Broom-maker	6	..	
Piano-tuner	9	..	
Broom salesmen	2	..	
Osteopaths	2	..	
Musicians	5	1	
Typists	..	3	
Salesmen	4	..	
Poultry raiser	..	1	
Packing clerk	..	1	
Lawyer	2	..	
Carpet weaver	1	..	
Preacher	1	..	
Storekeeper	1	..	
Printer	..	1	
Factory worker	..	1	
Factory foreman	1	..	
Truckman	1	..	
Studying osteopathy	5	..	
Studying for M.A. Degree at Washington University	..	1	
Died	4	12	
Occupation unknown	5	14	

This paper is not intended as an argument for or against pensions. It is simply a plea for such measures of relief as may enable these unfortunates to regain the ability to provide for their own needs. What is sorely needed is an understanding by the people that the blind are in need of something besides money to enable them to keep their self-respect and to make them useful members of society. There is nothing, to my mind, which so soon makes a man dependent as to have the doors of all occupation closed to him. Instead of teaching a blind man how to work, letting him do what he can and helping him to dispose of his product, we hand him out a gratuity in the form of a pension.

Schools for the blind have been organized in most of the States under more or less favorable conditions, and in those States where schools are not maintained, provision is made for the education of the blind by arrangements with neigh-

boring States. The character of the schools and the amount of education and training vary in different States. It necessarily varies with the individual, depending upon his mental ability, his former education and teaching, and his age. All people are not fitted to receive the same kind of training and it requires great discrimination and judgment in order to determine the line of work and instruction to be selected for any individual. To attempt to train or educate a person upward of fifty years of age is an almost hopeless task. They are never as susceptible to education as those who are trained and educated at an earlier age.

In all but two or three States where pensions or relief laws are in effect the agitation for pensions was started by the blind themselves. Relief for the blind has been called "class" legislation, but whether it is class legislation or not, the fact remains that the blind are and always will be with us. Those who are now in the possession of their faculties should help to bear the burden of those who cannot care for themselves, whether they be blind or mentally or physically incapacitated. The measures which have been proposed have been primarily for the relief of the indigent blind but in certain States compulsory education of all the blind up to a certain age is required.

According to the census figures of 1920, we expected to find in the State of Missouri about 2,500 blind, including all ages. Instead of 2,500 blind we have now about 6,000 on our pension roll over twenty-one years of age with vision less than 20–450 who are classed as indigent. (No one seems to understand how the Legislature arrived at 20–450 as a standard.) This number takes no account of those under twenty-one years nor of those who are able to care for themselves or who are cared for. The conditions under which pensions are granted in Missouri are: first, that the individual must be twenty-one years of age; second, that vision in either eye shall not be more than 20–450 without or with

glasses; third, that he must have been a resident of Missouri for ten years or must have been a bona fide resident of the State at the time of losing his sight; fourth, that he must have an income of less than $780 a year. Those publicly soliciting alms and those confined in insane asylums at the expense of the State, county, or municipality or under conviction for any criminal offense cannot share in the benefits of the pension. Such is the condition at present in Missouri which the workers for the blind are trying to improve through amendments to the present law or the passage of an entirely new law.

The administration of the funds and the examination of the applicants were left to the Missouri Commission for the Blind, which is composed of five members appointed by the Governor. This Commission has authority to investigate the economic status of each applicant but no funds are provided for this purpose. The wording of the provision regarding the amount of income was so ambiguous that many applicants were placed on the pension roll who should not have been so included. This the Commission was powerless to prevent.

The ocular examination was first made by the consulting staff of the Missouri Commission for the Blind composed of all oculists in the State who were members of either the American Ophthalmological Society, the American Academy of Ophthalmology and Oto-Laryngology, or who had certificates from the American Board for Ophthalmic Examinations or who were members of the American College of Surgeons practising ophthalmology. Later, owing to the fact that there were some districts in the State in which there were no oculists, pressure was brought to bear upon the Legislature and the Commission was instructed to have examinations made by general physicians appointed by the Probate Court. Because of this instruction quite a large number of cases have been examined by general practitioners. In the follow-

ing table only those cases examined by oculists have been considered in arriving at the percentage of blindness due to the various diseases.

Dr. H. D. Lamb, my associate, has made a careful study of cases examined by oculists and summarized his findings. This gives us a fairly accurate summary of the blindness in this State. I shall here include a table compiled by Dr. Lamb including the first 4,000. A later report will give the complete analysis of the entire list of 6,000.

TABLE 1

Causes of Blindness	Eyes Examined by Oculist Number	Eyes Examined by General Physician Number	Cause of Blindness Per Cent.
Trachoma	1,406	140	19.7
Cataract	1,131	190	15.9
Optic atrophy	976	36	13.7
Corneal ulceration	785	96	11.0
Glaucoma	741	70	10.4
Uveitis	462	21	6.5
Simple trauma	330	21	4.6
Trauma with sympathetic ophthalmia	132	2	1.8
Chorioretinitis	204	..	2.8
Ophthalmia neonatorum	163	11	2.3
Pigment degeneration of retina	119	6	1.7
Progressive myopia	78	2	1.1
Optic neuritis	82	14	1.2
Congenital malformations	59	..	0.8
Congenital cataract	43	2	0.6
Retinal detachment	30	1	0.4
Acid, lime and lye burns	30	2	0.4
Parenchymatous keratitis	14	..	0.2
Miscellaneous burns	11	..	0.2
Keratoconus	15	2	0.2
Pterygium	9	2	0.1
Essential shrinkage conjunctiva	8	..	0.1
Amblyopia ex anopsia	8	..	0.1
Hemorrhagic retinitis	7	2	0.1
Albino	6	..	0.1
Albuminuric retinitis	6	2	0.1
Fundus condition (obscured by lens changes)	82	3	1.2
No diagnosis	179	68	2.5

TABLE 2

Vision	Number of cases	Percentage of cases
0 and light perception	2,578	65.9
Light perception to 10–450	972	24.9
10–450 to 20–450	360	9.2

TABLE 3

Age	Number of cases	Percentage of cases
From 20 to 30 years	193	4.9
From 30 to 40 years	329	8.4
From 40 to 50 years	493	12.6
From 50 to 60 years	626	16.0
From 60 to 70 years	920	23.5
From 70 to 80 years	835	21.4
From 80 to 90 years	438	11.2
From 90 to 100 years	66	1.7
100 and over	10	0.3

In these tables it is to be noted that 74.1 per cent. of the blindness occurs in individuals fifty years of age and upward. We must bear in mind, however, that there is no record here of blindness up to twenty years of age. It is of interest to note that the blindness in each decade increases at a fairly definite rate from twenty to seventy years of age. The percentage of blindness under twenty is probably less than that above twenty. This in itself is one of the strong arguments in favor of the prevention of blindness. Ophthalmia neonatorum is becoming less and less frequent as a result of prophylactic measures laid down by the State Board of Health and by legal requirement. With a better understanding of the treatment of lues, focal infection, and trachoma the number of blind will decrease still further. The number of those blinded by accident will probably also be decreased by the use of safety devices and by the granting of compensation where negligence on the part of the employer is shown. The blind over fifty years of age constitute a special group which will, in my judgment, be greatly benefited by the pension grant.

Those who give us the most concern are the younger blind who, in this State, are compelled until reaching the age of sixteen to attend the school for the blind where their education and training are begun and where they are in a measure prepared to become self-supporting. The work of the school for the blind must, however, be supplemented by further training and education, vocational or otherwise. The next

step should be the establishment of shops and institutions where the blind can do something for their own support and are relieved of the necessity of disposing of their own work. This type of relief would commend itself to both the blind and the seeing.

In the table of the causes of blindness we find that trachoma leads the list as a causative factor, and the cure of this disease and the prevention of its spread should take first place in an extended relief measure. (See Table 1.)

Conservation classes for the near blind will aid much in the education not only of the near blind but of the seeing. St. Louis is about to follow the example set by Boston, Cleveland, Cincinnati, and other cities in establishing sight conservation classes in our public schools.

The second largest factor in the list is cataract. Our law does not provide for compulsory operation or treatment in cases that are favorable for treatment or surgical attention. We have had individuals blind from cataract who stated that they preferred to draw a pension rather than submit to surgical operation. It is hardly fair to insist that a person who has but one eye, but who is still able to get about, should be operated upon although he may have less than the vision of one who is entitled to a pension. On the other hand, it is not fair to the tax-payer to grant a pension to one who is unwilling to avail himself of all means offered for the relief of his blindness.

The granting of pensions has brought about some very important things. First, perhaps, a great benefit to a large dependent class who would otherwise be thrown upon the community for support; I mean, those blind upward of fifty years of age who are untrained to do work which renders them self-supporting. We have, also, in the second place, learned that the condition of the blind has as a whole forced upon us many needed changes. The first, of course, is the adoption of measures to prevent blindness, especially

trachoma and ophthalmia neonatorum. The need of conservation of sight classes in our schools is now being brought to our attention. We have compulsory education of the blind up to sixteen years of age, but supervision must be continued and vocational training given and then workshops operated in the interest of the blind which will help to make these unfortunate people more self-reliant and will take them out of the indigent class. As time goes on the problem of caring for the blind will be more and more complicated but the number of dependent blind will be diminished.

In order that the State may not be imposed upon by those who are not entitled to pensions or relief of any kind, it is necessary that we should specify what we mean by the needy or indigent and also what we mean by blindness. There is, so far as I can learn, no uniformity in the definition of either "indigent" or "blind." Whether a man is in need of assistance depends upon many factors that cannot be enumerated here. This phase of the question will have to be left to the trained investigator who should examine each case and let it stand upon its own merits. This should be done for the State and also for the blind in order that there may be no question regarding the justice of the relief to any individual. The question of blindness should be decided not by general practitioners, as is done in many of the States, but by trained oculists whose qualifications are unquestioned. We have in this State specified qualifications for the ophthalmic examiners which relieves the Commission for the Blind of making a distinction or choice that would bring criticism upon them, injustice to the tax-payer, as well as harm to the cause of the blind.

It is a simple matter to have the blind in the cities and larger towns examined, but provisions should be made for an oculist to visit the remote sections and villages where no oculist is available and where it is impossible for the individual to leave home.

I have already given a table of the results of examination of the blind of the first 4,000 on the blind pension list in Missouri, and from this it is evident that great care is necessary in the examination of these cases in order that no injustice may be done.

We might divide the blind into three classes: first, total blindness, in which there is only light perception; second, blindness to such a degree that hand movements may be seen at three or four feet; third, blindness to such a degree that the individual is able to see moving objects at a distance of ten feet.

If we wish to follow the standards set for industrial cases and call a man totally blind with a vision of 20–200, that would simplify the classification, but it would be an injustice to many. The essential fact is that a man is blind when he has insufficient sight to earn his own livelihood. This inability to make one's living varies with the individual according to the amount of previous education that he may have had, also with the amount of education or training that he is capable of. If a graded degree of blindness is to be considered, it is but fair that there should be a graded allowance according to the relief or need of the individual. We are prone to give sympathy when a man needs temporary relief and encouragement and assistance to enable him to help himself.

To summarize the relief for the blind the measures adopted might be: first, prevention; second, conserving vision; third, education and training of the blind; fourth, medical and surgical care of special cases; fifth, work for the blind; sixth, monetary assistance graded according to the individual need and means of disposing of their work. The extent to which relief is necessary depends also upon the place of residence and the ability of the friends or family to assist in the care of needy cases.

In some States the period of residence, ten to fifteen years,

has been required of all without providing that the individual who has become blinded shortly after taking up his residence in such state, is also entitled to relief. Citizenship should not in all cases be required as a prerequisite to the granting of a pension or relief. The age has been almost uniformly set at twenty-one years. It seems to me that the care of the blind and relief, when necessary, should begin at the time of the loss of sight. Those who are cared for in institutions, homes, or asylums, either public or private, penitentiary or hospital, should not be eligible for a pension. If a man's family is financially able to assume this obligation the State should not be called upon, nor should any individual be placed upon the pension roll who is unwilling to undergo education, training, treatment, or operation where such measures will probably put the individual on a self-sustaining basis or at least enable him to help himself.

Re-examination should be at the discrimination of the board of examiners. This, of course, would not be necessary in all cases, but is certainly advisable in some.

The work of caring for the blind in its various phases, including the prevention of blindness and prophylactic measures, rightly comes under the State Board of Health. This work should be done under centralized authority. When prophylactic measures of all kinds have been carried to their extreme limit and preventive measures adopted and followed out, then the number of blind will be so diminished that a pension system will not be burdensome and their number will be reduced to a minimum.

A digest of the various provisions in the States shows a lack of uniformity of opinion. To my mind there are certain fundamental principles which should appeal to all. It is not possible to separate prevention and relief, for they are too closely connected.

A few of the essentials might be summarized as follows:

1. Definition of pension; relief; indigent; blind.

2. Graded relief permissible, but not mandatory.

3. Compulsory education or training, vocational or otherwise.

4. Workshops and means of disposing of their products.

5. Connecting link between school and later life.

6. Uniform residence requirements.

7. Administration under board free from political influence and empowered and enabled to make examination into economic status and award graded relief.

8. Examinations to be made by oculists of approved standing and re-examination where advisable.

9. Uniform regulations and enforcement of prophylactic, preventive, and industrial protective measures.

10. Conservation of sight classes.

11. Provisions for medical and surgical treatment.

12. Division of expenses between the State and the county on a fifty-fifty basis.

There are certain States whose laws may be studied with profit, notably New York, Ohio, New Hampshire, Maine, Colorado, and Massachusetts.

APPENDIX

REPORT OF COMMITTEE ON UNDERGRADUATE TEACHING OF OPHTHALMOLOGY

The Committee on Undergraduate Teaching of Ophthalmology sent out a comprehensive questionnaire to a large number of the leading medical schools in America. Answers were received from 39 of these institutions. A number of the replies came too late to be thoroughly digested, but a study of the material as a whole seems to bring out certain facts that may be of interest to the members of the Society.

The average time devoted to ophthalmology by 35 colleges is fifty-eight hours. In other words, the hours that have grown out of the practical needs of the teachers of our medical schools appear to approximate almost precisely the sixty hours which the Committee of the American Medical Association has theoretically established, and recommends as the proper allotment to ophthalmology from the whole time of the undergraduate course.

The Committee finds that the average time of fifty-eight hours is almost precisely divided between didactic and clinical teaching, notwithstanding that the general consensus of opinion is in favor of an almost pure clinical training. The explanation of this discrepancy, it is thought, may be found in the small number of cases available for clinical purposes. Leaving aside the three large schools (Columbia, Harvard, and Jefferson), the average number of new patients per diem in 35 schools is only four; *i. e.*, 1,200 per annum. In the absence of clinical material, didactic and laboratory work are made to take as best they can the place of clinical instruction. The schools with the largest number of cases report the smallest number of didactic lectures; the schools with the smallest number of cases the largest amount of didactic instruction.

There seems to be a clear indication here to increase the clinical material. This perhaps might be best accomplished by the fusion of small autonomous dispensaries. A further advantage of this move would be to increase the number of teachers attached to any

one clinic, and lower the student sections assigned to individual instructors, from the present average of eight to the more ideal average of from four to six men.

A finding of moment is the lack of monetary support given to departments of ophthalmology. Of 30 schools reporting, 14 apparently receive no assistance, while the average budget for the remaining 16 is only $1,450 per annum.

The resolution of this Society last year creating the Committee on Undergraduate Teaching of Ophthalmology read as follows:

> "That the Chair appoint a committee to investigate the status of undergraduate teaching of ophthalmology in this country and report back to this Society in one year with their recommendations."

The Committee's suggestion is that, accepting for the present sixty hours as the proper allotment of time for the teaching of ophthalmology in the undergraduate course, consideration might be given with profit to the problem of how these hours should be distributed. Taking the opinions given in the answers to the questionnaire as a basis, the Committee would put forward as a starting point for discussion the following distribution:

(1)	*Didactic Instruction:* Lectures variously illustrated and covering the place of ophthalmology in medicine, the relation of the eye to other organs, and general principles.....	4–8	hours
(2)	*Clinical Instruction*	52–56	"
	Divided as follows:		
	(a) Routine methods of examination.....	4	"
	(b) Ophthalmic findings in systemic disorders and diseases of the nervous system.....	15	"
	(c) External diseases of the eye.....	33–37	"

In the time devoted to clinical instruction, periods of quite short duration might be devoted to operations and refraction.

The Committee would suggest that its work might be continued for another year, with a view to studying this matter more thoroughly, and bringing it again before the Society for discussion and an expression of opinion at its next annual meeting. The Committee would emphasize the provisional character of this report.

Two members of the Committee have interesting notes showing

the mind of students in regard to undergraduate teaching in ophthalmology, and the chairman would ask that permission be given to have these read as supplementary reports.

E. V. L. Brown,
George S. Derby,
William C. Finnoff,
Arnold Knapp,
W. Gordon M. Byers, *Chairman.*

Supplementary Report of the Committee on Undergraduate Teaching of Ophthalmology

GEORGE S. DERBY, M.D.

How much does the undergraduate in the Harvard Medical School learn from his course in ophthalmology?

When Dr. Knapp told me last winter that he was sending out a questionnaire to graduates of the College of Physicians and Surgeons (Columbia University) who had been in practice for some years, it seemed such a good idea that, with the approval of Professor Quackenboss, I asked the Dean's office to send out a similar questionnaire to the more recent graduates of the Harvard Medical School.

At the present time our school devotes thirty-eight hours to ophthalmology. Previous to this year we had a few hours more. Of this time eight hours are devoted to lectures, one of which is a pathologic demonstration. The remaining thirty hours are divided into six exercises of two and one-half hours each, coming on successive days at the Eye and Ear Infirmary. One hour each morning is devoted to ophthalmoscopy, while one and one-half hours are given to the demonstration of the commoner diseases of the eye, special attempt being made to let each student examine personally at least one case a day and see a number of others demonstrated. Each section is supposed to have six students, and instruction is now given in the third year. The last day is devoted to the examination in which the student demonstrates a case to the instructors.

The questions which we sent out were as follows:

1. Of what value has the undergraduate instruction in ophthalmology been to you in your line of work?
2. If it has been of value, which part of the instruction could with benefit be enlarged upon?
3. If it has not been of value, do you feel that it should be omitted from the *undergraduate* studies?

One hundred and five answers were received. As to the value of the course:

19	considered it	of great value.
54	"	" valuable.
6	"	" of some value.
11	"	" of slight value.
6	"	" of no value to them personally.

Shall the course be omitted?

19 emphatically opposed the suggestion of omitting the course from the curriculum.
73 answered that it could not be omitted.
3 were in favor of omitting it—less than 4 per cent.

Question 2 in regard to how the course might be improved:

25 expressed themselves as satisfied.
25 would have liked to have more time spent on the ordinary clinical work, stress being laid on the commoner diseases of the eye, the removal of foreign bodies, etc.
21, a number of whom are now specializing in internal medicine, would have more time devoted to ophthalmoscopy.
10 considered that not enough time was given to demonstrating the relationship of the eye to general disease.

The others made no suggestion.

In a general way I gather that many thought the time devoted to lectures could be more profitably spent in actual observation. My conclusions are from the answers to this questionnaire—

That the course in ophthalmology is of real use to the student and should not be omitted.

That the great part of the time should be devoted to practical work in ophthalmoscopy and in studying the commoner diseases and injuries of the eye.

Sections should not exceed six men. We have had experience with sections of six and twelve and believe that the smaller number is far superior.

Supplementary Report of the Committee on Undergraduate Teaching of Ophthalmology

ARNOLD KNAPP, M.D.

Questionnaires were sent to graduates of the College of Physicians and Surgeons (Columbia University) of fifteen and twenty-five years' standing, irrespective of the line of work in which they are now engaged. The three following questions were asked:

1. Of what value has the undergraduate instruction in ophthalmology been to you in your line of work?
2. If it has been of value, which part of the instruction could with benefit be enlarged upon?
3. If it has not been of value, do you feel that it should be omitted from the *undergraduate* studies?

One hundred and fifty-eight answers were returned. Eleven of these stated that the teaching in ophthalmology had been of no value to them in their work and they thought it might be omitted; 147 stated that it should by no means be dropped from the curriculum, and offered the following suggestions:

18 wished further instruction in the recognition of external eye diseases.
52 desired more information about ophthalmoscopy, particularly the diagnosis of nephritis, brain tumor, and arteriosclerosis.
1 thought it was a waste of time to teach ophthalmology to undergraduates.
3 desired more instruction in refraction.

Supplementary Report of the Committee on Undergraduate Teaching of Ophthalmology

W. GORDON M. BYERS, M.D.

A questionnaire to graduates was recently sent out by the Medical Faculty of McGill University. About 60 replies have been received to date. The subjects of ophthalmology and oto-laryngology were linked in the questionnaire, and for that reason it is impossible to give precise figures for ophthalmology. But summing up the answers it can be conservatively stated that the graduates generally were in favor of maintaining undergraduate teaching in ophthalmology. This statement is made in support of the findings of Dr. Knapp and Dr. Derby.

REPORT OF COMMITTEE ON GRADUATE TEACHING OF OPHTHALMOLOGY

During the past year a survey of institutions engaged in the graduate teaching of medicine in this country has been made by a Committee appointed by the Council on Medical Education and Hospitals of the American Medical Association. The Chairman, Dr. Louis B. Wilson, of Rochester, Minn., and the Secretary of the Council, Dr. N. P. Colwell, visited and inspected 26 of these institutions and prepared a report in two parts. One part has been published.[1] The other part is for the private guidance of the Council in rating the institutions of this kind, which will doubtless be attempted in the near future.

This report did not deal especially with the graduate teaching of ophthalmology, but a survey which had that especial purpose was made for the American Board for Ophthalmic Examinations and published two years ago.[2] A repetition of such survey by your Committee this year promised little that would be new and important. At the present time an attempt to formulate our conception of what ought to be the course of graduate study in preparation for ophthalmic practice, with suggestions for making it the course commonly adopted by teachers and students, seems to be more generally useful.

The published report to the Council on Medical Education says: "There still remain institutions in which the conditions are almost inconceivably bad"; and the private report, which named the institutions and specified the conditions referred to, showed that some of these schools of the lowest grade still attract large classes—sufficient to furnish their financial support. It remains a fact that half the American students now seeking to profit by the large ophthalmic clinics of Europe are so ignorant of the methods of examining cases of ocular disease that they can gain very little by such opportunities; and a much larger proportion of them are so poorly grounded in the fundamental branches bearing on eye conditions that they cannot appreciate the real meaning of what they see.

What benefit can it be to the student to examine the tissues of the eye when he does not know its anatomic variations and anomalies most likely to be mistaken for pathologic conditions? What does it profit to search the eyeground for the cause of poor sight

[1] Jour. Amer. Med. Assn., v. 80, March 17, p. 790.

[2] Amer. Jour. Ophth., v. 4, Feb., 1921, p. 135.

when the ophthalmoscopist does not understand the significance of what he does see there? Preparation for special practice has been inadequate, not only because the time given to it was so short, but also because that time was so poorly used; because no course of study offered was arranged to give the fundamental training that was essential to proper clinical work. This Society can do no greater service to education in ophthalmology than by emphasis upon the proper content and order of such education, published in such a way as to command the attention of ophthalmologists, medical teachers, and medical practitioners and students who are considering ophthalmic practice as a desirable special work to take up.

The average undergraduate student has been expected to learn a great deal about the fundamental branches, anatomy, physiology, and pathology, that did not seem to have any practical connection with his subsequent studies or practice. And, having spent his time acquiring so much that seemed useless, he has assumed that he had been taught all that could be useful. The young doctor of medicine, advised not to think of a specialty until long after he has put the study of anatomy behind him,—he hopes forever,—assumes that he was taught, along with the relations of the structures in Scarpa's triangle, all the anatomy of the eye that he will ever need to know.

He believes that, having been puzzled by the layers of the retina, when he had no interest in the purposes they serve, he learned as much of ocular histology as he can ever find useful. He was not conscious of any significance that might attach to the behavior of visual purple, and the suggestions that might come from it as to the influence of exhaustion or after-images on visual acuity. The facts of pathology were presented in relation to the appendix, the spinal column, the liver, or the kidney; but were not understood or appreciated with regard to intra-ocular pressure, transparency of the media, or sclerosis of the retinal vessels. In a word, the man or woman who has been dubbed a doctor in medicine, turns to ophthalmic practice as a special field of work with the impression that he has had all the training he needs as to the fundamentals of medicine, and only lacks an acquaintance with clinical methods and appearances and a perfected operative technic to fit him for the duties of a practising ophthalmologist.

The first thing such an aspirant must be taught is that there is a good deal of the anatomy, histology, and embryology of the eye that he never learned in the medical college and must know before

he can make a good clinical examination of an eye; that physiologic optics is a large subject, fundamental to ophthalmic practice, and directly entering into the most extensive branch of the work of the oculist; and that pathology appears in a new aspect in relation to the eye, and gives significance and importance to what is seen with the ophthalmoscope or ocular microscope.

It should be made clear to every one interested that the first step in preparation for special ophthalmic practice is to study the special anatomy, histology, embryology, and physiology of the eye; elementary optics with so much trigonometry as is needed for its understanding; pathology as manifested in the ocular tissues; and the bacteriology of ocular infections, both superficial and deep. The American Ophthalmological Society, which has always selected its members with relation to their scientific training, powers of original research, and ability to discuss questions of scientific interest, is peculiarly fitted to point out the kind of education the ophthalmologist should aim at, and especially to indicate how the differentiation of his training from that of the general medical profession should begin.

After getting an acquaintance with the above fundamental branches, the special methods of examination should be studied and practised. Examination by focal illumination, with the convex lens, now expanded to the corneal microscope, ophthalmoscopy, transillumination, the shadow test, the use of test lenses, the different tests of visual acuity, methods of mapping the field of vision, tonometry, the use of fluorescein and other intravital stains, the various tests for ocular movements and balance, and the tests of color sense, light sense, radiography of the eyeball and adjoining parts. These should be taught by demonstration and actual application to the patient. Beginning with an understanding of instruments and methods of their use, this may go on to clear understanding of appearances and symptoms elicited, to be connected, on the one hand, with the fundamentals, anatomy, embryology, and pathology, and gradually developed and combined into the systematic examination of patients and the combination of the facts ascertained in diagnosis.

As the last stage of this systematic course, only valuable as it has been preceded by what has been already indicated, we come to the clinical work with patients, that has too often been the only thing sought by the graduate student, and which could only be really profitable when preceded by the studies we have indicated. The

final result of the graduate education in ophthalmology depends not alone on the number and variety of clinical cases seen, but very much on the systematic thoroughness and skill with which every case seen has been studied. It is certain that the educational result reached will be better from the thorough study of one hundred cases than from the use of the same time and effort in the more hasty and superficial investigation of one thousand. The educational opportunity is greater, not in the clinic or private office that "runs through" the largest number of cases, but in that in which the study of each case is most systematic, conscientious, and minute.

The perfection of a graduate education is attained not by telling or showing the student something, but by training him to see and do it himself. Beyond the knowledge of fundamentals, the skill in methods of examination and the storing up of clinical experience is the habit of combining all these resources and making them bear directly on the problems of the particular case. The constant harking back to anatomy and pathology, the continuous drawing on physiology for the philosophy of the succession of morbid phenomena the constant striving to check up the results of one examination by other methods, the following the case through to the end, and examining and thinking of it as a whole, are all important objectives of graduate training.

Such ideal training is possible only by the co-operation of several groups of workers who are, or might be, interested in graduate teaching and where each worker commands a part of the wide resources that have to be drawn upon to perfect the ophthalmologist. The work on fundamentals can be given only by those who command laboratories of anatomy, histology, physiology, optics, and pathology. Many of the good clinical schools are destitute of such laboratories. Those that have what they call clinical or pathologic "laboratories" often do no teaching in them. An applicant before the American Board for Ophthalmic Examinations examined in the pathologic laboratory of one of the most widely known eye hospitals in this country admitted that during his year of internship in that institution he had scarcely seen the inside of that room.

It should be urged on every university medical school that there should be given each year a laboratory course of at least a month on each branch fundamental to ophthalmology—anatomy, including histology and embryology, physiologic optics, and ocular path-

ology. Twenty such institutions, each turning out a laboratory class each year, on each of these fundamentals, would not supply the annual need for well-trained oculists in this country. These courses might best be given by oculists, who themselves had a good acquaintance with these fundamentals, but teachers of anatomy, physics, and general pathology, who know nothing of ocular disease, can meet the need for such teaching far better than it has been met in the past. Such courses have never been offered for any adequate number of graduate students, either in Europe or America. They are more nearly approached in Madras and Peking. It is time for America to take the lead in such teaching.

Laboratory teaching is given under personal supervision and to relatively small classes. Training in methods of examination of the eye must also be given with laboratory facilities, and to even smaller classes than can be handled in laboratories of anatomy, pathology, and physics. It must be given by instructors skilled in the use of such methods of examination. Courses of such instruction should be given in every ophthalmic hospital and clinic in the country throughout the year. Without such systematic training a larger part of the people must depend for ophthalmic service on half-trained specialists, general practitioners who are willing to guess at eye conditions, and optometrists spawned by scores for each single well-trained oculist.

An oculist recently advertised for a skilled assistant. Among the many applications received not one in ten showed any evidence of systematic training in the work of making routine ocular examinations. They all seemed to assume that, being graduates in medicine who were "interested" in the eye and had spent a few weeks in clinics looking over the shoulders of their classmates and discussing operative technic, they were qualified for such a position. A man who had served full time as intern in one of the largest ophthalmic hospitals in America was found unable to see gross fundus changes with the ophthalmoscope. He had never been taught to use it with any skill. It needs to be repeated, here as elsewhere, that the path to the greatest honor and satisfaction in ophthalmology, to most certain and permanent reward for our labor, is the teaching of younger men how to examine an eye and how to understand what they see in it.

But the final stage of graduate instruction cannot be given even to laboratory classes, or in teaching clinics, but only to assistants who continue to have daily professional contact with the teacher, either

in public clinic or private office, through years of ophthalmic practice. When senior and junior workers in ophthalmology come, through such contact, to know and respect each other, when they understand each other's point of view, and compare, day after day, their observations and inferences; when the recollections and lessons of former cases are summoned up, to throw their light on the common problems of the case under investigation, graduate study reaches its climax and begins to yield intelligence and wisdom, which patients and communities can best afford to seek and reward. For every practitioner of ophthalmology who is so circumstanced that he can possibly associate with himself in practice younger men, his most constant duty, his broadest opportunity, his higest privilege is to seek such association.

The members of the American Ophthalmological Society, as teachers, trustees, and alumni of medical schools, as heads of clinics, as members of hospital staffs, in the discussions of medical societies, as advisers of practitioners or students looking to ophthalmology as their field of future work, and, most of all, in planning and conducting their own daily practice, can do much to improve and render effective the ideals of graduate instruction in ophthalmology.

Something may be done in arranging definite schedules of instruction, and assigning order and time to particular subjects, but this is a matter for more personal discussion than has been possible for members of your Committee in the last year. It might be aided by the general discussion appropriate to the presentation of this report.

It may be worth while, however, here to consider the question as to whether our energies at first should be directed chiefly toward improving the education of all the incoming ophthalmologists to the limited extent now possible; or toward organizing a few postgraduate schools which would train a few men in a relatively thorough manner. The graduates of such schools would form a body of men from whom teachers and investigators could be drawn. Even one such postgraduate school would be worth while, and we think the members of the Society should be urged to seek an endowment for this purpose. It is certainly surprising that no one has ever offered to donate a large sum for the advancement of ophthalmology. This must be due to the fact that our needs have not been sufficiently advertised.

The chief difficulty in organizing a graduate school of ophthal-

mology is in obtaining properly qualified teachers who are willing to devote sufficient time to the school. Most ophthalmologists feel that, after they have given a large part of their time to clinical work in the hospital, they must devote the rest of their time to making a living in private practice. The only way this difficulty can be overcome is to provide adequate salaries for the teachers.

Another question is, to what extent should facilities be provided for teaching men of marked ability who are already practising ophthalmology? While there may be many such men, there are probably only a few who can afford to give up practice for a sufficient time to obtain any real benefit from the postgraduate courses. This question may solve itself if well-organized postgraduate schools are once established.

F. H. Verhoeff,
T. B. Holloway,
Edward Jackson, *Chairman.*

INDEX

American Board for Ophthalmic Examinations, 27, 30
American College of Surgeons, nominees for, 30
Angioma of Orbit, 144
Appendix, 315
Auditing Committee, 25

Bedell, Arthur J., 86, 134, 182
Berens, Conrad, Jr., 271
Black, Nelson M., 125, 171
Blake, Eugene M., 95
Blepharoptosis, 71
Blind, Legislation for Relief of, 301
Blind Spot, Examination of, 271
Brown, E. V. L., 99, 201
Buphthalmos, 43
Burke, John W., 182
Byers, W. Gordon M., 126, 144
By-Laws, Amendments to, 33, 37

Calhoun, F. Phinizy, 49
Charles, J. W., 86, 189, 202, 229
Choroiditis, Metastatic, 230
Clapp, C. A., 43, 52, 200
Committee: Auditing, 25
Graduate Teaching, 32
Investigation National Safety Code, 32
Investigation of Retinal Conditions, 32
Pathology, 31
Prize Essays, 32
Program, 32
Publication, 32
Theses, 32
Undergraduate Teaching, 32
Congress, International Ophthalmological, 28, 38
Constitution, Amendments to, 33, 37
Council, Members of, 5, 32
National, 30
Report of, 29

Derby, George S., 70, 78, 148, 151, 220
Diplopia, Monocular, 223

Ellett, E. C., 49, 150, 236
Endophthalmitis, Phacoanaphylactic, 202
Endowment Fund, 24, 30, 31
Epibulbar Tumor, 100
Ewing, A. E., 78, 86
Eyeball, Posterior Transillumination of, 148
Eyelid, Sarcoma of, 119
Executive Session, 26, 37
Exhibition of Instruments and Apparatus, 124

Feingold, Marcus, 50, 96, 181
Finnoff, W. C., 87, 99, 124, 132, 133
Fisher, Carl, 75, 236
Focal Infections, 230
Francis, Lee Masten, 140, 158

Glaucoma, Acute, 52
Infantile, 43
Iridectomy, 62
Glioma, Bilateral, 164
of Retina, 124
Graduate Teaching, Report of Committee, 320
Green, John, Jr., 51, 157, 201
Greenwood, Allen, 60, 85, 97, 117, 201, 230, 238

Harbridge, D. F., 239
Hardy, William F., 183
Hemorrhage Causing Optic Atrophy, 239
Hill, Emory, 194, 202, 238
Holloway, T. B., 50, 97, 116
Howe, Lucien, 95, 97, 124
Hyaloid Artery, 133
Hydrophthalmos, 43

Insulin, in Lipæmia Retinalis, 183
International Congress of Ophthalmology, 28, 38
Iridectomy in Glaucoma, 62
Iris, Glioma of, 164

Jack, E. E., 143
Jackson, Edward, 60, 97, 124, 159, 170
Jean, George W., 151, 188

Key, Ben Witt, 77
Knapp, Arnold, 61, 116, 158, 164, 220

Lacrimal Duct Conservation, 78
Gland, Adenosarcoma, 140
Lambert, W. E., 150
Lancaster, W. B., 76, 201, 220, 229
Lane, Francis, 169, 188
Legislation for Blind, 301
Lemoine, Albert N., 202, 222
Libby, George F., 48
Lichtenberg, J. S., 150
Lipæmia Retinalis, 183
Luedde, W. H., 107
Lyster, T. C., 182

MacDonald, Alexander E., 202
Macleish, A. L., 199
Members, List of, 7
Minutes of Proceedings, 23
Monocular Diplopia, 223
Muscles, Insertions of, 124

National Council, 30, 33
Necrology, 13

Officers, List of, 5
Ophthalmic Examinations, Report of Board, 27
Optic Atrophy from Distant Hemorrhage, 239
Orbit, Angioma of, 144
Osteoma of, 134
Osteoma of Orbit, 134

Pathology, Committee on, 36
Patterson, James A., 95
Phacoanaphylactic Endophthalmitis, 202
Presidents of the Society, 6
Prize Essays, 27, 32
Proceedings, Minutes of, 23
Program Committee, 32
Ptosis Operation, 71
Publication Committee, 32
Pusey, Brown, 125

Radium for Epibulbar Tumor, 100
Reese, Robert G., 71
Retina, Glioma of, 124, 164
Malignant Disease of, 159
Retinal Conditions, Committee to Investigate, 32
Retinal Detachment, in Pregnancy, 194
Detachment, pain in, 189

Safety Code, Investigation of, 32
Sarcoma of Lid, 119
Scarlett, Hunter W., 247
Secretary-Treasurer, Report of, 26
Shahan, W. E., 124, 151, 158
Shannon, C. E. G., 119
Siderosis Bulbi, 125, 171
Stark, H. H., 290
Stegman, L. V., 51
Sweet, William M., 181

Teaching Graduate, 29, 320
Undergraduate, 29, 315
Theobald, Samuel, 43
Thermophore, 124
Thermotherapy, Selective, 151
Theses, Committee on, 32
Török, E., 62
Transillumination of Eyeball, 148
Traumatic Neurology, 247
Tubercle Bacilli, Injections of, 87
Tuberculosis, General, Effect on Eye, 290
of Eye, 124, 126
Tumor, Epibulbar, 100
Limbus, 107
Sarcoma of Lid, 119

Undergraduate Teaching, Report of Committee, 315

Veasey, C. A., 60, 139

Wilder, W. H., 70, 98, 100, 118, 158, 220, 237
Wilmer, W. H., 221
Woodruff, F. E., 301
Woods, Hiram, 52, 61, 85, 95

Zentmayer, William, 78, 94, 117, 232, 229

RE
1
A55
v.21

Biological
& Medical
Serials

American Ophthalmological
Society
Transactions

PLEASE DO NOT REMOVE
CARDS OR SLIPS FROM THIS POCKET

UNIVERSITY OF TORONTO LIBRARY

STORAGE